

ORIGINAL ARTICLE

Possible Subclinical Leaflet Thrombosis in Bioprosthetic Aortic Valves

R.R. Makkar, G. Fontana, H. Jilaihawi, T. Chakravarty, K.F. Kofoed, O. de Backer, F.M. Asch, C.E. Ruiz, N.T. Olsen, A. Trento, J. Friedman, D. Berman, W. Cheng, M. Kashif, V. Jelnin, C.A. Kliger, H. Guo, A.D. Pichard, N.J. Weissman, S. Kapadia, E. Manasse, D.L. Bhatt, M.B. Leon, and L. Søndergaard

ABSTRACT

BACKGROUND

A finding of reduced aortic-valve leaflet motion was noted on computed tomography (CT) in a patient who had a stroke after transcatheter aortic-valve replacement (TAVR) during an ongoing clinical trial. This finding raised a concern about possible subclinical leaflet thrombosis and prompted further investigation.

METHODS

We analyzed data obtained from 55 patients in a clinical trial of TAVR and from two single-center registries that included 132 patients who were undergoing either TAVR or surgical aortic-valve bioprosthesis implantation. We obtained four-dimensional, volume-rendered CT scans along with data on anticoagulation and clinical outcomes (including strokes and transient ischemic attacks [TIAs]).

RESULTS

Reduced leaflet motion was noted on CT in 22 of 55 patients (40%) in the clinical trial and in 17 of 132 patients (13%) in the two registries. Reduced leaflet motion was detected among patients with multiple bioprosthesis types, including transcatheter and surgical bioprostheses. Therapeutic anticoagulation with warfarin, as compared with dual antiplatelet therapy, was associated with a decreased incidence of reduced leaflet motion (0% and 55%, respectively, $P=0.01$ in the clinical trial; and 0% and 29%, respectively, $P=0.04$ in the pooled registries). In patients who were reevaluated with follow-up CT, restoration of leaflet motion was noted in all 11 patients who were receiving anticoagulation and in 1 of 10 patients who were not receiving anticoagulation ($P<0.001$). There was no significant difference in the incidence of stroke or TIA between patients with reduced leaflet motion and those with normal leaflet motion in the clinical trial (2 of 22 patients and 0 of 33 patients, respectively; $P=0.16$), although in the pooled registries, a significant difference was detected (3 of 17 patients and 1 of 115 patients, respectively; $P=0.007$).

CONCLUSIONS

Reduced aortic-valve leaflet motion was shown in patients with bioprosthetic aortic valves. The condition resolved with therapeutic anticoagulation. The effect of this finding on clinical outcomes including stroke needs further investigation. (Funded by St. Jude Medical and Cedars–Sinai Heart Institute; Portico-IDE Clinical-Trials.gov number, NCT02000115; SAVORY registry, NCT02426307; and RESOLVE registry, NCT02318342.)

The authors' full names, academic degrees, and affiliations are listed in the Appendix. Address reprint requests to Dr. Makkar at the Department of Interventional Cardiology, Cedars–Sinai Heart Institute, 8700 Beverly Blvd., Los Angeles, CA 90048, or at makkarr@cshs.org.

This article was published on October 5, 2015, at NEJM.org.

N Engl J Med 2015;373:2015-24.

DOI: 10.1056/NEJMoa1509233

Copyright © 2015 Massachusetts Medical Society.

 A Quick Take
is available at
NEJM.org

TRANSCATHETER AORTIC-VALVE REPLACEMENT (TAVR) is a recent innovation in the management of aortic stenosis. The efficacy and safety of this therapeutic intervention have been studied in several randomized clinical trials.¹⁻⁶ The Portico Re-sheathable Transcatheter Aortic Valve System U.S. Investigational Device Exemption (PORTICO IDE) study is an ongoing, prospective clinical trial to evaluate TAVR with either a Portico valve (St. Jude Medical) or a commercially available valve.

As specified in the PORTICO IDE protocol, computed tomography (CT) was performed in a subgroup of patients to assess the stent frame of the implanted valve. A finding of reduced leaflet motion on CT in a patient who had had a stroke after TAVR and similar findings in an asymptomatic patient at one clinical site led to closer scrutiny of this observation. Additional CT review by the core laboratory revealed that this finding was not isolated, which prompted a more extensive investigation that involved analysis of all available CT and echocardiographic data.

These events also led to the establishment of two physician-initiated registries to evaluate bioprosthetic leaflet function after TAVR or surgical aortic-valve replacement: the Assessment of Transcatheter and Surgical Aortic Bioprosthetic Valve Thrombosis and Its Treatment with Anticoagulation (RESOLVE) registry and the Subclinical Aortic Valve Bioprosthesis Thrombosis Assessed with Four-Dimensional Computed Tomography (SAVORY) registry. We report the findings of these investigations from the randomized, controlled PORTICO IDE study as well as from the two registries. The major objective of our analyses was to examine the prevalence of reduced leaflet motion in bioprosthetic aortic valves, as assessed on four-dimensional, volume-rendered CT; the association between reduced leaflet motion and strokes and transient ischemic attacks (TIAs); and the influence of anticoagulation on reduced leaflet motion.

METHODS

STUDY POPULATIONS, FUNDING, AND OVERSIGHT

This study was conducted in patients who were enrolled in the PORTICO IDE randomized trial and in the RESOLVE and SAVORY registries. The PORTICO IDE trial, which is sponsored by St. Jude Medical, has a target enrollment of 1206

patients. The trial protocol is available with the full text of this article at NEJM.org.

The RESOLVE and SAVORY registries are also ongoing. RESOLVE is a single-center registry study that is being conducted at Cedars-Sinai Medical Center in Los Angeles and that includes patients with previously implanted valves (retrospective enrollment) with a target enrollment of 200 patients; it is funded by the Cedars-Sinai Heart Institute. SAVORY is a single-center registry study that is being conducted at Rigshospitalet in Copenhagen and that includes patients with newly implanted valves (prospective enrollment) with a target enrollment of 75 patients; it is funded by St. Jude Medical.

For the PORTICO IDE trial, the sponsor contributed to the study design, supervised data collection and analysis, and reviewed the manuscript to verify the accuracy of data with respect to the PORTICO IDE patients. For the two registries, study design and data collection were conducted by the respective institutions. For the trial and the two registries, approval by the institutional review board at each participating site was obtained before study initiation, and all patients provided written informed consent. The coprincipal investigators had unrestricted access to the data from all three data sets for the purpose of this analysis. They also made the decision to submit the manuscript for publication, prepared all drafts of the manuscript, and attest to the completeness and accuracy of the reported data and for the fidelity of the study to the protocol.

CT IMAGING AND EVALUATION

In the PORTICO IDE trial, all the patients underwent CT 30 days after TAVR on the basis of the routine imaging protocol at each study site. In the RESOLVE and SAVORY registries, all the patients underwent CT at varying intervals after either TAVR or surgical aortic-valve replacement (median interval, 87 days; range, 7 to 1851). All CT scans were obtained with a dedicated four-dimensional, volume-rendered CT-acquisition protocol, as mandated at each site. Details with respect to the CT imaging protocol and image processing are provided in the Supplementary Appendix, available at NEJM.org.

Blinded analysis of CT data from the PORTICO IDE trial and the registries was performed by a dedicated CT core laboratory at Cedars-Sinai

Heart Institute, with quantitative assessment of leaflet motion with a volume-rendered en face image of the aortic-valve prosthesis at maximal leaflet opening. Leaflet motion was defined as normal, mildly reduced (<50% reduction), moderately reduced (50 to 70% reduction), severely reduced (>70% reduction), or immobile (lack of motion in at least one valve leaflet). Validation of leaflet-motion assessments is described in the Supplementary Appendix. For the purposes of analysis, leaflet motion was considered to be reduced if it was moderately reduced, severely reduced, or immobile.

TRANSTHORACIC AND TRANSESOPHAGEAL ECHOCARDIOGRAPHY

For all patients, transthoracic echocardiography was performed at baseline and at the time that CT was performed. Valvular hemodynamics, stroke volume, and ejection fraction were reported according to the guidelines of the American Society of Echocardiography.⁷⁻⁹ For the PORTICO IDE and SAVORY cohorts, transesophageal echocardiography was performed in a subgroup of patients to compare and validate the CT findings of reduced leaflet mobility and to further describe the mechanism and cause of these leaflet-motion abnormalities. All echocardiographic results in the PORTICO IDE trial were analyzed by a single investigator in the echocardiography core laboratory at MedStar Health Research Institute in Washington, D.C.

CLINICAL OUTCOMES

All the patients, in both the PORTICO IDE trial and the registries, who had a neurologic event were evaluated by a neurologist and underwent neuroimaging. In the PORTICO IDE trial, an independent clinical-events committee adjudicated all end-point events; cases of stroke or death were included in this analysis. We investigated the associations between reduced leaflet motion (as identified on CT) and various baseline, procedural, and follow-up data, including neurologic events. At the time that the index CT was performed, we collected data on antithrombotic strategies to assess their effect on the prevalence of reduced leaflet motion. In patients with reduced leaflet motion who underwent a repeat CT scan, we collected data on the use of antithrombotic medications to study their effect on the resolution of reduced leaflet motion.

STATISTICAL ANALYSIS

We calculated means \pm SD to summarize continuous variables and frequencies and percentages to summarize categorical variables. For the comparison between patients with normal leaflet motion and those with reduced leaflet motion, we used the two-sample t-test for normally distributed continuous data or the Wilcoxon rank-sum test for nonnormally distributed continuous data. We used the chi-square test or Fisher's exact test to compare categorical variables. A two-sided P value of less than 0.05 was considered to indicate statistical significance. Statistical analyses were performed with the use of SAS software, version 9.3.

RESULTS

REDUCED AORTIC-VALVE LEAFLET MOTION

PORTICO IDE Cohort

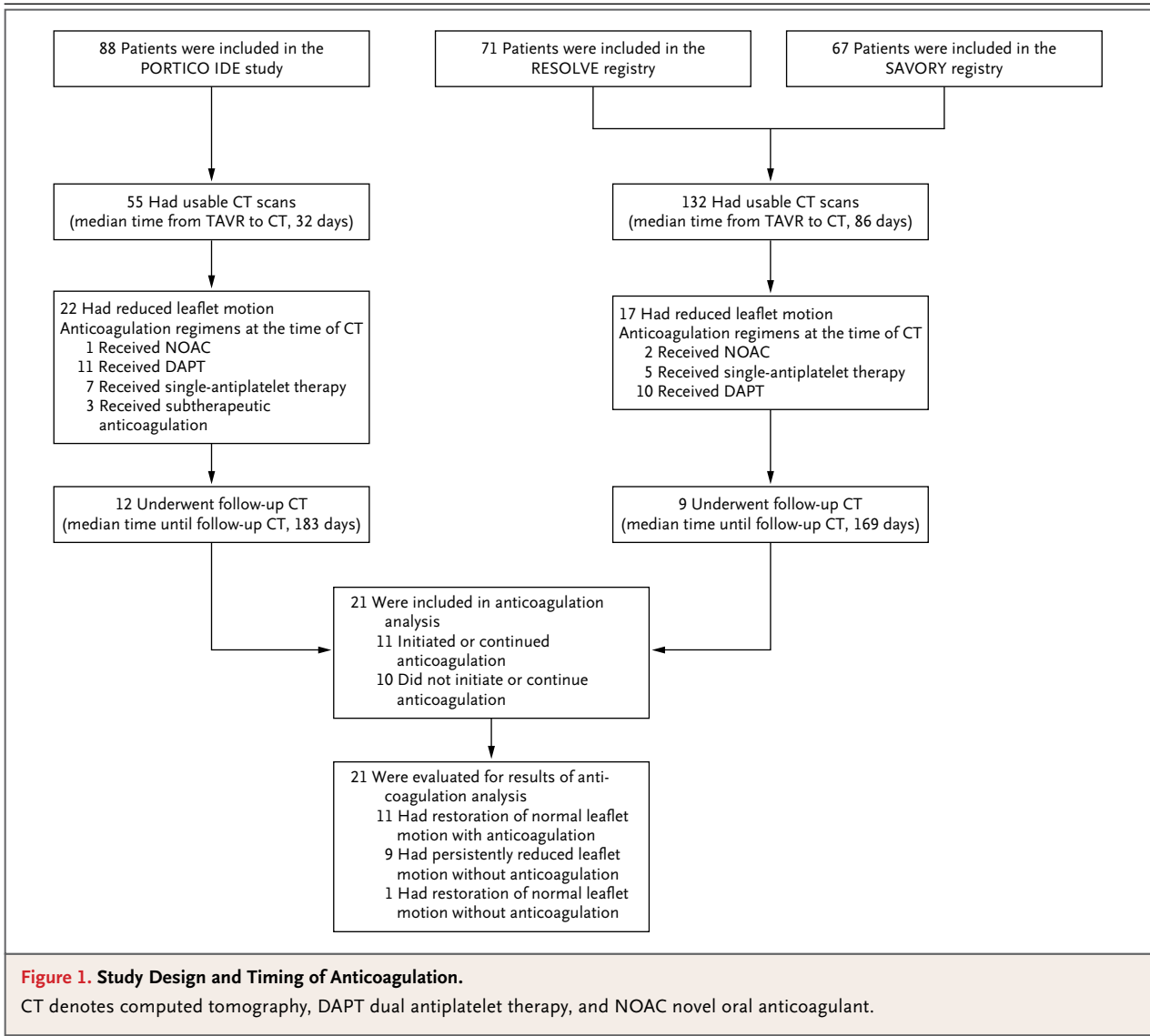
Of the 88 patients in the TAVR group in the PORTICO IDE trial, 65 underwent cardiac CT, which was conducted with contrast material in 59 patients and without contrast material in 6 patients. Of these patients, 55 who had usable contrast CT scans were included in the analysis (median interval between TAVR and CT, 32 days; interquartile range 28 to 37) (Fig. 1). Baseline clinical, CT, and echocardiographic characteristics are summarized in Table 1, and in Table S1 in the Supplementary Appendix.

Reduced aortic-valve leaflet motion was present in 22 of 55 patients (40%), including 16 of 37 (43%) with Portico valves, 6 of 14 (43%) with Sapien XT valves (Edwards Lifesciences), and 0 of 4 patients with CoreValve valves (Medtronic). One leaflet was affected in 15 patients, two leaflets in 6 patients, and three leaflets (one immobile leaflet and two leaflets with severely reduced motion) in 1 patient. All the patients with reduced leaflet motion on four-dimensional, volume-rendered CT had hypoattenuating opacities noted in the corresponding leaflets on two-dimensional CT, primarily at the base of the valve leaflets (Fig. 2, and Fig. S1 in the Supplementary Appendix; videos are available at NEJM.org).

Transesophageal echocardiography was performed at a median of 9 days after CT in 10 of 22 patients with reduced leaflet motion (including patients with Portico and Sapien XT valves). There was 100% concordance in the assessment of leaflet motion between the two imaging



Videos showing reduced leaflet motion in aortic-valve bioprostheses are available at NEJM.org



methods. The findings on transesophageal echocardiography were consistent with a hyperechoic, homogeneous mass located on the aortic aspect of the prosthetic leaflets that prevented normal leaflet excursion (Fig. S2 in the Supplementary Appendix and videos).

There was no significant difference between patients with reduced leaflet motion and those with normal leaflet motion with respect to the mean aortic-valve gradient. This observation was consistent at the time of hospital discharge in 50 patients (aortic-valve gradient, 9.1 ± 4.5 mm Hg and 9.5 ± 4.2 mm Hg, respectively; $P=0.50$), at 30 days in 50 patients (aortic-valve gradient,

10.5 ± 4.3 mm Hg and 9.0 ± 4.9 mm Hg, respectively; $P=0.10$), and at 6 months in 28 patients (aortic-valve gradient, 9.6 ± 6.0 mm Hg and 9.5 ± 4.2 mm Hg, respectively; $P=0.85$) (Fig. S3 in the Supplementary Appendix).

The prevalence of reduced leaflet motion was lower among patients who received therapeutic anticoagulation with warfarin at the time of the index CT after TAVR (international normalized ratio [INR], >2.0 within 7 days before or after CT scan), as compared with those who received either subtherapeutic or no anticoagulation (0 of 8 patients receiving therapeutic warfarin vs. 21 of 41 patients [51%] receiving subtherapeutic or no

Table 1. Characteristics of the Patients at Baseline in the PORTICO IDE Study.*

Characteristic	Normal Leaflet Motion (N=33)	Reduced Leaflet Motion (N=22)	P Value†‡
Age — yr	82.1±9.4	86.3±6.2	0.10
Male sex — no. (%)	18 (55)	8 (36)	0.19
Body-mass index‡	28.0±6.3	27.0±6.1	0.47
Medical condition — no. (%)			
Chronic kidney disease	9 (27)	9 (41)	0.29
Hypercoagulable disorder	0	1 (5)	0.40
Hypertension	28 (85)	21 (95)	0.38
Previous stroke	4 (12)	5 (23)	0.46
Previous transient ischemic attack	4 (12)	2 (9)	>0.99
Hyperlipidemia	24 (73)	20 (91)	0.17
Active cancer	10 (30)	7 (32)	0.91
Autoimmune disease	1 (3)	1 (5)	>0.99
Diabetes	17 (52)	12 (55)	0.83
Chronic lung disease	14 (42)	6 (27)	0.25
Peripheral vascular disease	14 (42)	9 (41)	0.91
Coronary artery disease	13 (39)	7 (32)	0.57
Myocardial infarction	4 (12)	2 (9)	>0.99
Atrial fibrillation	15 (45)	10 (45)	>0.99
New York Heart Association class — no. (%)			0.53
I	0	0	
II	5 (15)	4 (18)	
III	20 (61)	10 (45)	
IV	8 (24)	8 (36)	
History of smoking — no. (%)	15 (45)	9 (41)	0.74
Surgical procedure — no. (%)			
CABG	15 (45)	5 (23)	0.15
PCI	11 (33)	5 (23)	0.55
Balloon aortic valvuloplasty	3 (9)	1 (5)	0.64
Surgical aortic-valve replacement	1 (3)	2 (9)	0.56
Permanent pacemaker	9 (27)	5 (23)	0.76

* Plus-minus values are means ±SD. CABG denotes coronary-artery bypass grafting, and PCI percutaneous coronary intervention.

† P values were calculated with the use of the two-sample t-test or the Wilcoxon rank-sum test for continuous variables and the chi-square test or Fisher's exact test for categorical variables.

‡ The body-mass index is the weight in kilograms divided by the square of the height in meters.

anticoagulation, $P=0.007$). Reduced leaflet motion was also less prevalent among patients receiving therapeutic anticoagulation than among those receiving dual antiplatelet therapy (0 of 8 patients and 11 of 20 patients [55%], respectively; $P=0.01$) (Table S2 in the Supplementary Appendix).

Pooled RESOLVE and SAVORY Cohorts

The pooled registry data set included 132 patients — 70 from the RESOLVE registry and 62 from the SAVORY registry — who had CT data that could be interpreted (out of 71 and 67 CT scans, respectively) (Fig. 1). Scanning was performed a mean of 30 ± 10 days after the procedure

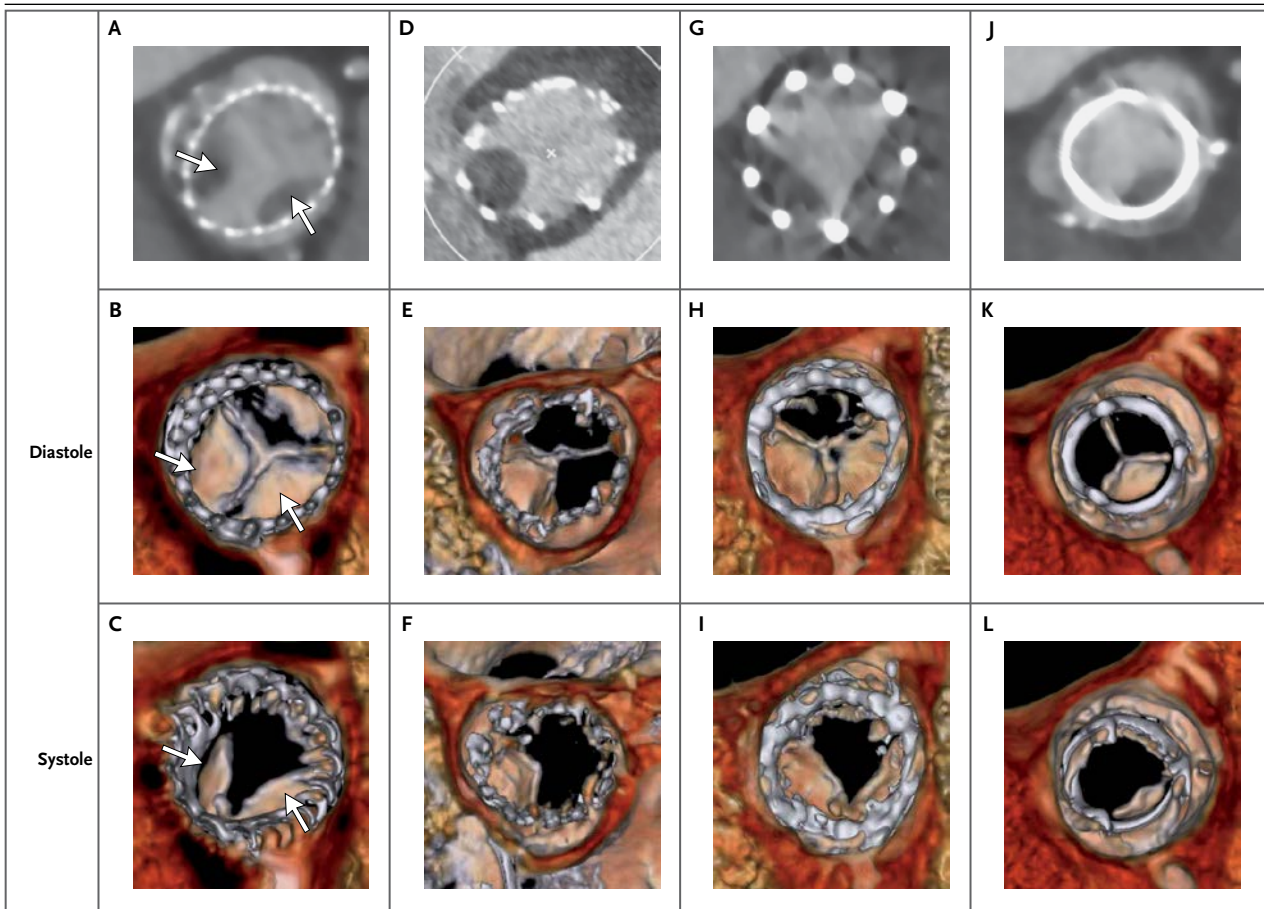


Figure 2. Evidence of Reduced Leaflet Motion in Multiple Prosthesis Types.

Shown are hypoattenuating opacities on two-dimensional computed tomography (CT) (maximum intensity projection of gray-scale image) and volume-rendered CT (color images) for multiple prosthesis types, including the CoreValve (Panels A through C, arrows), Portico (Panels D through F), Sapien XT (Panels G through I), and Carpentier–Edwards Perimount surgical valve (Panels J through L) during diastole and systole. The hypoattenuating lesions always involve the base of the leaflet and extend to the center of the frame. Normal leaflets are visible only on volume-rendered CT in diastole, at their line of coaptation in axial images. Leaflets with reduced motion are visible as wedge-shaped or semilunar opacities in both systole and diastole.

in 42 patients (32%) and within 3 months in 73 patients (55%). These patients underwent implantation of 105 transcatheter valves and 27 surgical valves. Baseline clinical, CT, and echocardiographic characteristics are summarized in Table 2, and in Table S3 in the Supplementary Appendix.

Reduced leaflet motion was observed in 17 of 132 patients (13%), including 15 of 105 with transcatheter valves (14%) and 2 of 27 with surgical valves (7%). Details with respect to valve type and frequency of reduced leaflet motion for each type are provided in Table S4 in the Supplementary Appendix. There was no significant difference in the interval between the valve implantation and the performance of CT among patients

with reduced leaflet motion and those with normal leaflet motion (228 ± 459 days and 189 ± 293 days, respectively; $P=0.67$). The antithrombotic regimens at the time of CT are provided in Table S2 in the Supplementary Appendix. Therapeutic anticoagulation with warfarin was associated with significantly lower rates of reduced leaflet motion than was dual antiplatelet therapy (0 of 13 patients and 10 of 35 patients [29%], respectively; $P=0.04$).

NATURAL HISTORY OF REDUCED LEAFLET MOTION

Among patients with reduced leaflet motion, follow-up CT was performed in 12 of 22 patients in the PORTICO IDE study (median interval between index and follow-up CT, 183 days) and in

Table 2. Characteristics of the Patients at Baseline in the Pooled Registries.*

Characteristic	Normal Leaflet Motion (N=115)	Reduced Leaflet Motion (N=17)	P Value
Age — yr	79.9±9.0	80.8±7.9	0.68
Male sex — no. (%)	59 (51)	9 (53)	0.90
Body-mass index	26.4±4.9	24.3±3.8	0.10
Medical condition — no./total no. (%)			
Chronic kidney disease	14/115 (12)	0	0.21
Diabetes	34/115 (30)	4/17 (24)	0.78
Hypertension	99/115 (86)	15/17 (88)	>0.99
Stroke	13/115 (11)	1/17 (6)	0.69
Transient ischemic attack	8/115 (7)	2/17 (12)	0.62
Chronic lung disease	29/113 (26)	5/17 (29)	0.77
Need for hemodialysis	2/115 (2)	0	1.00
Active cancer	2/111 (2)	0	1.00
Peripheral arterial disease	26/114 (23)	3/17 (18)	0.76
Coronary artery disease	49/115 (43)	10/17 (59)	0.21
Myocardial infarction	16/115 (14)	5/17 (29)	0.15
Atrial fibrillation	36/115 (31)	3/17 (18)	0.39
New York Heart Association class — no. (%)			0.38
I	1 (1)	0	
II	19 (17)	5 (29)	
III	65 (57)	10 (59)	
IV	30 (26)	2 (12)	
Surgical procedure — no. (%)			
PCI	20 (17)	6 (35)	0.08
CABG	18 (16)	5 (29)	0.18
Previous aortic-valve surgery	3 (3)	0	1.00
Pacemaker	13 (11)	0	0.22
Balloon aortic valvuloplasty	4 (3)	0	1.00

* Plus-minus values are means ±SD. Included are data for 132 patients listed in the SAVORY registry (St. Jude Medical) and the RESOLVE registry (Cedars-Sinai Heart Institute).

9 of 17 patients in the registries (median interval, 169 days) (Fig. 1). The decision as to whether to administer anticoagulants to patients with reduced leaflet motion was left to the treating physician and was influenced by the bleeding risk and the uncertain clinical significance of this finding.

Among the 21 patients in the PORTICO IDE study and the pooled registries who underwent follow-up CT, normal leaflet motion recovered in all 11 patients who started or continued to receive therapeutic anticoagulation but persisted in 9 of 10 patients who did not receive anticoagulation ($P<0.001$) (Fig. S4 in the Supplementary Appen-

dix and videos). One patient who was taking aspirin had resolution of reduced leaflet motion on follow-up CT at 303 days. In 1 patient with reduced leaflet motion, CT that was performed 3 months after the discontinuation of warfarin revealed normal motion of the previously involved leaflet but reduced motion in a different leaflet (Fig. S5 in the Supplementary Appendix). Another patient with a surgical valve who had initially been excluded from the RESOLVE registry on the basis of an inconclusive 30-day CT scan was noted to have reduced motion of the surgical-valve leaflet on follow-up CT at 3 months.

Table 3. Clinical Outcomes.

Outcome	Normal Leaflet Motion	Reduced Leaflet Motion	P Value*
	<i>number of patients</i>		
PORTICO IDE study			
Patients in study	33	22	
Death†	1	2	0.56
Myocardial infarction‡	1	1	>0.99
Stroke or transient ischemic attack§	0	2	0.16
Stroke	0	2	0.16
Transient ischemic attack	0	0	>0.99
Pooled registries			
Patients in group	115	17	
Death	0	0	>0.99
Myocardial infarction	0	0	>0.99
Stroke or transient ischemic attack¶	1	3	0.007
Stroke	1	0	>0.99
Transient ischemic attack	0	3	0.002

* P values were calculated with the use of Fisher's exact test.

† One patient with normal leaflet motion died 111 days after valve implantation from congestive heart failure. Of the two deaths among patients with reduced leaflet motion, one was the result of a myocardial infarction 147 days after valve implantation and the other was the result of pneumonia 249 days after valve implantation.

‡ The myocardial infarction occurred 1 day after valve implantation and 27 days before computed tomography (CT) in the group with normal leaflet motion and 147 days after valve implantation and 114 days after CT in the group with reduced leaflet motion.

§ In the two patients with stroke, the event occurred 6 hours after TAVR (with CT performed 1 day after TAVR) in one patient and 1 day after TAVR (with CT performed 28 days after TAVR) in the second patient. The first patient had multiple risk factors for stroke, including atrial fibrillation and substantial spontaneous echo contrast in the left atrium on echocardiography during TAVR.

¶ In the group with normal leaflet motion, one patient had a stroke 1 day after TAVR (with CT performed 35 days after TAVR). In the group with reduced leaflet motion, three patients had transient ischemic attacks: one that occurred 15 days after TAVR (with CT performed 39 days after TAVR), a second that occurred 239 days after TAVR (with CT performed 24 days after TAVR), and a third that occurred 147 days after TAVR (with CT performed 32 days after TAVR).

CLINICAL OUTCOMES

Clinical outcomes are shown in Table 3. There were no significant between-group differences in clinical outcomes in the PORTICO IDE trial. In the pooled RESOLVE and SAVORY cohorts, patients with reduced leaflet motion in the registries had a higher incidence of stroke or TIA than did those with normal leaflet motion (3 of 17 patients [18%] vs. 1 of 115 patients [1%], $P=0.007$), although the total number of events was extremely small.

DISCUSSION

In this study, reduced aortic-valve leaflet motion, as identified on four-dimensional, volume-ren-

dered CT, was observed in patients after TAVR or surgical aortic-valve replacement with a bioprosthetic valve. We made several observations with regard to the phenomenon of reduced leaflet motion: it appeared to be hemodynamically subclinical at the time of detection, with normal aortic-valve gradients on echocardiography; it occurred in multiple prosthesis types; it was detected on CT or transesophageal echocardiography but was missed on transthoracic echocardiography; and it had a lower prevalence among patients receiving therapeutic anticoagulation than among those receiving subtherapeutic or no anticoagulation. These findings, along with hypoattenuating opacities in the corresponding leaflets on two-dimensional CT, suggest that the

reduced leaflet motion that we observed could be associated with subclinical leaflet thrombosis. However, our study is limited by the absence of pathological confirmation, so the interpretation of reduced leaflet motion as thrombosis is based only on the imaging characteristics and its resolution with anticoagulation.

Symptomatic transcatheter aortic-valve thrombosis is rare (occurring in <1% of cases).¹⁰⁻¹⁴ Only five cases of subclinical leaflet thrombosis in transcatheter aortic valves have been reported.^{15,16} On the presumption that our finding of reduced leaflet motion does represent subclinical thrombosis, our study does not permit any precise estimate of the frequency with which the problem occurs, since we evaluated only a small number of patients and the timing and repetition of imaging were not systematic. However, the fact that reduced leaflet motion was found fairly frequently in three small cohorts suggests that the phenomenon is not uncommon.

Our study also shows that although transthoracic echocardiography may rule out valve stenosis or incompetence, it has limited usefulness in the detection of the subclinical form of reduced leaflet motion reported here, owing to inadequate visualization within the valve stent frame and normal aortic-valve gradients. The lack of elevated aortic-valve gradients despite reduced leaflet motion, a seemingly paradoxical observation, was validated with benchtop hydrodynamic testing in a pulse duplicator model (for details, see the Supplementary Appendix). In this model, the forced closure of one leaflet (and occasionally, even two leaflets) of a transcatheter aortic valve was associated with only a minor increase in the transvalvular gradient, which in clinical practice might be considered to be the upper limit of the normal range for bioprosthetic valves (Table S5 and Fig. S6 in the Supplementary Appendix).

Reduced leaflet motion was more prevalent among patients who were receiving subtherapeutic or no anticoagulation than among those receiving therapeutic anticoagulation at the time of the index CT after TAVR. Furthermore, therapeutic anticoagulation was associated with resolution of the hypodense areas overlying the leaflets, with restoration of normal leaflet motion (in all 11 patients), whereas reduced leaflet motion persisted in the majority of patients who

were not receiving anticoagulation (in 9 of 10 patients). These observations suggest that the observed reduced leaflet motion is due to thrombosis. Normalization of leaflet motion with anticoagulation also suggests that thrombus formation is the primary event leading to reduced leaflet motion rather than reduced leaflet motion leading to the formation of an overlying thrombus.

The finding that patients with reduced leaflet motion in the registries had a higher incidence of strokes or TIAs than did those with normal leaflet motion is preliminary and inconclusive. Overall, only six neurologic events were observed (two strokes in the PORTICO IDE study and one stroke and three TIAs in the registries), and all strokes occurred within 1 day after the TAVR procedure and before four-dimensional CT was performed. It is more likely that these first-day strokes were related to the procedural aspects of TAVR rather than to leaflet thrombosis. The cause of strokes or TIAs after TAVR is multifactorial and includes embolization of both thrombotic and nonthrombotic material from aortic, left ventricular, or native-valve instrumentation and new or preexisting atrial fibrillation, in addition to thromboembolism from bioprosthetic leaflets. Nonetheless, our findings raise the concern that patients undergoing TAVR or surgical aortic-valve replacement with a bioprosthetic valve could be at greater risk for leaflet thrombosis and consequent embolic stroke than has previously been recognized. Further and more systematic study of this phenomenon to clarify the mechanism and assess the clinical consequences seems desirable.

In conclusion, reduced aortic-valve leaflet motion occurred in patients with bioprosthetic aortic valves and was easily detected noninvasively by four-dimensional, volume-rendered CT. Therapeutic anticoagulation with warfarin, but not therapy with antiplatelet drugs, prevented and effectively treated this phenomenon. Better characterization of this observation is needed to determine its frequency and evaluate its clinical effect.

Supported by St. Jude Medical (PORTICO IDE trial and SAVORY registry) and Cedars-Sinai Heart Institute (RESOLVE registry).

Disclosure forms provided by the authors are available with the full text of this article at NEJM.org.

We thank Barathi Sethuraman, Ph.D., for data analysis.

APPENDIX

The authors' full names and academic degrees are as follows: Raj R. Makkar, M.D., Gregory Fontana, M.D., Hasan Jilaihawi, M.D., Tarun Chakravarty, M.D., Klaus F. Kofoed, M.D., D.M.Sc., Ole de Backer, M.D., Ph.D., Federico M. Asch, M.D., Carlos E. Ruiz, M.D., Niels T. Olsen, M.D., Ph.D., Alfredo Trento, M.D., John Friedman, M.D., Daniel Berman, M.D., Wen Cheng, M.D., Mohammad Kashif, M.D., Vladimir Jelnin, M.D., Chad A. Kliger, M.D., Hongfei Guo, Ph.D., Augusto D. Pichard, M.D., Neil J. Weissman, M.D., Samir Kapadia, M.D., Eric Manasse, M.D., Deepak L. Bhatt, M.D., M.P.H., Martin B. Leon, M.D., and Lars Søndergaard, M.D.

From Cedars-Sinai Heart Institute (R.R.M., H.J., T.C., A.T., J.F., D.B., W.C., M.K.) and Cedars-Sinai Medical Center (G.F.) — both in Los Angeles; Rigshospitalet, University of Copenhagen, Copenhagen (K.F.K., O.B., N.T.O., L.S.); MedStar Health Research Institute, Washington, DC (F.M.A., A.D.P., N.J.W.); Hackensack University Medical Center and Joseph M. Sanzari Children's Hospital, Hackensack, NJ (C.E.R., V.J.); Lenox Hill Heart and Vascular Institute of New York (C.A.K.) and Columbia University Medical Center—New York Presbyterian Hospital (M.B.L.) — both in New York; St. Jude Medical, Plymouth, MN (H.G., E.M.); Cleveland Clinic, Cleveland (S.K.); and Brigham and Women's Hospital Heart and Vascular Center and Harvard Medical School — both in Boston (D.L.B.).

REFERENCES

- Leon MB, Smith CR, Mack M, et al. Transcatheter aortic-valve implantation for aortic stenosis in patients who cannot undergo surgery. *N Engl J Med* 2010;363:1597-607.
- Smith CR, Leon MB, Mack MJ, et al. Transcatheter versus surgical aortic-valve replacement in high-risk patients. *N Engl J Med* 2011;364:2187-98.
- Popma JJ, Adams DH, Reardon MJ, et al. Transcatheter aortic valve replacement using a self-expanding bioprosthesis in patients with severe aortic stenosis at extreme risk for surgery. *J Am Coll Cardiol* 2014;63:1972-81.
- Adams DH, Popma JJ, Reardon MJ, et al. Transcatheter aortic-valve replacement with a self-expanding prosthesis. *N Engl J Med* 2014;370:1790-8.
- Kapadia SR, Leon MB, Makkar RR, et al. 5-Year outcomes of transcatheter aortic valve replacement compared with standard treatment for patients with inoperable aortic stenosis (PARTNER 1): a randomised controlled trial. *Lancet* 2015;385:2485-91.
- Mack MJ, Leon MB, Smith CR, et al. 5-Year outcomes of transcatheter aortic valve replacement or surgical aortic valve replacement for high surgical risk patients with aortic stenosis (PARTNER 1): a randomised controlled trial. *Lancet* 2015;385:2477-84.
- Zoghbi WA, Chambers JB, Dumesnil JG, et al. Recommendations for evaluation of prosthetic valves with echocardiography and Doppler ultrasound: a report from the American Society of Echocardiography's Guidelines and Standards Committee and the Task Force on Prosthetic Valves, developed in conjunction with the American College of Cardiology Cardiovascular Imaging Committee, Cardiac Imaging Committee of the American Heart Association, the European Association of Echocardiography, a registered branch of the European Society of Cardiology, the Japanese Society of Echocardiography and the Canadian Society of Echocardiography, endorsed by the American College of Cardiology Foundation, American Heart Association, European Association of Echocardiography, a registered branch of the European Society of Cardiology, the Japanese Society of Echocardiography, and Canadian Society of Echocardiography. *J Am Soc Echocardiogr* 2009;22:975-1014.
- Baumgartner H, Hung J, Bermejo J, et al. Echocardiographic assessment of valve stenosis: EAE/ASE recommendations for clinical practice. *J Am Soc Echocardiogr* 2009;22:1-23.
- Lang RM, Badano LP, Mor-Avi V, et al. Recommendations for cardiac chamber quantification by echocardiography in adults: an update from the American Society of Echocardiography and the European Association of Cardiovascular Imaging. *J Am Soc Echocardiogr* 2015;28(1):1.e14-39.e14.
- Latib A, Naganuma T, Abdel-Wahab M, et al. Treatment and clinical outcomes of transcatheter heart valve thrombosis. *Circ Cardiovasc Interv* 2015;8:8.
- De Backer O, Ihlemann N, Olsen NT, Vejstrup N, Søndergaard L. Intracardiac echocardiography unveils large thrombus on a restenotic TAVR prosthesis more than 6 years after implantation. *Eur Heart J* 2015 March 22 (Epub ahead of print).
- De Marchena E, Mesa J, Poment S, et al. Thrombus formation following transcatheter aortic valve replacement. *JACC Cardiovasc Interv* 2015;8:728-39.
- Trepels T, Martens S, Doss M, Fichtlscherer S, Schächinger V. Thrombotic restenosis after minimally invasive implantation of aortic valve stent. *Circulation* 2009;120(4):e23-e24.
- Lancellotti P, Moura L, Pierard LA, et al. European Association of Echocardiography recommendations for the assessment of valvular regurgitation. Part 2: mitral and tricuspid regurgitation (native valve disease). *Eur J Echocardiogr* 2010;11:307-32.
- Leetmaa T, Hansson NC, Leipsic J, et al. Early aortic transcatheter heart valve thrombosis: diagnostic value of contrast-enhanced multidetector computed tomography. *Circ Cardiovasc Interv* 2015;8:8.
- Pache G, Blanke P, Zeh W, Jander N. Cusp thrombosis after transcatheter aortic valve replacement detected by computed tomography and echocardiography. *Eur Heart J* 2013;34:3546.

Copyright © 2015 Massachusetts Medical Society.

RECEIVE IMMEDIATE NOTIFICATION WHEN AN ARTICLE IS PUBLISHED ONLINE FIRST

To be notified by e-mail when *Journal* articles are published Online First, sign up at NEJM.org.