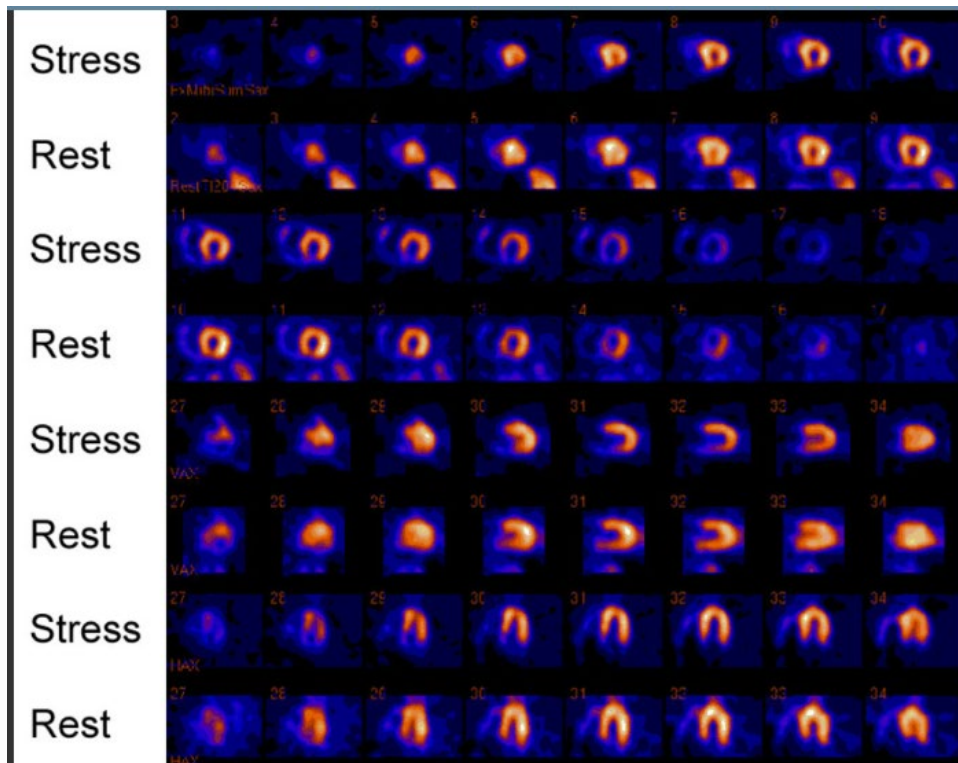


Sample Questions for Certified Cardiovascular Knowledge Examination

Question 1

A 70-year-old man with coronary artery disease comes for evaluation because of a three-week history of chest pain. Nine months ago, he sustained an MI and underwent percutaneous revascularization. Current medications include aspirin 81 mg daily, metoprolol 25 mg twice daily, rosuvastatin 40 mg daily, lisinopril 10 mg daily, and amlodipine 5 mg daily. Heart rate is 83/min, respirations are 18/min, and blood pressure is 120/80 mm Hg. Lungs are clear to auscultation. Cardiac exam discloses a regular rhythm and no murmurs. The patient exercises for nine minutes on the Bruce protocol and achieves 82% of his maximum predicted heart rate. Myocardial perfusion images are shown.



Which of the following arteries is most likely causing the perfusion abnormality?

- A. Left anterior descending
- B. Left circumflex
- C. Left main
- D. Right coronary

Question 2

An autopsy is being performed on a 20-year-old man who died while playing in an intramural soccer game at his university. He collapsed suddenly; there was no trauma. Teammates and paramedics were unable to resuscitate him. According to his roommate, he had felt well for the several weeks just prior to his death. He had no history of serious illness or drug use.

Which of the following is the most likely finding on autopsy?

- A. Aberrant origin of the right coronary artery
- B. Increased acid mucopolysaccharide-rich ground substance
- C. Intracoronary thrombus
- D. Myofiber and intracellular myofibrillar disarray
- E. Structurally normal heart

Question 3

A 70-year-old woman comes for a routine annual physical exam. She reports that she feels well and exercises daily. She has a history of hypertension managed with lisinopril and amlodipine. She monitors her blood pressure at home; it ranges from 110/60 to 125/75 mm HG. Additional medications include aspirin 81 mg daily, calcium and vitamin D supplements and monthly alendronate to prevent osteoporosis. The patient is 5 ft 3 in tall and weight 150 lb; BMI is 26.6 kg/m². Heart rate is 75/min, respirations are 10/min, and blood pressure is 135/80 mm HG. Jugular venous pressure is 6 cm H₂O. Carotid artery upstrokes are normal; there is a faint bruit on the left. Lungs are clear to auscultation. Cardiac exam discloses a single S₁ and a physiologically split S₂; there are no murmurs. There are no abdominal bruits. Posterior tibialis and dorsalis pedis pulses are 2+. Laboratory studies show the following:

Blood

- Cholesterol, total 210 mg/dL
- HDL 44 mg/dL
- LDL 120 mg/dL
- Triglycerides 210 mg/dL

Carotid artery ultrasonography shows stenosis of 65% on the left and less than 49% on the right.

Which of the following is the most appropriate pharmacotherapy?

- A. Clopidogrel
- B. Dipyridamole
- C. Hydrochlorothiazide
- D. Rosuvastatin
- E. Warfarin

Question 4

A 44-year-old woman is referred for evaluation of a diastolic cardiac murmur. Cardiac exam discloses reduced intensity of S1 and S2; there is reverse splitting of S2. A diastolic cardiac murmur can be heard best when the diaphragm of the stethoscope is placed over the left sternal border with the patient sitting, leaning forward and holding her breath in full expiration.

Which of the following is the most likely cause of the murmur?

- A. Aortic regurgitation
- B. Atrial septal defect
- C. Mitral stenosis
- D. Patent ductus arteriosus
- E. Tricuspid stenosis

Question 5

A 69-year-old woman is brought to the emergency department because of a two-hour history of severe chest pain, diaphoresis, and nausea. The patient has a history of type 2 diabetes mellitus and hypertension; there is no history of coronary heart disease. Current medications include aspirin, lisinopril, metformin, and simvastatin. The patient smoked one pack of cigarettes daily for 30 years but quit smoking five years ago. Heart rate is 90/min, respirations are 18/min, and blood pressure is 92/70 mm Hg. Lungs are clear to auscultation. Cardiac examination discloses normal S1 and S2 without murmur. The extremities are clammy and cool to touch. ECG shows ST segment elevation in leads V2 and V4. While waiting for transfer to the catheterization laboratory, the patient develops ventricular fibrillation and is defibrillated to restore sinus rhythm. Cardiac catheterization shows an occluded proximal left anterior descending coronary artery. This patient immediately undergoes thrombectomy, balloon angioplasty, and placement of a drug-eluting stent. TIMI 3 flow is established. ECG shows an >50% improvement in the ST segment elevations; they do not completely resolve. The patient is admitted to the intensive care unit. Thirty minutes later, the cardiac monitor shows 15 consecutive beats of wide complex rhythm at 80/min. Sinus rhythm occurs without intervention; the patient has no symptoms.

Which of the following is the most likely cause of this patient's dysrhythmia after percutaneous intervention?

- A. Acute stent thrombosis
- B. Coronary artery reperfusion
- C. Distal coronary artery embolization
- D. Electrolyte imbalance
- E. Left ventricular aneurysm

Answers

Question 1 – D. Right coronary

Question 2 – D. Myofiber and intracellular myofibrillar disarray

Question 3 – D. Rosuvastatin

Question 4 – A. Aortic regurgitation

Question 5 - B. Coronary artery reperfusion