



ACC Latin America
Conference 2017



MEXICO CITY
JUNE 22 – 24, 2017

GLOBAL EXPERTS, LOCAL LEARNING

VALVULAR HEART DISEASE

Regurgitation Valvular Lessons 2017



ACC Latin America
Conference 2017


Aortic Regurgitation & Aorta Evaluation



Jorge Eduardo Cossío-Aranda MD, FACC
Chairman of Outpatient Care Department
Instituto Nacional de Cardiología Ignacio Chávez
Mexico City.

No disclosure.

Painting the history of cardiology: “The clinical concept”



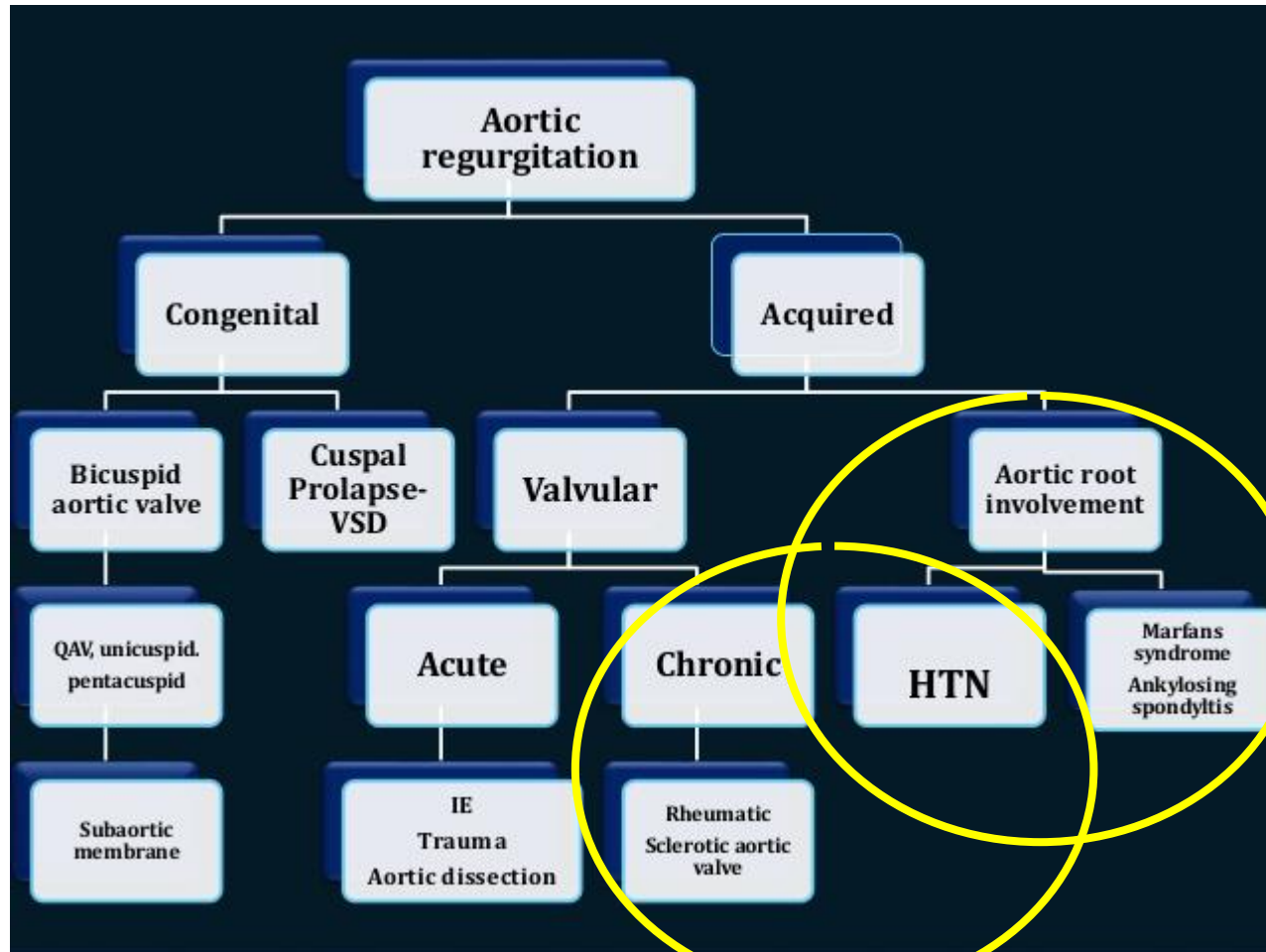
Harvey
Laenec
Cowper
Laubry
Vieusens
Morgagni
Corrigan
Duroziez
Quincke
Traube
Mussel
Landolfi
Muller

**Murales del Instituto Nacional de Cardiología “Ignacio Chávez”
Pintados por Diego Rivera.**

Causes of Aortic Regurgitation



ACC Latin America
Conference 2017



Stage of Chronic Aortic Regurgitation



ACC Latin America
Conference 2017

Stage	Definition	Valve Anatomy	Valve Hemodynamics	Hemodynamic Consequences	Symptoms
A	<u>At risk of AR</u>	<ul style="list-style-type: none">• <i>Bicuspid aortic valve (or other congenital valve anomaly)</i>• <i>Aortic valve sclerosis</i>• <i>Diseases of the aortic sinuses or ascending aorta</i>• <i>History of rheumatic fever or known rheumatic heart disease</i>• <i>IE</i>	<ul style="list-style-type: none">• AR severity none or trace	<ul style="list-style-type: none">• None	<ul style="list-style-type: none">• None

2017 AHA/ACC Focused Update of the 2014 AHA/ACC Guideline for the Management of Patients With Valvular Heart Disease: A Report of the American College of Cardiology/American Heart Association Task Force on Clinical Practice Guidelines. <http://circ.ahajournals.org/lookup/suppl/doi:10.1161/CIR.0000000000000503/-/DC1>.

Volume overload – compensatory mechanisms
LV EDV increases without increase in diastolic pressure
(due to increased compliance)
LV preload reserve is maintained initially
Eccentric hypertrophy

Increased afterload
Increased chamber volume
Increased systolic wall stress and afterload
Concentric LVH
Continued increase in chamber volume and afterload

Descompensation

Afterload mismatch (reversible)
Impaired LV contractility (irreversible)

Stage of Chronic Aortic Regurgitation



ACC Latin America
Conference 2017

Stage	Definition	Valve Anatomy	Valve Hemodynamics	Hemodynamic Consequences	Symptoms
B	<u>Progressive AR</u>	<ul style="list-style-type: none"> • Mild-to-moderate calcification of a trileaflet valve bicuspid aortic valve (or other congenital valve anomaly) • Dilated aortic sinuses • Rheumatic valve changes • Previous IE 	<ul style="list-style-type: none"> • Mild AR: <ul style="list-style-type: none"> ◦ Jet width <25% of LVOT ◦ Vena contracta <0.3 cm ◦ RVol <30 mL/beat ◦ RF <30% ◦ ERO <0.10 cm² ◦ Angiography grade 1+ • Moderate AR: <ul style="list-style-type: none"> ◦ Jet width 25%–64% of LVOT ◦ Vena contracta 0.3–0.6 cm ◦ RVol 30–59 mL/beat ◦ RF 30%–49% ◦ ERO 0.10–0.29 cm² ◦ Angiography grade 2+ 	<ul style="list-style-type: none"> • Normal LV systolic function • Normal LV volume or mild LV dilation 	<ul style="list-style-type: none"> • None

2017 AHA/ACC Focused Update of the 2014 AHA/ACC Guideline for the Management of Patients With Valvular Heart Disease: A Report of the American College of Cardiology/American Heart Association Task Force on Clinical Practice Guidelines. <http://circ.ahajournals.org/lookup/suppl/doi:10.1161/CIR.0000000000000503/-/DC1>.

Stage of Chronic Aortic Regurgitation



ACC Latin America
Conference 2017

Stage	Definition	Valve Anatomy	Valve Hemodynamics	Hemodynamic Consequences	Symptoms
C	<u>Asymptomatic severe AR</u>	<ul style="list-style-type: none"> • Calcific aortic valve disease • Bicuspid valve (or other congenital abnormality) • Dilated aortic sinuses or ascending aorta • Rheumatic valve changes • IE with abnormal leaflet closure or perforation 	<ul style="list-style-type: none"> • Severe AR: <ul style="list-style-type: none"> ◦ Jet width $\geq 65\%$ of LVOT ◦ Vena contracta >0.6 cm ◦ Holodiastolic flow reversal in the proximal abdominal aorta ◦ RVol ≥ 60 mL/beat ◦ RF $\geq 50\%$ ◦ ERO ≥ 0.3 cm² ◦ Angiography grade 3+ to 4+ ◦ In addition, diagnosis of chronic severe AR requires evidence of LV dilation 	<p>C1: Normal LVEF ($\geq 50\%$) and mild-to-moderate LV dilation (LVESD ≤ 50 mm)</p> <p>C2: Abnormal LV systolic function with depressed LVEF ($<50\%$) or severe LV dilatation (LVESD >50 mm or indexed LVESD >25 mm/m²)</p>	<ul style="list-style-type: none"> • None; exercise testing is reasonable to confirm symptom status

2017 AHA/ACC Focused Update of the 2014 AHA/ACC Guideline for the Management of Patients With Valvular Heart Disease: A Report of the American College of Cardiology/American Heart Association Task Force on Clinical Practice Guidelines. <http://circ.ahajournals.org/lookup/suppl/doi:10.1161/CIR.0000000000000503/-/DC1>.

Stage of Chronic Aortic Regurgitation



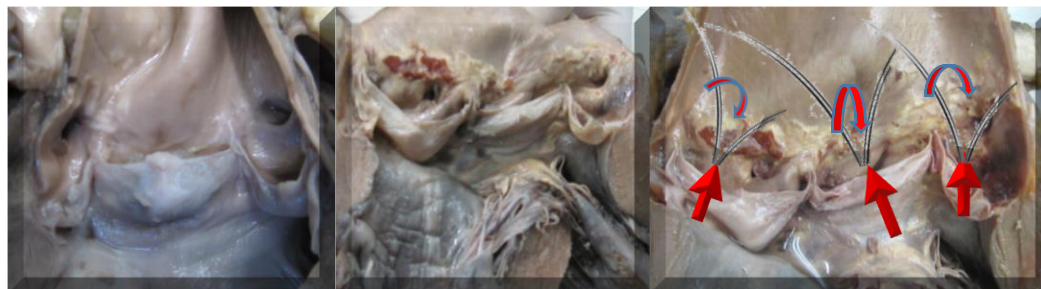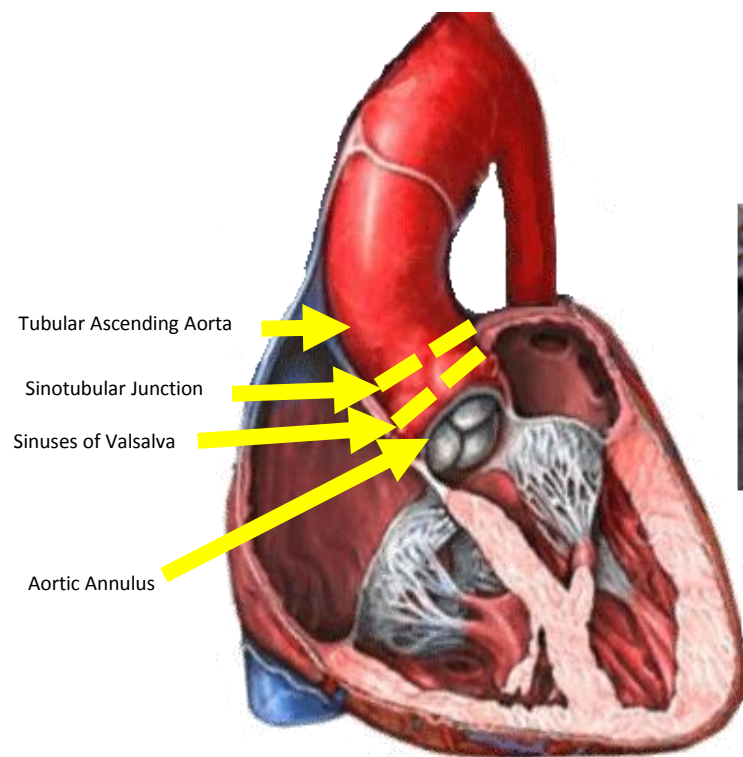
ACC Latin America
Conference 2017

Stage	Definition	Valve Anatomy	Valve Hemodynamics	Hemodynamic Consequences	Symptoms
D	<u>Symptomatic severe AR</u>	<ul style="list-style-type: none"> • Calcific valve disease • Bicuspid valve (or other congenital abnormality) • Dilated aortic sinuses or ascending aorta • Rheumatic valve changes • Previous IE with abnormal leaflet closure or perforation 	<ul style="list-style-type: none"> • Severe AR: <ul style="list-style-type: none"> ◦ Doppler jet width $\geq 65\%$ of LVOT; ◦ Vena contracta >0.6 cm, ◦ Holodiastolic flow reversal in the proximal abdominal aorta, ◦ RVol ≥ 60 mL/beat; ◦ RF $\geq 50\%$; ◦ ERO ≥ 0.3 cm²; ◦ Angiography grade 3+ to 4+ ◦ In addition, diagnosis of chronic severe AR requires evidence of LV dilation 	<ul style="list-style-type: none"> • Symptomatic severe AR may occur with normal systolic function (LVEF $\geq 50\%$), mild-to-moderate LV dysfunction (LVEF 40% to 50%) or severe LV dysfunction (LVEF $<40\%$); • Moderate-to-severe LV dilation is present. 	<ul style="list-style-type: none"> • Exertional dyspnea or angina, or more severe HF symptoms

AR – Complete assessment



ACC Latin America
Conference 2017



2017 AHA/ACC Focused Update of the 2014 AHA/ACC Guideline for the Management of Patients With Valvular Heart Disease: A Report of the American College of Cardiology/American Heart Association Task Force on Clinical Practice Guidelines. <http://circ.ahajournals.org/lookup/suppl/doi:10.1161/CIR.0000000000000503/-/DC1>.

The *sensitivity and specificity of TTE* for diagnosis of aortic dissection are only 60-80%, whereas TEE has a sensitivity of 98% to 100% and a specificity of 95% to 100%.

CT imaging is very accurate, rapid approach to diagnosis at many centers.

CMR imaging is rarely used in unstable patients with suspected dissection.

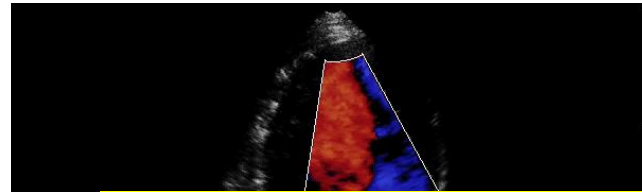
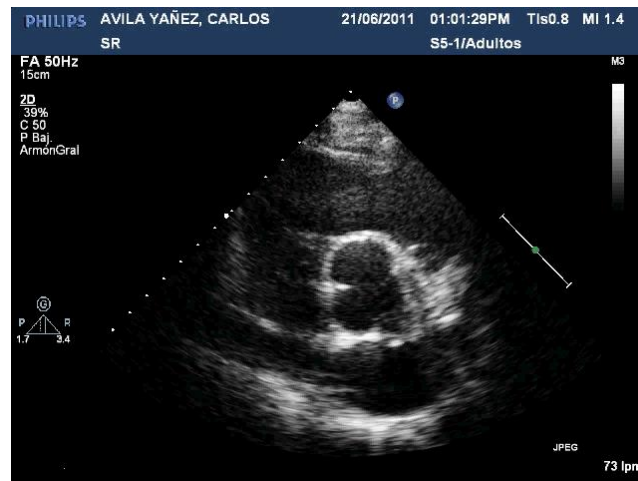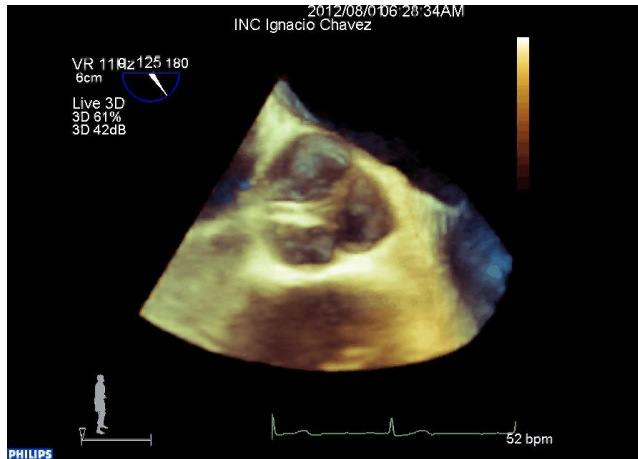
Angiography should be considered only when the diagnosis cannot be determined by noninvasive imaging and when patients have suspected or known CAD, specially those with previous CABG

Recommendations	COR	LOE
TTE is indicated in patients with signs or symptoms of AR (stages A to D) for accurate diagnosis of the cause of regurgitation, regurgitant severity, and LV size and systolic function, and for determining clinical outcome and timing of valve intervention	I	B
TTE is indicated in patients with dilated aortic sinuses or ascending aorta or with a bicuspid aortic valve (stages A and B) to evaluate the presence and severity of AR	I	B

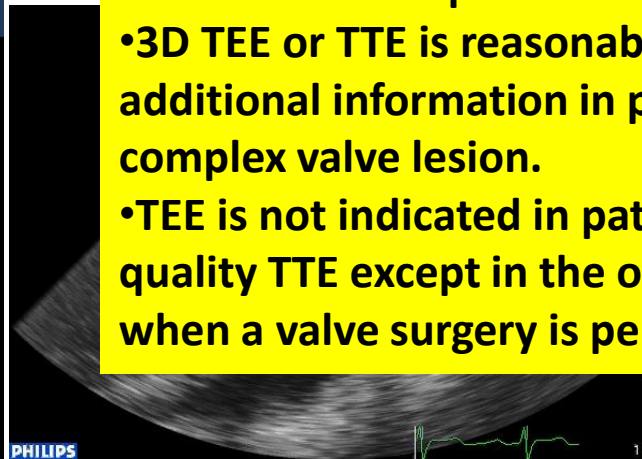
AR, Echo evaluation.

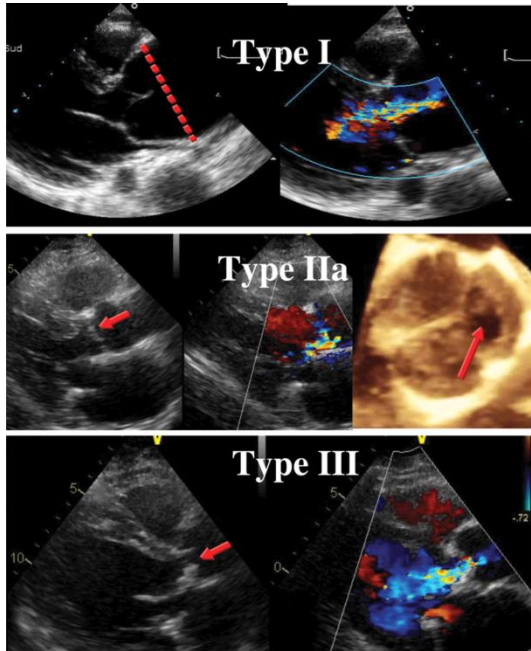


ACC Latin America
Conference 2017



- TTE is recommended as the first-line imaging modality in valvular regurgitation.
- TEE is advocated when TTE is of non-diagnostic value or when further diagnostic refinement is required.
- 3D TEE or TTE is reasonable to provide additional information in patients with complex valve lesion.
- TEE is not indicated in patients with a good-quality TTE except in the operating room when a valve surgery is performed.





- In patients with AR, careful aortic valve analysis is mandatory. *The echo report should include information about the aetiology, the lesion process, and the type of dysfunction.*

- Additional echo findings are used as complementary findings to assess the severity of AR. The assessment of the morphology and dimension of the aortic root is mandatory.

Mechanisms of aortic regurgitation according to the Capentier functional classification. Type I, aortic annulus dilatation; Type IIa, prolapse of the left coronary cusp (arrow); Type III, rheumatic aortic valve disease with restricted cusp motion.

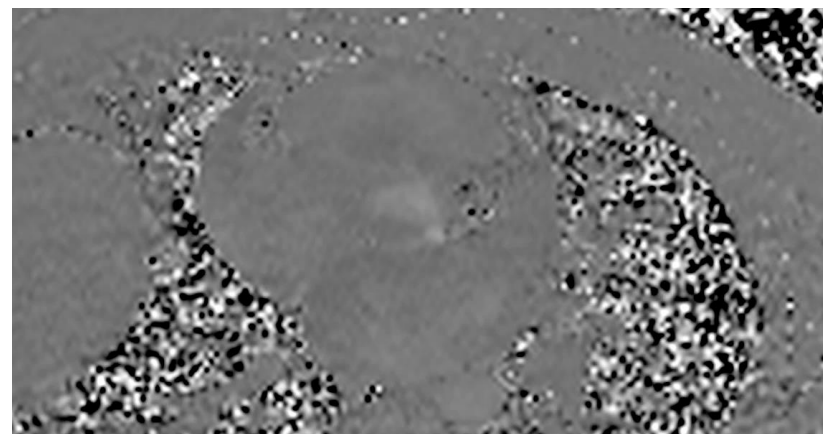
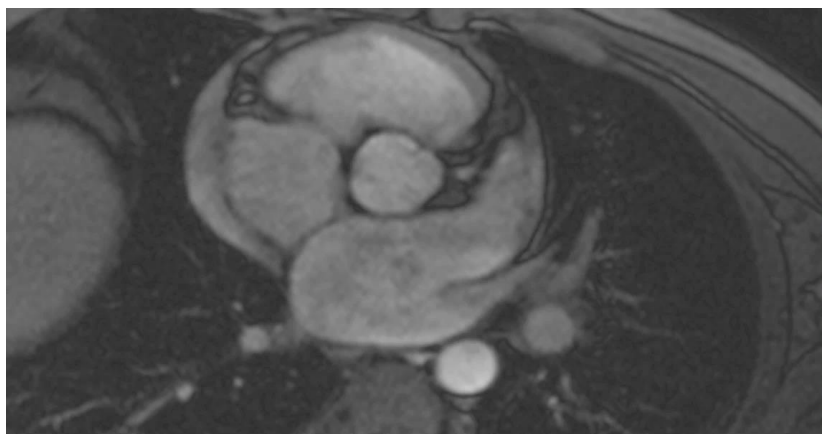
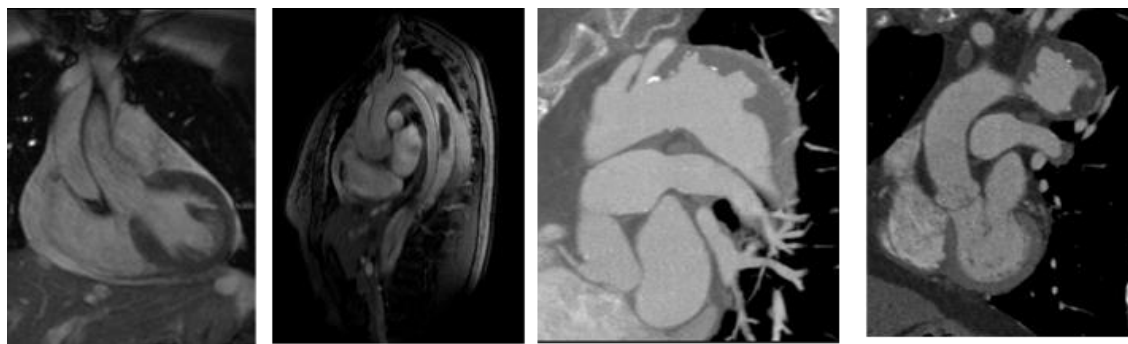


Recommendations	COR	LOE
CMR is indicated in patients with moderate or severe AR (stages B, C, and D) and suboptimal echocardiographic images for the assessment of LV systolic function, systolic and diastolic volumes, and measurement of AR severity	I	B

Aortic Regurgitation: CRM



ACC Latin America
Conference 2017



2017 AHA/ACC Focused Update of the 2014 AHA/ACC Guideline for the Management of Patients With Valvular Heart Disease: A Report of the American College of Cardiology/American Heart Association Task Force on Clinical Practice Guidelines. <http://circ.ahajournals.org/lookup/suppl/doi:10.1161/CIR.0000000000000503/-/DC1>. Heart 2014; 100:1924-32

Dra. Gabriela Meléndez – Resonancia Magnética. Instituto Nacional de Cardiología Ignacio Chàvez.

Recommendations	COR	LOE
Coronary angiography is indicated before valve intervention in patients with symptoms of angina, objective evidence of ischemia, decreased LV systolic function, history of CAD, or coronary risk factors (including men age >40 years and postmenopausal women)	I	C
Coronary angiography should be performed as part of the evaluation of patients with chronic severe secondary MR	I	C

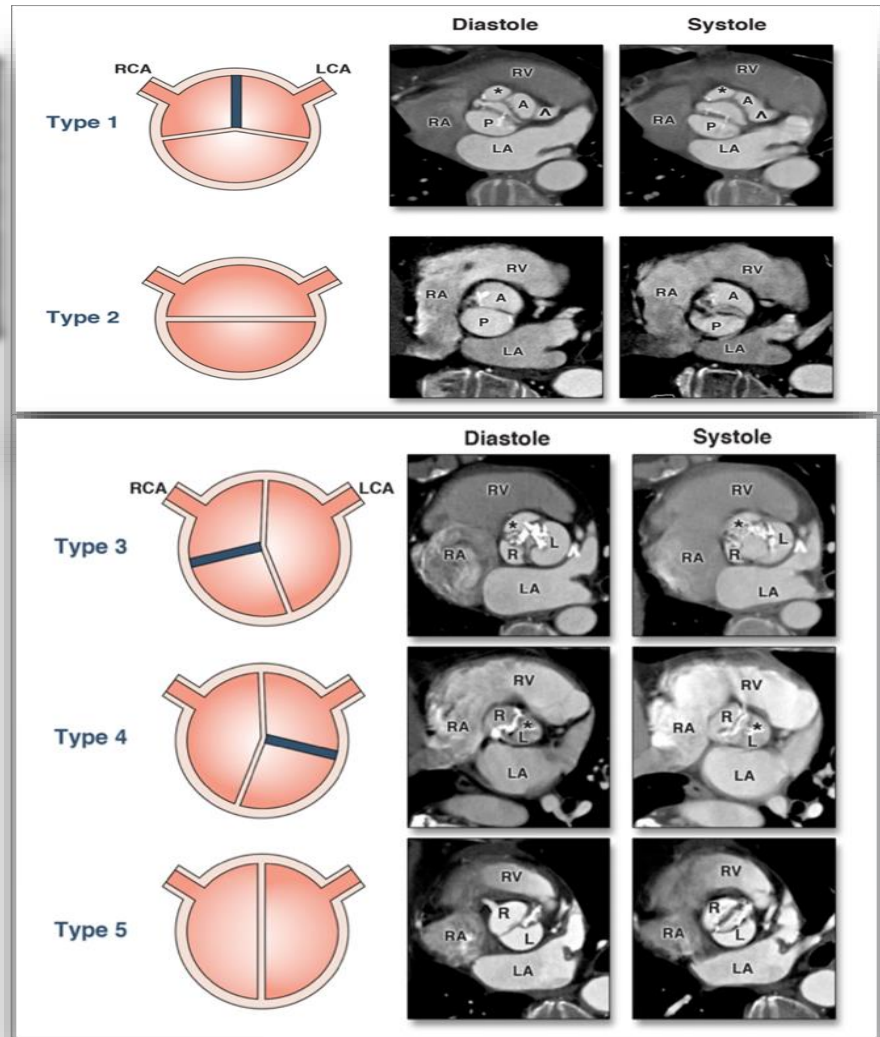
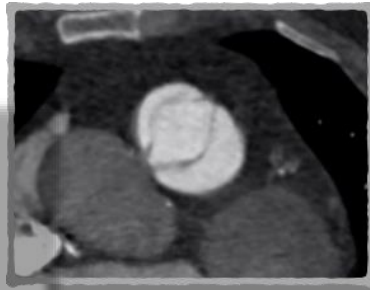
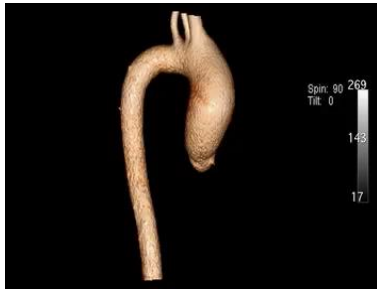Recommendations – Diagnosis & follow up	COR	LOE
An initial <u>TTE</u> is indicated in patients with a known bicuspid aortic valve to evaluate valve morphology, to measure the severity of AS and AR, and to assess the of the aortic shape and diameter sinuses and ascending aorta for prediction of clinical outcome and to determine timing of intervention	I	B
<u>Aortic magnetic resonance angiography or CT angiography</u> is indicated in patients with a bicuspid aortic valve when morphology of the aortic sinuses, sinotubular junction, or ascending aorta cannot be assessed accurately or fully by echocardiography	I	C

Recommendations – Diagnosis & follow up	COR	LOE
Serial evaluation of the size and morphology of the aortic sinuses and ascending aorta by echocardiography, CMR, or CT angiography is recommended in patients with a bicuspid aortic valve and an aortic diameter greater than 4.0 cm, with the examination interval determined by the degree and rate of progression of aortic dilation and by family history. In patients with an aortic diameter greater than 4.5 cm, this evaluation should be performed annually	I	C

Aorta Bivalva: Computed Tomography



ACC Latin America
Conference 2017



NO correlation between the degree of valvular dysfunction and degree of aortic dilatation.

Different phenotypes different etiologies

A genetic study is suggested

J Am Coll Cardiol Img 2013;6: 150-61

Recommendations: Intervention	COR	LOE
Operative intervention to repair the aortic sinuses or replace the ascending aorta is indicated in patients with a bicuspid aortic valve if the diameter of the aortic sinuses or ascending aorta is greater than 5.5 cm	I	B
Operative intervention to repair the aortic sinuses or replace the ascending aorta is reasonable in patients with bicuspid aortic valves if the diameter of the aortic sinuses or ascending aorta is greater than 5.0 cm and a risk factor for dissection is present (family history of aortic dissection or if the rate of increase in diameter is ≥ 0.5 cm per year)	IIa	C



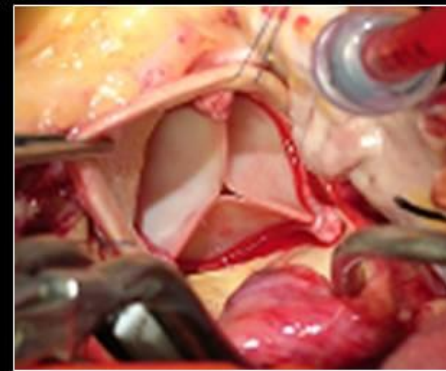
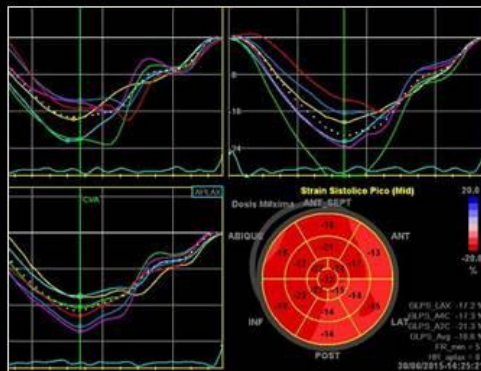
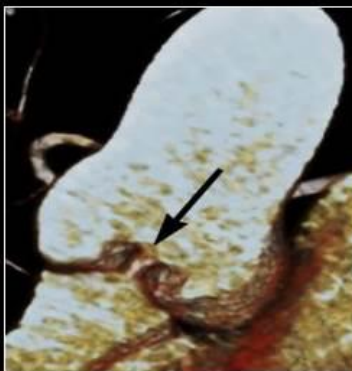
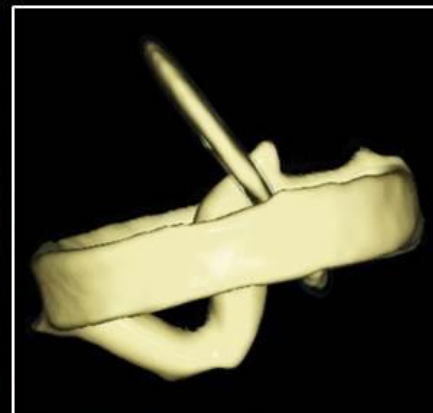
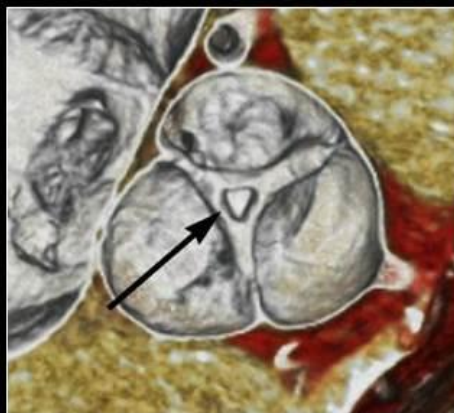
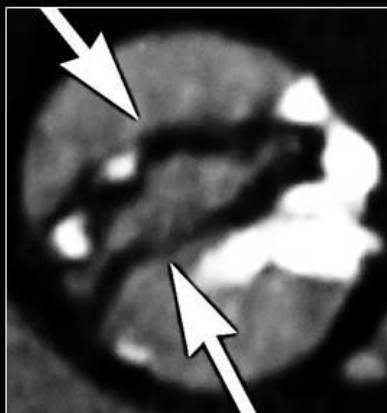
Recommendations: Intervention	COR	LOE
Replacement of the ascending aorta is reasonable in patients with a bicuspid aortic valve who are undergoing aortic valve surgery because of severe AS or AR (Sections 3.4 and 4.4) if the diameter of the ascending aorta is greater than 4.5 cm	Ila	C

- AR, is one of the clinical entities with **more variety of clinical signs** in physical examination.
- **Evaluation of the aortic complex** : Aortic valve, aorta and myocardial function.
- In patients with AR, careful aortic valve analysis by **ECHO** is mandatory. Valve analysis should integrate the assessment of the aetiology, the lesion process, and the type of dysfunction. It is a good guide to the timing of surgery. This should be considered when LV deterioration starts to occur.
- **CMR** is indicated in patients with moderate or severe AR and suboptimal echocardiographic images for the assessment of LV systolic function, systolic and diastolic volumes, and measurement of AR severity (Class I)
- **CT** is excellent option to evaluate bicuspid aortic valve and Aortopathy. There is not correlation between the degree of valvular dysfunction and degree of aortic dilatation.

Aortic Regurgitation Aorta Evaluation



ACC Latin America
Conference 2017



Thank you