



ACC Latin America Conference 2017



MEXICO CITY
JUNE 22 – 24, 2017

GLOBAL EXPERTS, LOCAL LEARNING



ACC Latin America
Conference 2017

Case Study

Presenters:

Adan Pacheco, MD

Alexandro Atilano, MD

Cardiology/Internal Medicine

Hospital Universitario UANL Mty, Mex.



Patient

- Gender: Male
- Age: 39
- Occupation: Production Supervisor
- Religion : Catholic
- Civil Status: Married



History of the current illness

- He presents with dyspnea and orthopnea over past seven days.
- Denies chest pain. Has had palpitations on and off for the past two weeks. No fever or cough. He has been taking all of his medications



Background

- **Allergies:** No known drug allergies (NKDA).
- **Tobacco history:** Smoked 2 packs a month; quit when he was diagnosed with pre-diabetes.
- **Alcohol history:** Drinks 2 beer a week.
- **Family history:** Mother “tachyarrhythmia” carrier of a bicameral pacemaker; father deceased (age 70, colon cancer); 1 brother SVT



Past medical history:

- Appendicectomy 20 years ago
- LBBB dx 7 years ago in a medical check-up no other abnormalities
- Pre-syncope single episode 6 years ago
- Fasting glucose intolerance (prediabetes) and hyperlipidemia managed according to guidelines dx 5 years ago
- Atrial flutter dx 5 years ago treated with elective cardioversion (atrial thrombi discarded by TEE), converted to sinus rhythm.
- Last reported electrocardiogram (January 2017) 1st degree AV block and LBBB.



Medications:

- Aspirin 100mg qd
- Ezetimibe/Simvastatine 10/20mg qd
- Metformin XR 500mg qd

Physical exam

Vitals

BP = 134/82 mm Hg

HR = 88 bpm at rest
irregularly irregular
pattern

BR = 13 bmp

SatO₂: 95% RA

T°: 37.6°C

Height: 1.7 m

Weight: 80 kg

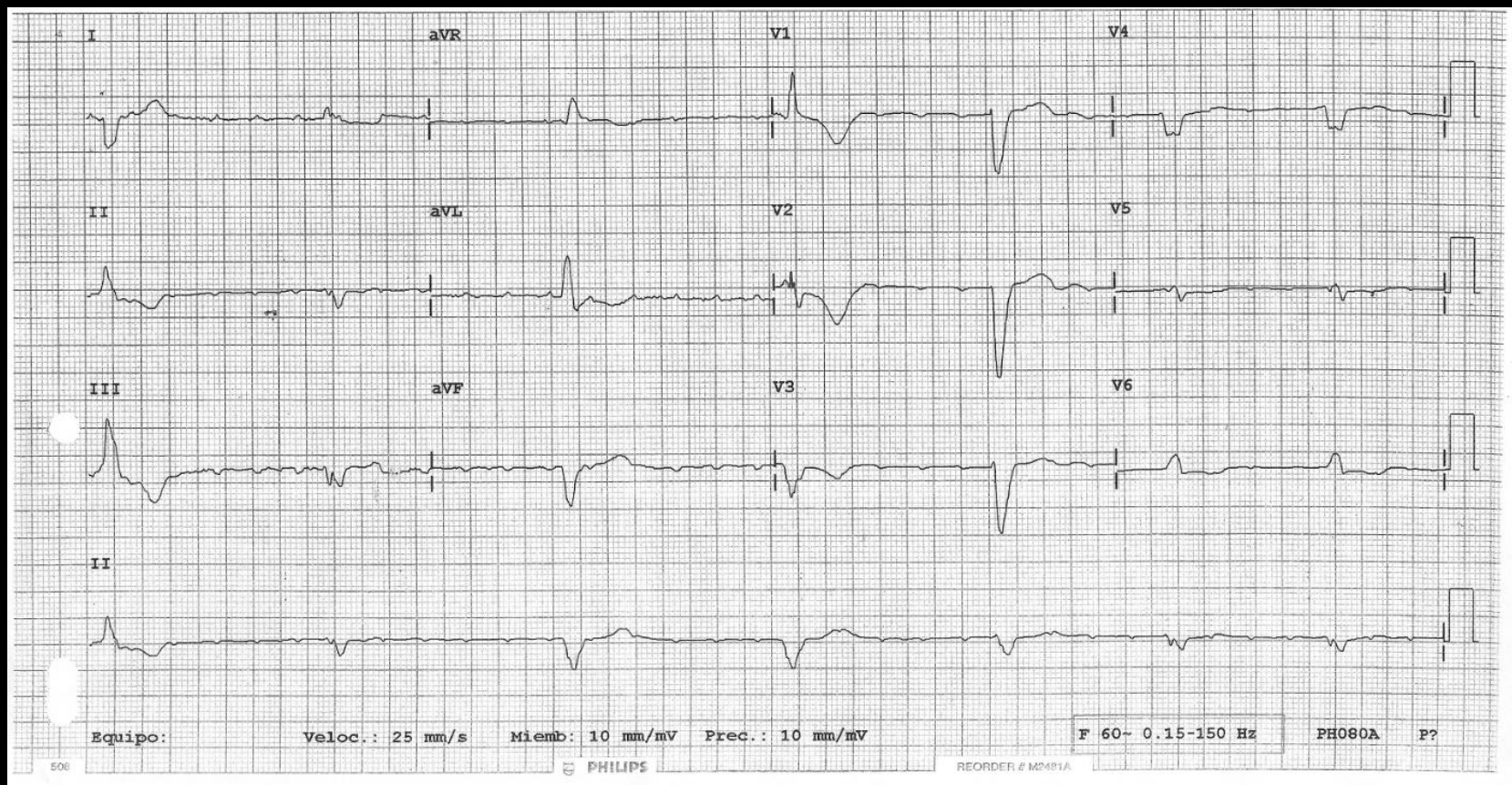
BMI: 27.68 Kg/m²

The remainder of his examination is completely normal with no clinical evidence of right- or left-sided congestive heart failure.

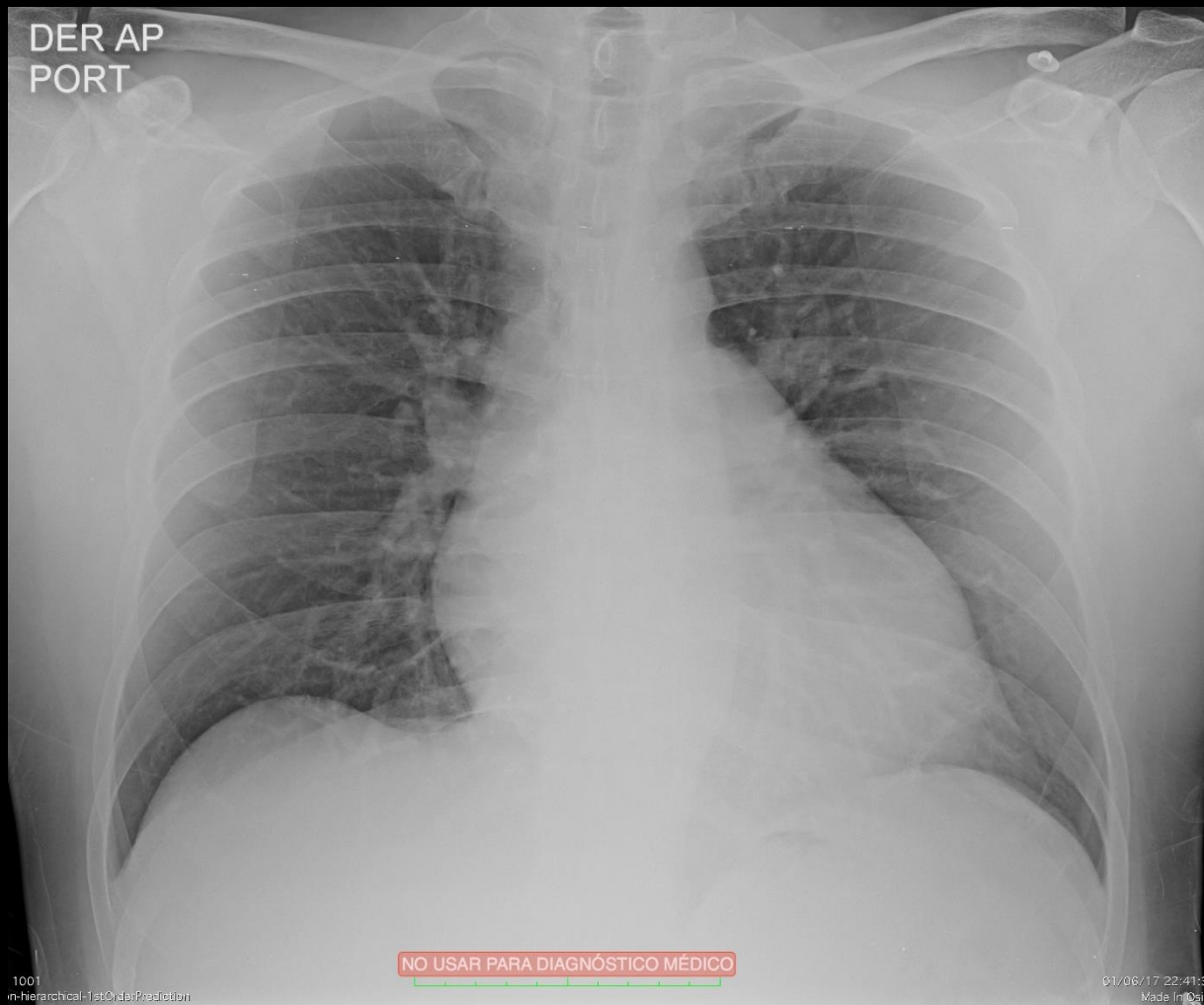


Lab's

- **Chem:** Glu 102/Creat 0.9/BUN 18.
- **Electrolytes** normal.
- **Urinalysis** normal.
- **CBC** normal.
- **LFT's** normal. INR 1.1
- **TFT** TSH 3.2 FT4 1.53



DER AP
PORT



NO USAR PARA DIAGNÓSTICO MÉDICO

1001
m-hierarchical-1stOrderPrediction

01/06/17 22:41:33
Made in Brazil

Echocardiogram

Ecocrd. adultos

S5-1

45Hz

15cm

2D/MM

68% 62%

C 50

P Baj.

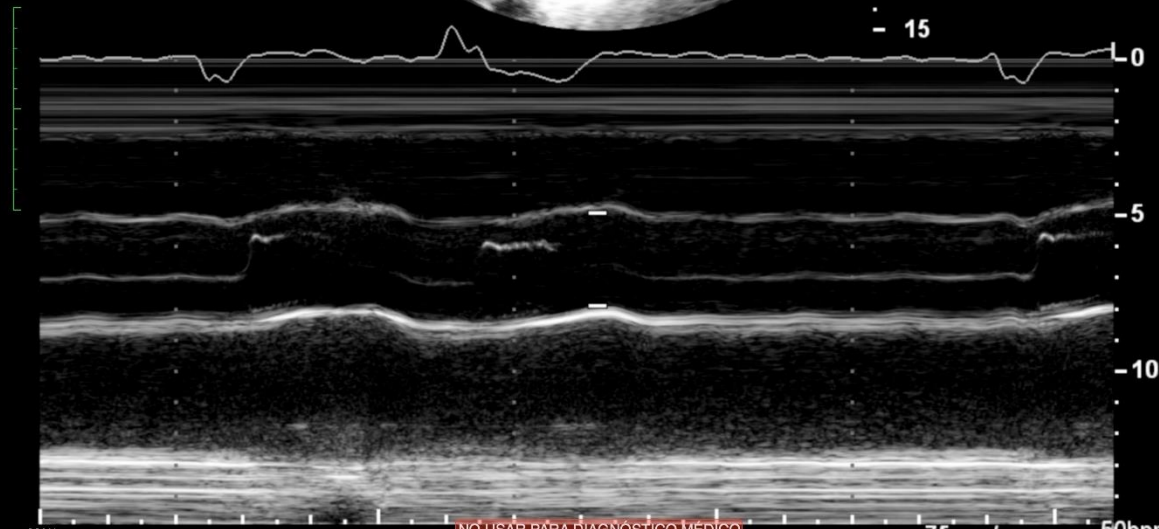
PenArmón

TIS0.6 MI 1.2

M3

Dist 2.97 cm

0
10
15



com: 220%

1: 4/27 Series: 1

titleEndanExplicit

NO USAR PARA DIAGNOSTICO MEDICO

75mm/s

50bpm

2006/17 11:18:30
Made in Osirix

Ecocrd. adultos

S5-1

47Hz

17cm

2D

76%

C 50

P Baj.

PenArmón

G
R
1.3 2.6

✦ A4CÁM d

VI-Long 7.19 cm

VI-Área 31.9 cm²

VI-Vol 116 ml

VTD (A4CÁM) 116 ml

Zoom
m. 1
UltraEndianDopler

NO USAR PARA DIAGNÓSTICO MÉDICO

TIS0.4 Ecocrd. adultos

S5-1

47Hz

17cm

2D

76%

C 50

P Baj.

PenArmón

G
R
1.3 2.6

✦ A4CÁM s

VI-Long 5.70 cm

VI-Área 17.5 cm²

VI-Vol 47.6 ml

VTs (A4CÁM) 47.5 ml

FE (A4CÁM) 59.1 %

Zoom
m. 1
UltraEndianDopler

NO USAR PARA DIAGNÓSTICO MÉDICO

TIS0.4 MI 1

- 0

- 5

X2 10

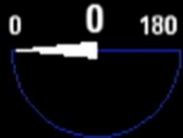- 15

43k
02/0

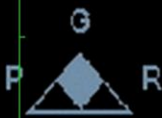Ecocrd. adultos

TISO.1 MI 0.4

X7-2t
53Hz
13cm



2D
68%
C 50
P Des.
Gral.



- 0 M4

- 5

X3

- 10

PAT T: 37.0C
TEMP. ETE< 37.0C

NO USAR PARA DIAGNÓSTICO MÉDICO

46 lpm

02/06/17 11:35:29
Made In OsiriX

Ecocrd. adultos

TIS0.1 MI 0.4

X7-2t

53Hz

15cm

Z 1.7

2D

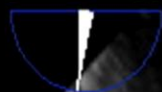
69%

C 50

P Des.

Gral.

0 83 180



M4



- 5



- 10

PAT T: 37.0C

TEMP. ETE: 37.5C

NO USAR PARA DIAGNÓSTICO MÉDICO

60 lpm

02/06/17 11:36:30

Made In OsiriX

Ecocrd. adultos

TIS0.3 MI 0.2 Free Form

X7-2t

53Hz

15cm

Z 1.7


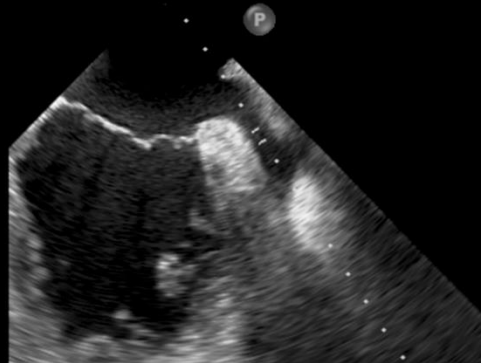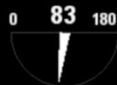
2D

61%

C 50

P Des.

Gral.



M4



PW

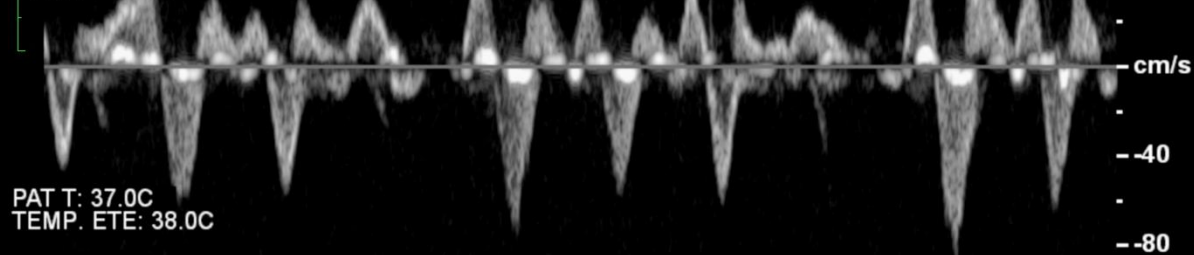
50%

FP 150Hz

VMue4.0mm

2.9MHz

5.1cm



PAT T: 37.0C
TEMP. ETE: 38.0C

Zoom: 3.20%
Im: 17/27 Series: 1
LittleEndianExplicit

NO USAR PARA DIAGNOSTICO MEDICO

75mm/s

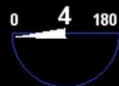52bpm

02/06/17 11:36:45
Made in OsiriX

Ecocrd. adultos

TIS0.5 MI 0.7

X7-2t
21Hz
7.1cm



2D
59%
C 50
P Des.
Gral.


FC
48%
6838Hz
FP 615Hz
4.4MHz



PAT T: 37.0C
TEMP. ETE: 38.7C

Dist 0.747 cm

NO USAR PARA DIAGNÓSTICO MÉDICO



50bpm
02/06/17 11:43:13
Made In OstrIX

Ecocrd. adultos

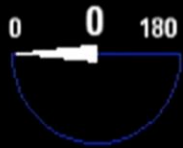TIS0.1 MI 0.3

X7-2t

Latidos 3D 1

7Hz

8.1cm



M4



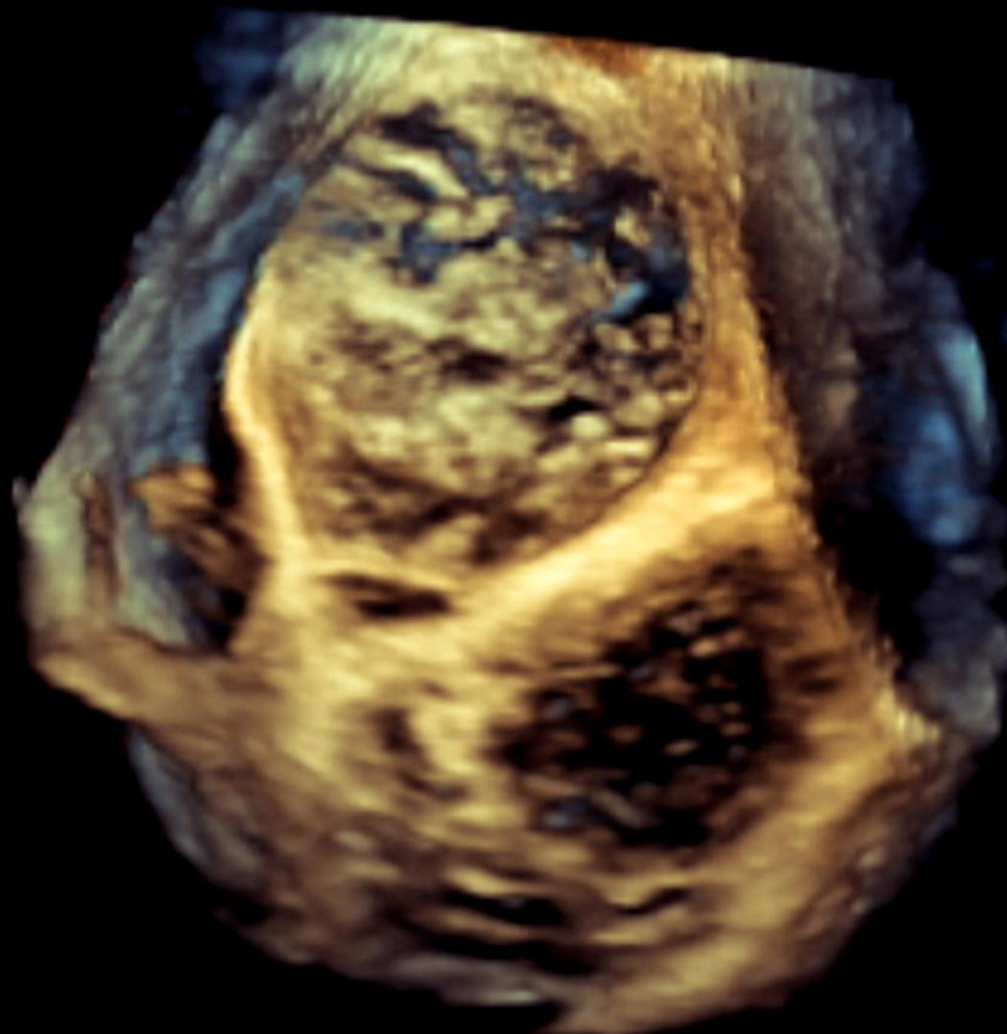Live 3D

2D / 3D

% 47 / 44

C 50 / 30

Gral.



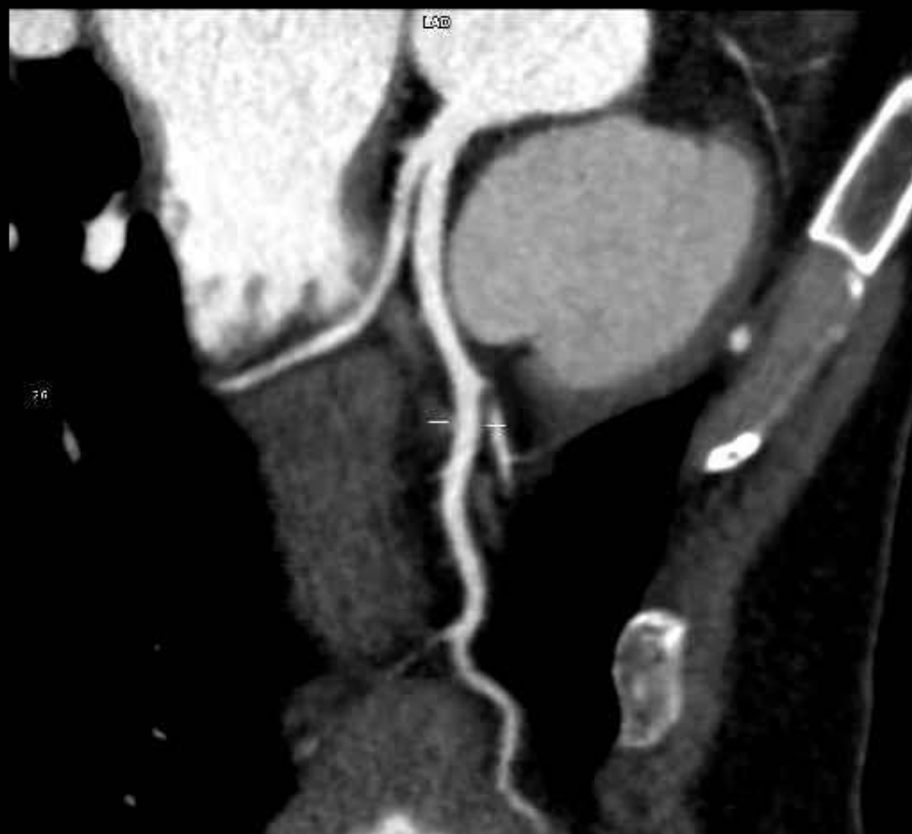
PAT T: 37.0C
TEMP. ETE: 40.1C

Zoom: 410%
Im: 1/22, Series: 1

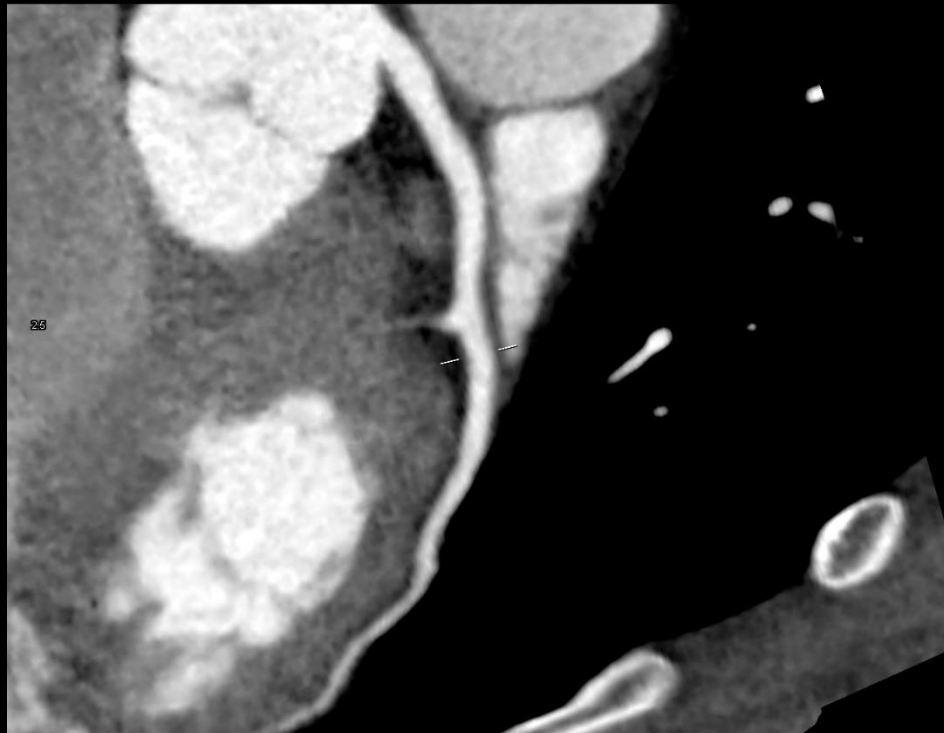
NO USAR PARA DIAGNÓSTICO MÉDICO

47 lpm
02/06/17 11:45:12

1 / 1



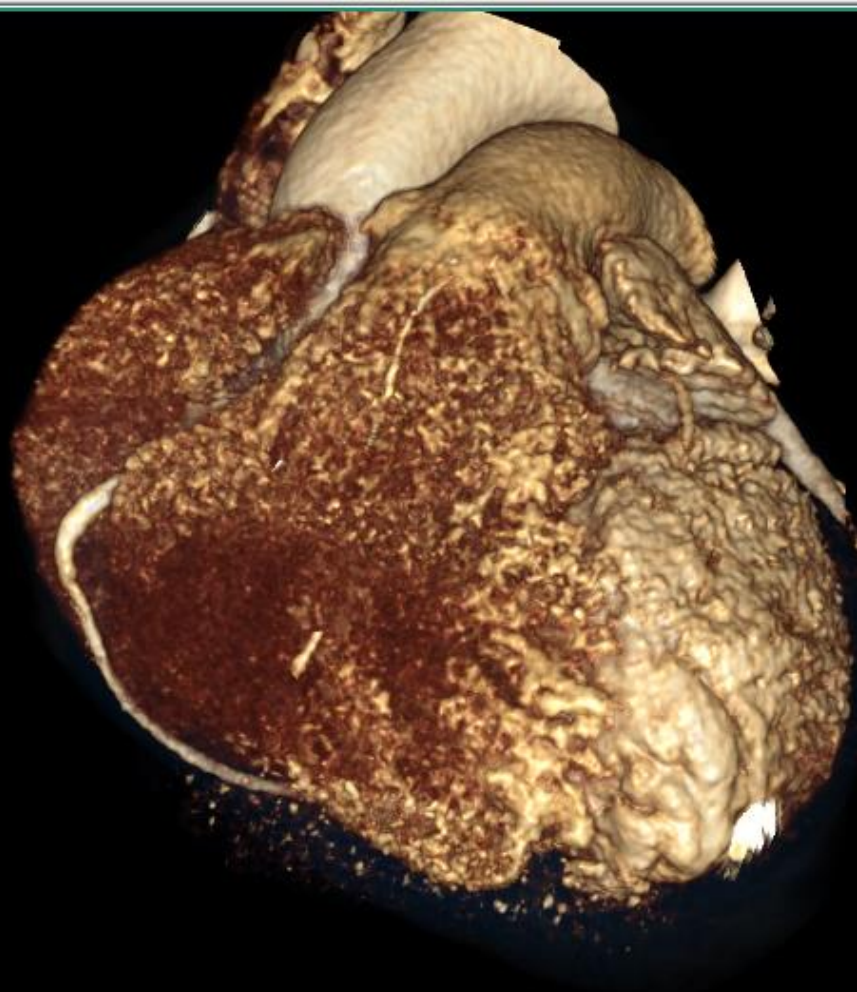
LAD



NO USAR PARA DIAGNÓSTICO MÉDICO

S12 Snapshot Func 10%
2017/06/03 16:50:54

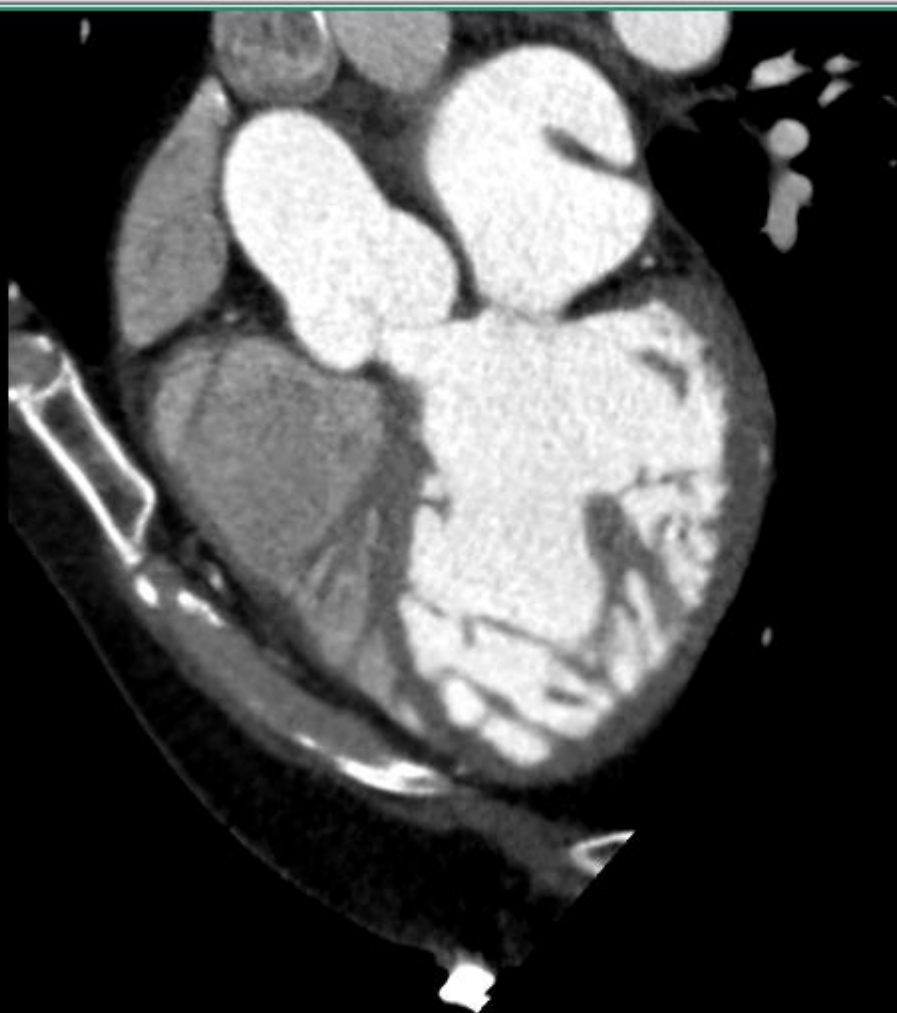THK:0



Z:0.59
C:128
W:256
IM:0 SE:1080

S6 Snapshot Func 90%
2017/06/03 16:50:55

THK:0



Z:0.59
C:128
W:256
IM:0 SE:1068

Management

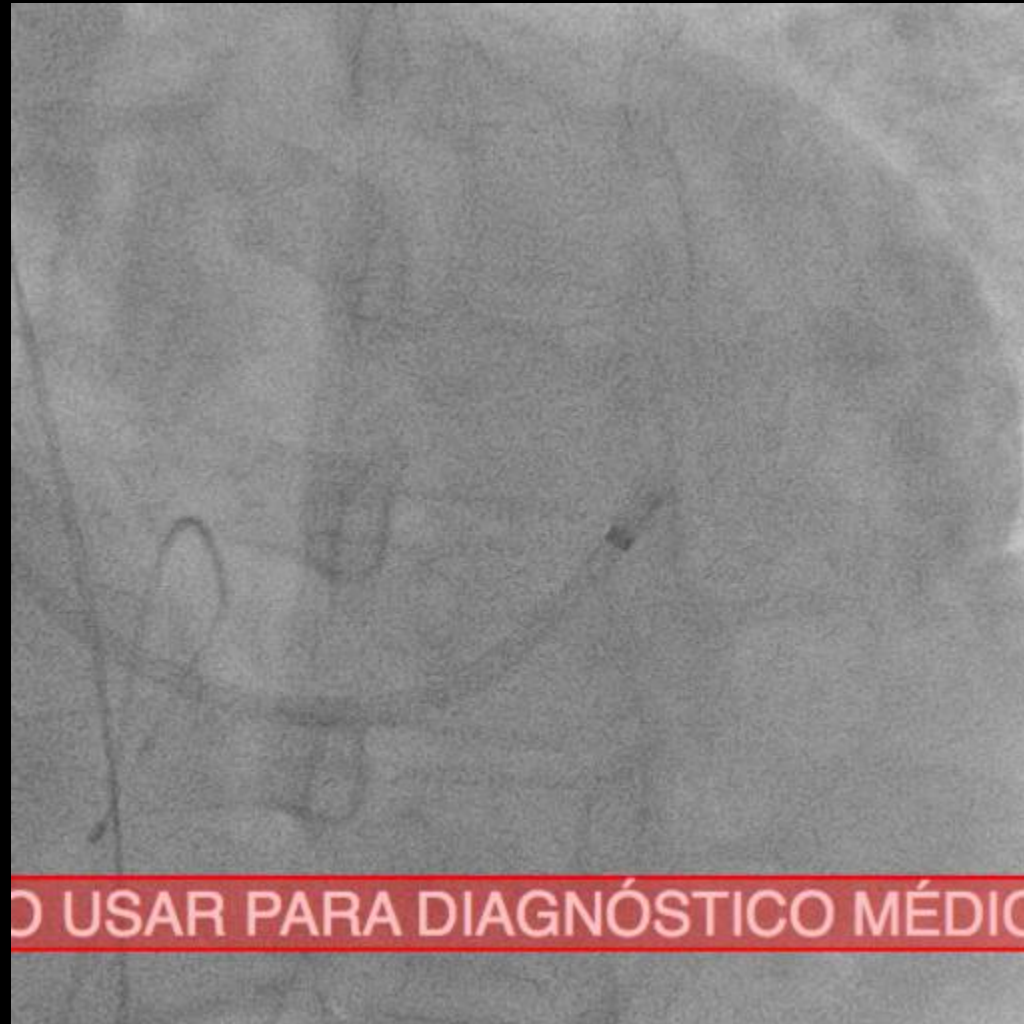
Meds

- Spironolactone 25 mg qd
- Rivaroxaban 20 mg bid
- Amiodarone 200 mg bid
- Ramipril 2.5 mg qd

Management

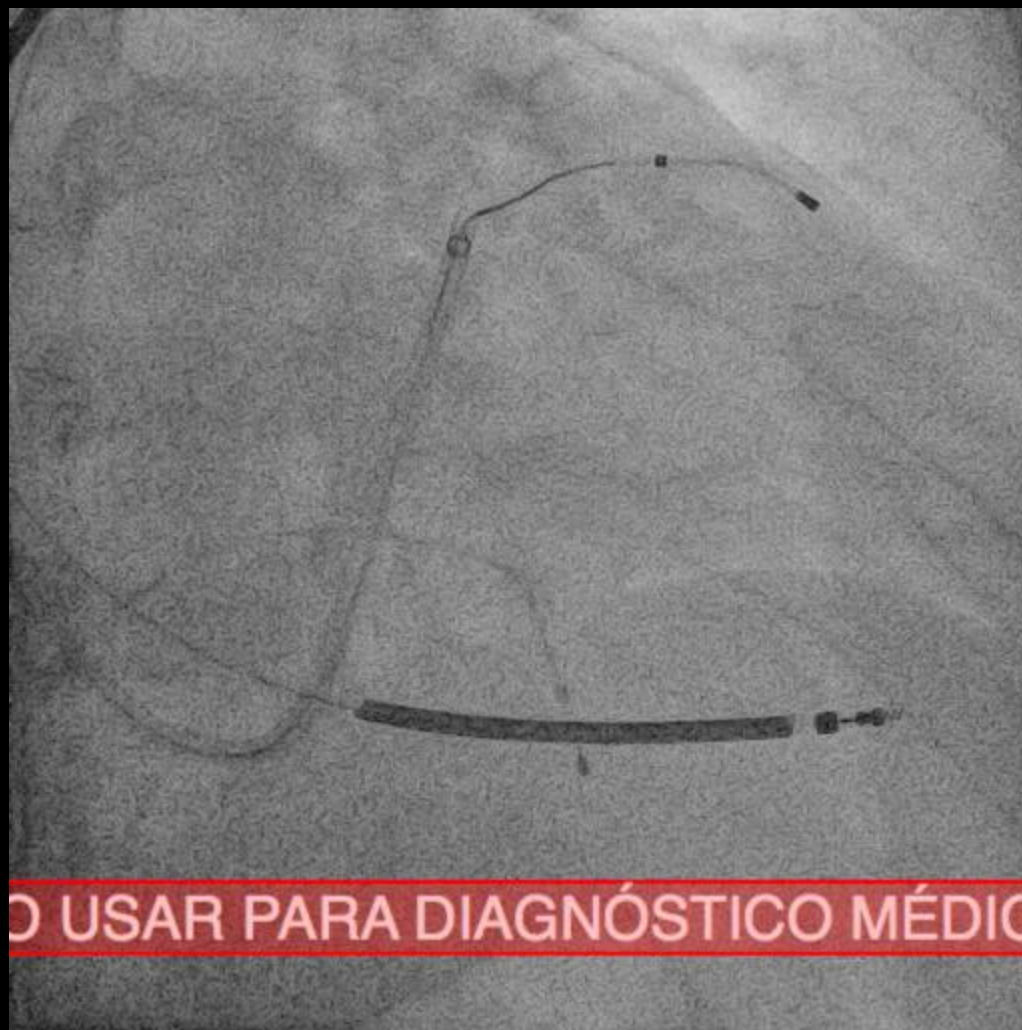
Procedure:

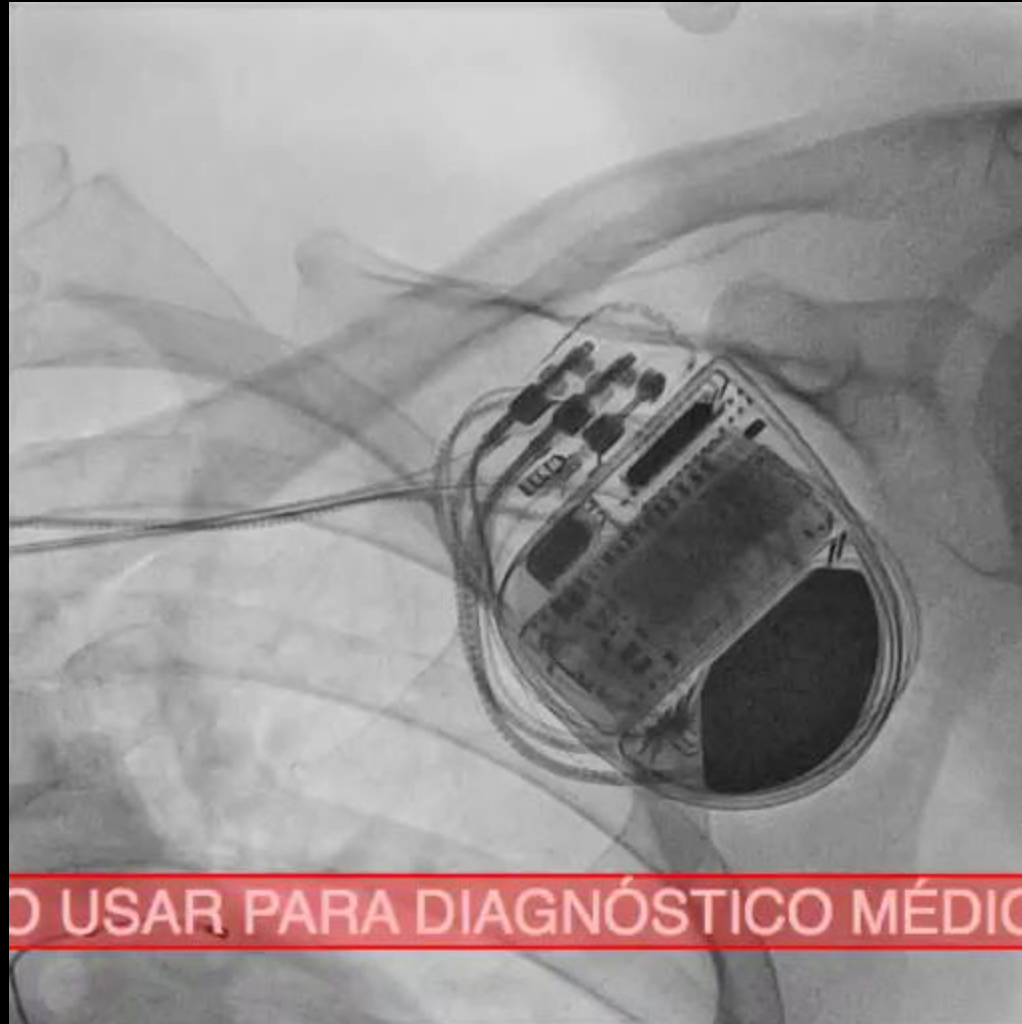
- Cardiac resynchronization therapy with implantable defibrillator
- VIVA XT CRT-D
- Parameters:
- With a defibrillation basal algorithm and echocardiographic resynchronization guidance.





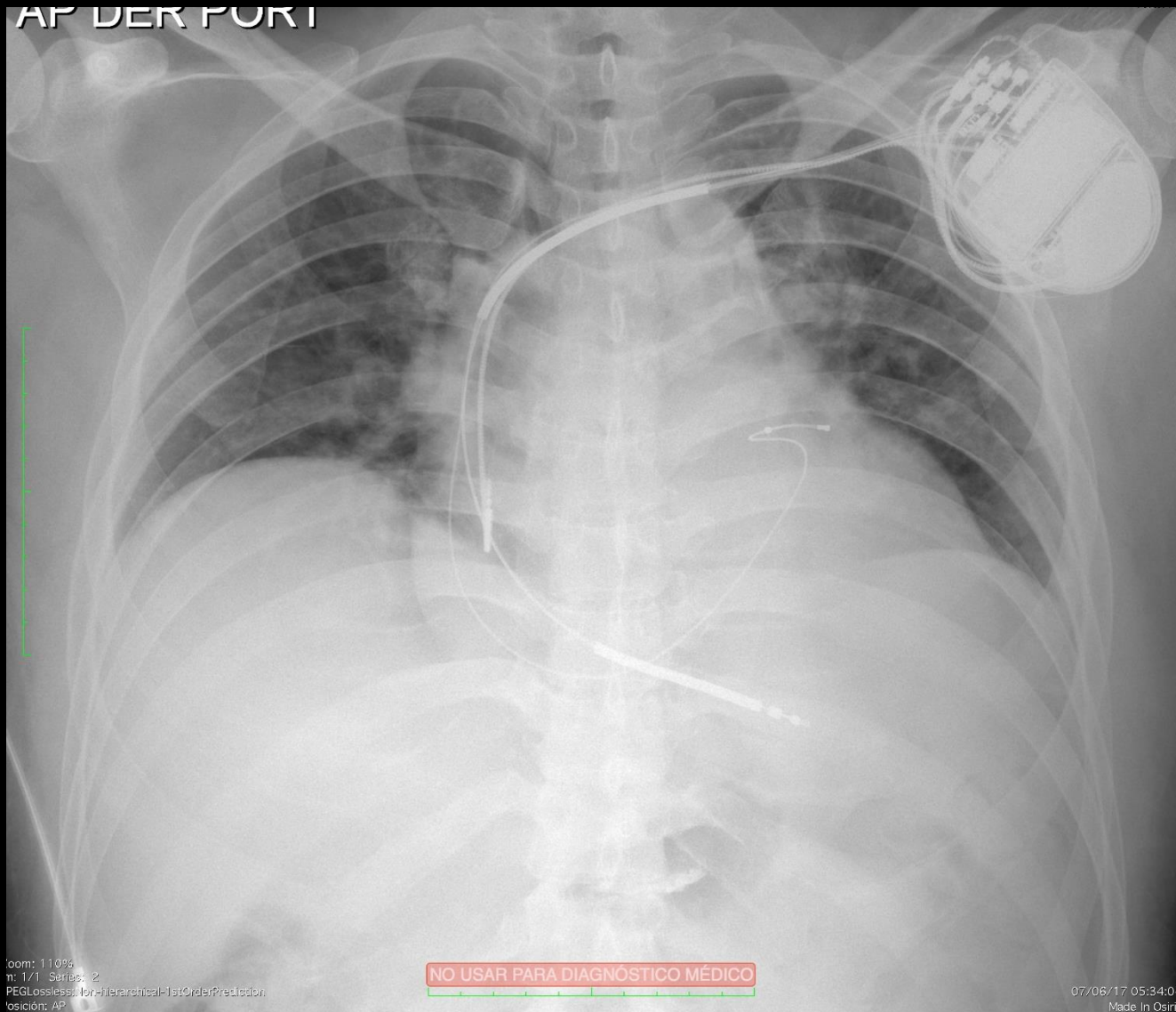
NO USAR PARA DIAGNÓSTICO MÉDICO





NO USAR PARA DIAGNÓSTICO MÉDICO

AP DER PORT



zoom: 110%
n: 1/1 Series: 2
PEGLossless: for Hierarchical-1stOrderPrediction
posición: AP

NO USAR PARA DIAGNÓSTICO MÉDICO

07/06/17 05:34:04
Made In OsiriX



ACC Latin America
Conference 2017



MEXICO CITY
JUNE 22 – 24, 2017

GLOBAL EXPERTS, LOCAL LEARNING