

THE GENETICS AND PRESENTATION OF AORTOPATHIES

Rima S Bader MD ,PhD, FASE, FRCPCH, FACC

Prof of Pediatric and Perinatal Cardiology

King Abdul Aziz University , College of Medicine, Jeddah Saudi Arabia



DISCLOSURES

I have no financial disclosures.

DEFINITION

Adults with congenital heart disease (CHD) generally fall into two categories:

1. Patients who have **been recognized**, treated, and followed during their pediatric years and subsequently require follow-up during their adult years
2. **De novo**, previously unrecognized adults who may or may not be symptomatic at the time of diagnosis.

PREVALENCE AND RISK FACTORS

- CHD in the adult is now more prevalent than ever because of the rapid advances in surgical and medical interventions in the pediatric population.
- As a result, there are now an estimated 750,000 adults with CHD in the United States, and this figure excludes patients with bicuspid aortic valves, which are present in up to 2% of the population, and mitral valve prolapse.

PREVALENCE AND RISK FACTORS

- ❑ Most congenital heart disease, however, appears to be caused by genetic abnormalities
- ❑ Few of which have been well described, but many remain to be elucidated.
- ❑ Evidence to support the importance of genetics in CHD includes the much higher risk in the offspring of CHD patients than the 0.8% general population risk;
 - ❑ Animal models such as transgenic knockout mice that develop cardiac abnormalities;
 - ❑ Well-described familial kindreds with lesions such as atrial septal defects;
 - ❑ Mendelian patterns of inheritance
 - ❑ The common clinical syndromes such as trisomy 21 (Down syndrome), in which atrioventricular canal–type (primum) septal defects are commonly present,
 - ❑ Noonan's syndrome, in which pulmonic stenosis is often present.
- ❑ In general, routine screening of adults for genetic mutations is not currently advocated for most adults with CHD, even for family planning.

PATHOPHYSIOLOGY

- ❑ The clinical course of CHD in the adult is most dependent on the anatomic lesions present and the timing and manner of repair.
- ❑ These lesions can be divided into three general categories (by decreasing incidence):
 - simple shunt lesions
 - obstructive lesions
 - complex lesions (acyanotic and cyanotic).

GENETIC AORTOPATHIES

GENETIC AORTOPATHIES

1. Autosomal dominant vascular

- Marfan Syndrome
- Ehlers-Danlos
- Loeys-Dietz: is It has features similar to Marfan syndrome and Ehlers–Danlos syndrome

2. Aneurysms-osteoarthritis syndromes

3. The chromosomal defect Turner syndrome

4. Non-syndromic familial thoracic aortic aneurysms and dissection.

MARFAN SYNDROME



- ❑ Antoine Bernard-Jean Marfan (June 23, 1858 – February 11, 1942), a French pediatrician
- ❑ In 1896, Marfan described a hereditary disorder of connective tissue in a 5 yr old girl with disproportionately long limbs that later became to be known as Marfan syndrome

MARFAN SYNDROME

- ❑ One of the most common inherited disorders of connective tissue ?
- ❑ Incidence: 1 in 3000-5000 individuals
- ❑ Prevalence is thought to be similar ? Regardless of sex
- ❑ Regardless of ethnicity

Marfan syndrome-diagnosis and management. Curr Probl Cardiol. Jan 2008;33(1):7-39.

GENETICS

- ❑ Caused by a **variety of** mutations in the FBN1 gene.
- ❑ FBN1 mutations have been identified in over 90 percent patients
- ❑ In 75% of patients - **autosomal dominant**, although the appearance of family members and degree of pathological **features may vary**.
- ❑ In **25% of patients - mutation** occurs spontaneously and may be associated with older paternal age.
- ❑ The **first fibrillin-1 gene mutation was identified in 1990**.
Subsequently, over 1000 different mutations have been identified.

GENETICS

- ❑ About 10 percent of individuals with suspected MFS have no defined FBN1 mutation.
- ❑ Some of these individuals may have TGFBR1 or TGFBR2 mutations.
- ❑ TGFBR1/TGFBR2 mutations more typically cause LoeysDietz syndrome (LDS), with rare reports in association with familial thoracic aortic aneurysm (FTAA) syndrome.
- ❑ Some patients with FBN1 gene mutations do not have MFS and instead have a related disorder such as ectopia lentis syndrome or other diseases such as ShprintzenGoldberg syndrome, WeillMarchesani syndrome, or stiff skin syndrome.

PATHOPHYSIOLOGY

- ❑ Mutations in the fibrillin-1 gene result in the production of an abnormal fibrillin protein, leading to abnormalities in the mechanical stability and elastic properties of connective tissue.
- ❑ More recently, research suggests that transforming growth factor-beta is implicated in the failure of normal elastic tissue formation.
- ❑ TGFBR 1 and 2 mutations – may have similar manifestations
- ❑ Cystic medial necrosis - cysts being fluid collections of mucin and ground substance - lead to a weakening of the aortic wall with subsequent aortic dilation and potentially aortic dissection, aneurysms, and rupture.
- ❑ They also lead to a reduction of the structural integrity of the skin, ligaments, eye lenses, lung airways, and the spinal dura.

MFS RELATED DISORDERS

1- Ectopia lentis syndrome

- ☐ Dislocated lenses with or without systemic features AND
- ☐ with an FBN1 not associated with Ao
- ☐ or no FBN1

RELATED DISORDERS

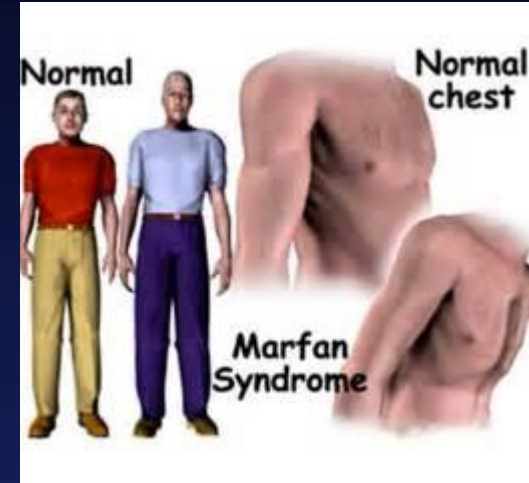2 **MASS** (myopia, MVP, borderline aortic root dilation, striae, skeletal findings)

Ao ($Z < 2$); AND systemic features ≥ 5 (with at least one skeletal feature) without ectopia lentis

- 3 **Mitral valve prolapse syndrome**

MVP; AND \square Ao ($Z < 2$); AND systemic features < 5 without ectopia lentis

1- MARFAN SYNDROME



REQUIREMENT FOR DIAGNOSIS

Index Case

If Characteristic Mutation known/AD inheritance apparent Major criteria in 1 system

+

2nd system 'involved'

If family/genetic history not significant Major criteria in 2 systems

+

3rd system 'involved'

CLUES TO DIAGNOSIS MFS

Relative of Index case

Family history Major criteria present

+

Major criteria in 1 system

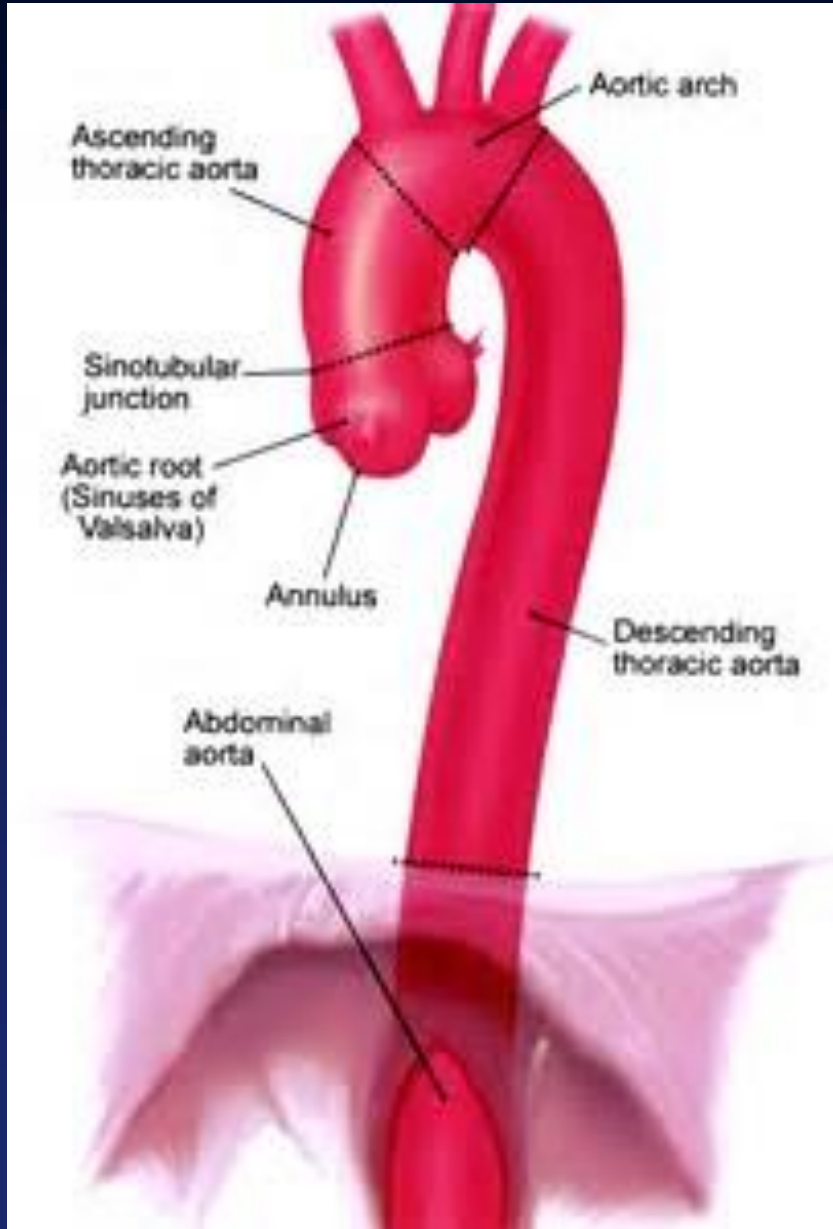
+

2nd system 'involved'

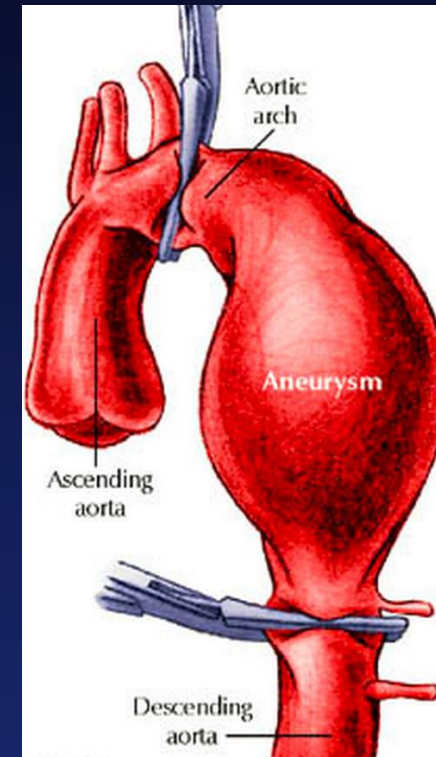
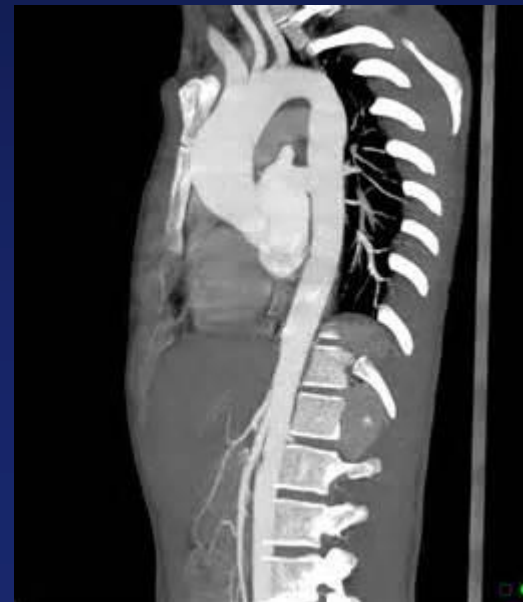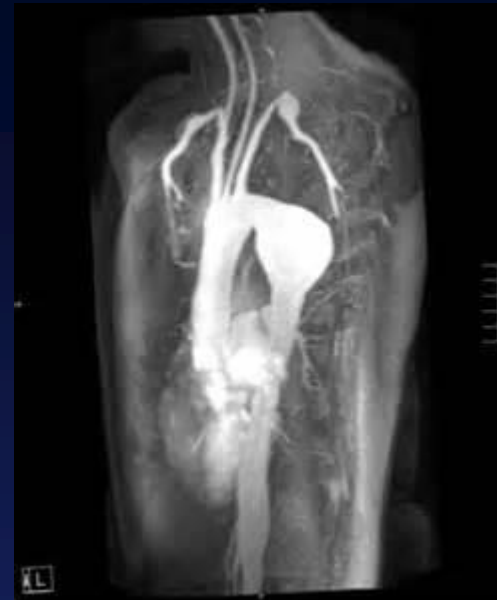AORTIC DISEASE

- ❑ Aortic root disease, leading to aneurysmal dilatation, aortic regurgitation, and dissection - main cause of morbidity and mortality
- ❑ Poor correlation between the severity of the cardiovascular and the ocular or skeletal manifestations
- ❑ Although dilated, the aorta in MFS tends to be stiffer and less distensible
 - ❑ ? Dilatation of the aorta, often (about 25%) accompanied by aortic regurgitation, progresses with time
 - ❑ 50 percent of young children with MFS
 - ❑ 60 to 80 percent of adult patients with MFS

Normal Aortic Arch



Aorta in Marfan syndrome



AORTIC DISEASE

- ❑ Dilatation may also involve other segments of the thoracic aorta, the abdominal aorta, the root of the pulmonary artery or even the carotid and intracranial arteries, although much less frequent than in LDS.
- ❑ The normal range for aortic diameter varies with body size and age - nomograms and Z-scores used to identify aortic dilatation.
- ❑ Undiagnosed and untreated MFS - frequently associated with aortic dissection. May have a family history of dissection.
- ❑ The frequency with which MFS is responsible for aortic dissection varies with age.
 - ❑ 50% of those under age 40
 - ❑ 2 % of those with age 40 - 70
 - ❑ no patient over age 70

CARDIAC

P4-2 3.2T

FPS 53s

LV

AO

LA

150

AO

4Sec

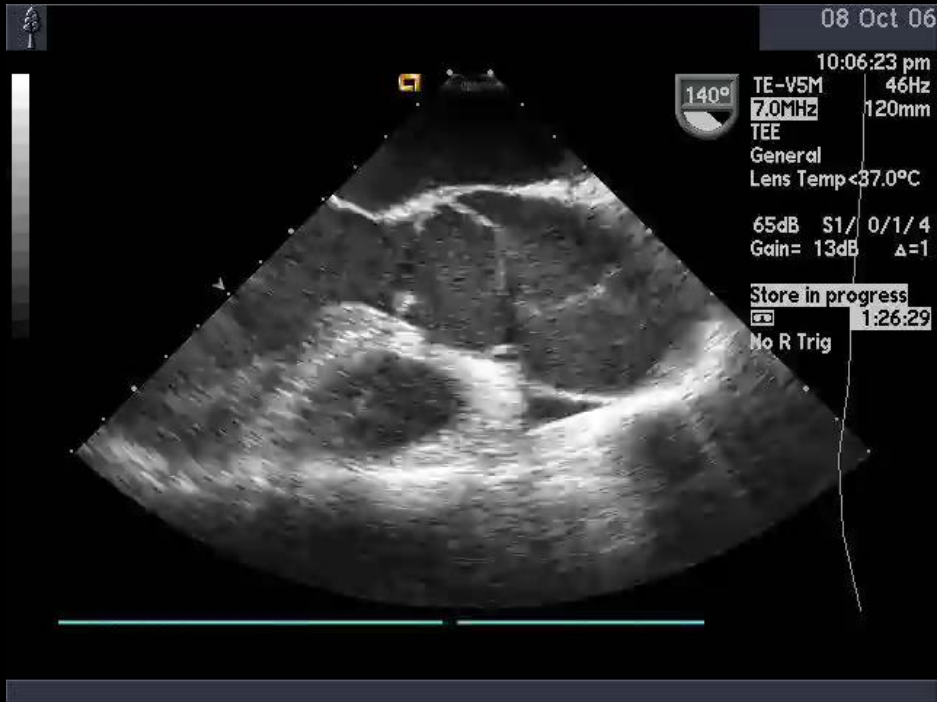
2D 60/1/24

M 50/1/23

MI 0.8 TIS 0.3 TIB 0.8 Tx 100%



AORTIC ROOT DILATION AND DISSECTION



Morphological and 4D functional MRI showing Dissection
of the descending thoracic aorta
with areas of false lumen

Source :

Management of acute aortic dissection

Nienaber CA, Clough RE.

Lancet. 2015 Feb 28;385(9970):800-11. doi: 10.1016/S0140-6736(14)61005-9

CARDIAC DISEASE

- ❑ Mitral valve prolapse (MVP)

- ❑ Common but nonspecific – only 1 point in systemic scoring 40-54% MFS adults;

- ❑ upto 90% in some series frequency of MVP increases with age; greater in women.

- ❑ Tricuspid valve prolapse may also occur.

CARDIAC DISEASE

- ❑ Approximately 25 percent of patients with MVP have progressive disease - defined by the appearance or worsening of clinical symptoms of mitral regurgitation or worsening on echocardiography
- ❑ Heart failure attributable to mitral valve prolapse and regurgitation represents a major source of morbidity and mortality in young children with the most extreme and rapidly progressive presentation of MFS.
- ❑ Some report suggest - some patients may have a cardiomyopathy with biventricular enlargement and generally asymptomatic mild systolic dysfunction unrelated to valvular disease

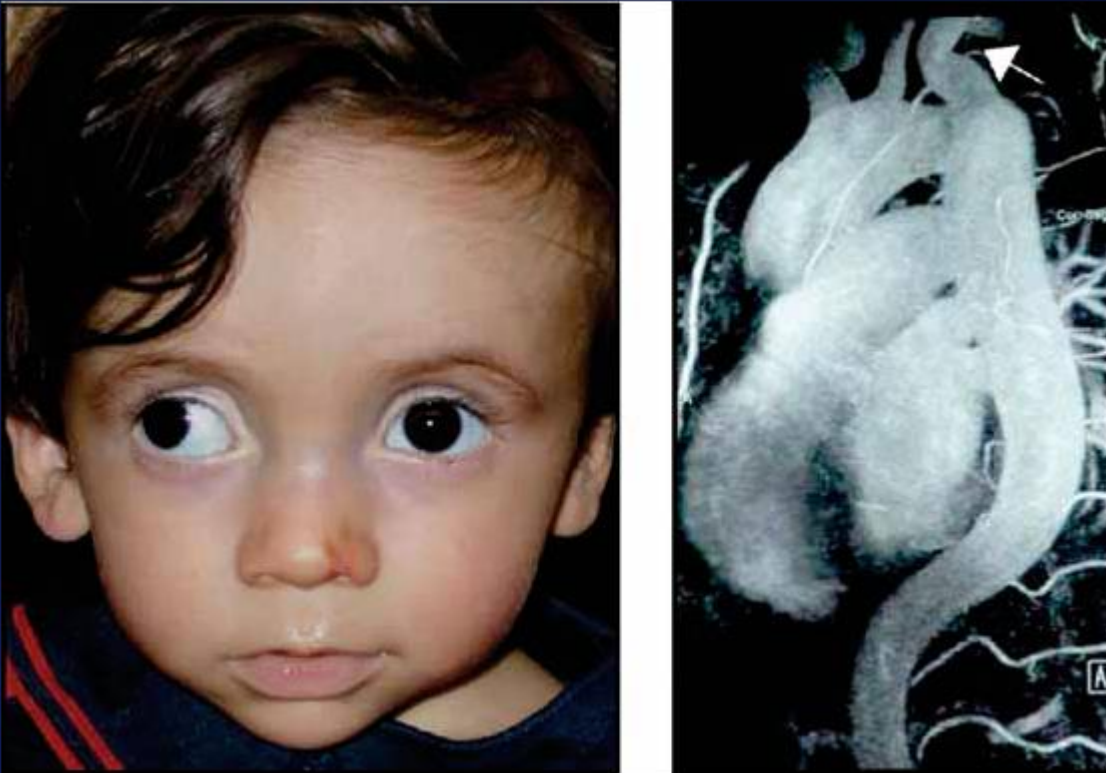NATURAL HISTORY MFS

- Aortic root growth rate is greater than normal, averaging 0.4–0.5 mm/year.
- A subset of patients shows faster growth (~1.5 mm/year), associated with greater dissection risk.
- Risk for dissection or death increases steeply at proximal aortic diameters ≥ 50 mm (1.33%/year vs 0.33%/year with diameters 45–49 mm).
- Other risk factors for dissection
 - include family history of dissection
 - pregnancy
 - After aortic root surgery, the aorta distal to the repair site remains at risk for dilatation and dissection

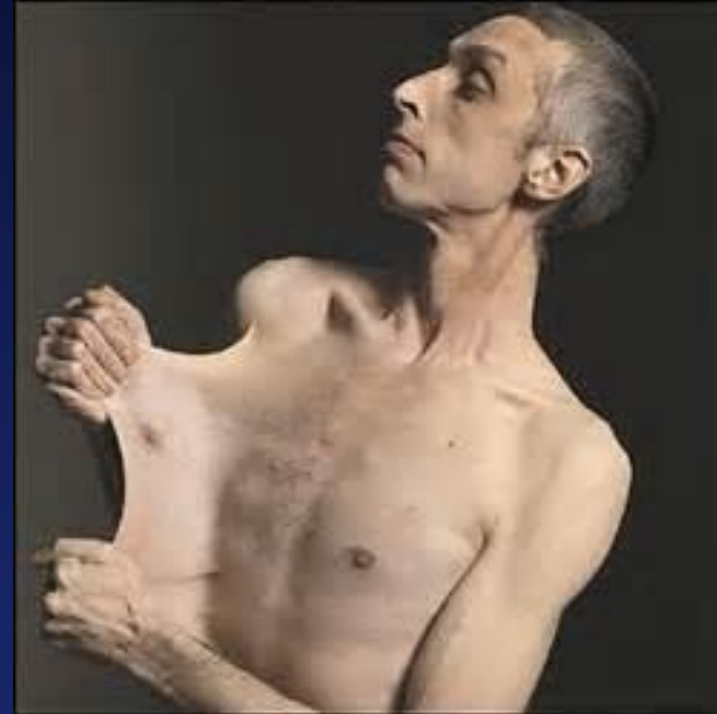OTHER GENETIC AORTOPATHIES

1. **Autosomal dominant vascular**
 - Marfan Syndrome
 - Ehlers-Danlos
 - Loeys-Dietz: i It has features similar to Marfan syndrome and Ehlers—Danlos syndrome
2. **Aneurysms-osteoarthritis syndromes**
3. **The chromosomal defect Turner syndrome**
4. **Non-syndromic familial thoracic aortic aneurysms and dissection.**

LOEYS-DIETZ



Ehlers-Danlos



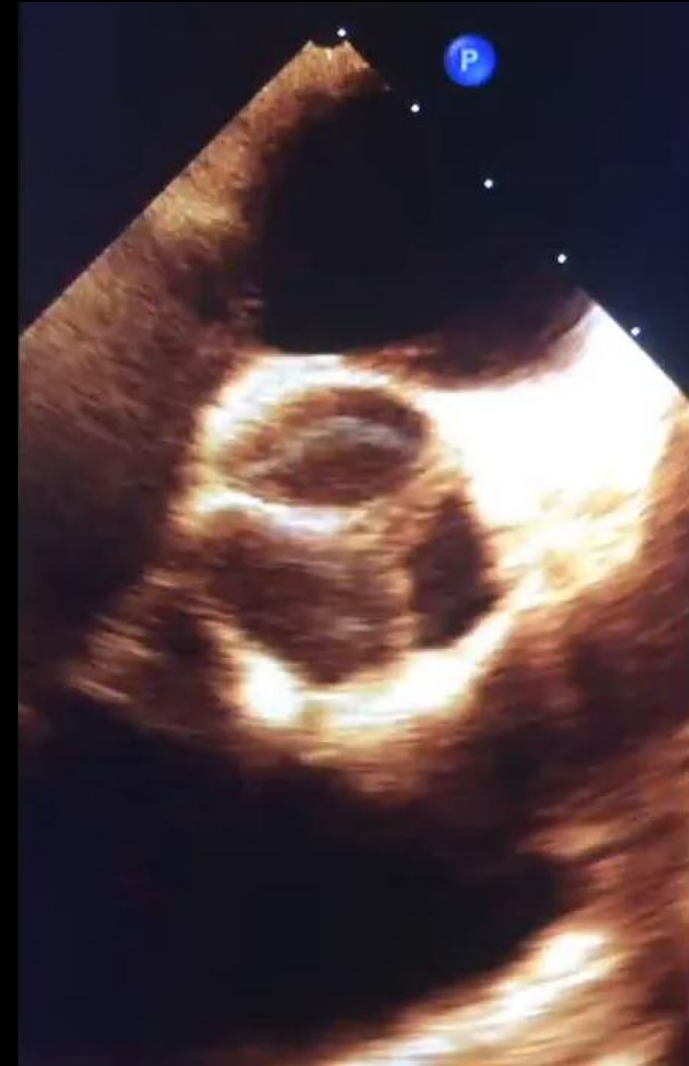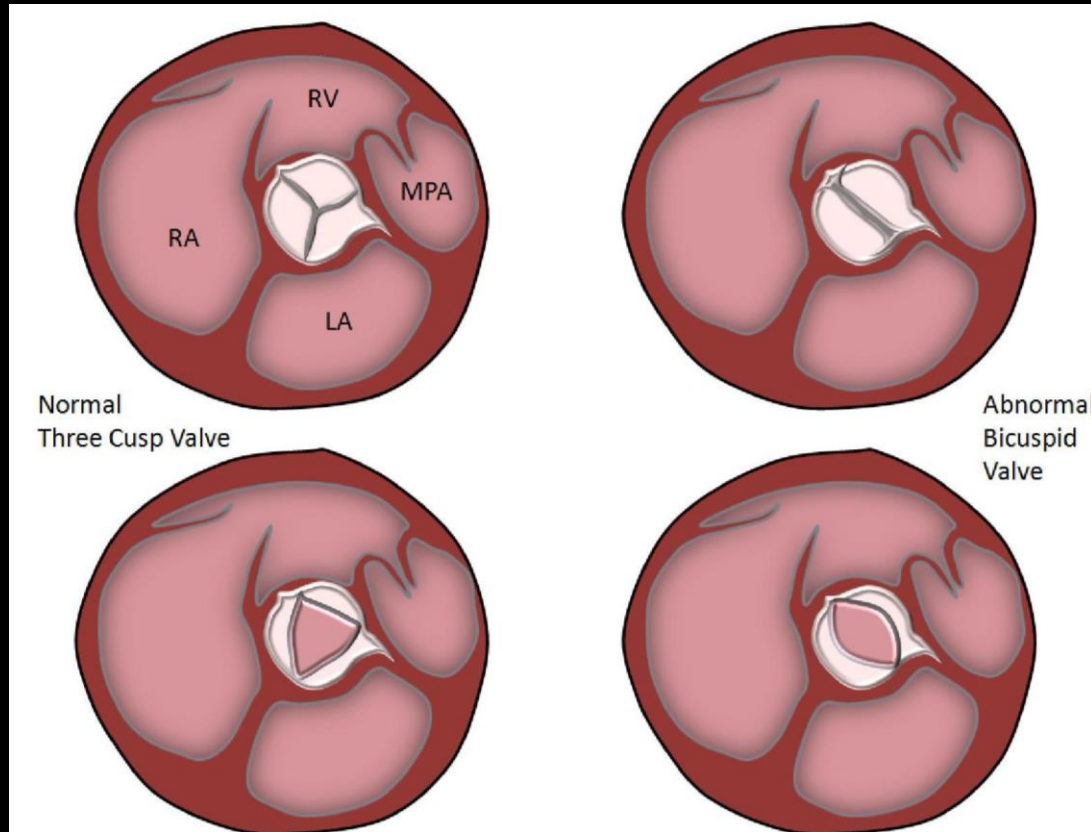
CONGENITAL HEART DISEASE -ASSOCIATED AORTOPATHY

1- BICUSPID AORTIC VALVE

- ❑ Bicuspid aortic valve (BAV), affecting 0.5%–2% of the population with a male predominance of ~3:1
- ❑ results from fusion of the right and left coronary cusps (>70%)
- ❑ right and non-coronary cusps (10%–20%)
- ❑ left and non-coronary cusps (5%–10%) of the aortic valve.
- ❑ Aortic coarctation (CoA) is present in ~7%, in association with right left fusion phenotype.

- ❑ General mode of inheritance is autosomal dominant with incomplete penetrance.
- ❑ However, the male predominance and association with Turner syndrome suggest X-linked inheritance
- ❑ several gene mutations with differing modes of inheritance may underlay BAV.
- ❑ While valve stenosis and insufficiency are the predominant complications, proximal aortic dilatation is found in 50%–87% of adult patients.
- ❑ Dilatation is generally greatest at the ascending aorta and often also involves the root and/or arch
- ❑ BAV-associated aortic dilatation probably results from an interplay between altered transvalvular haemodynamics and an intrinsic aortopathy.

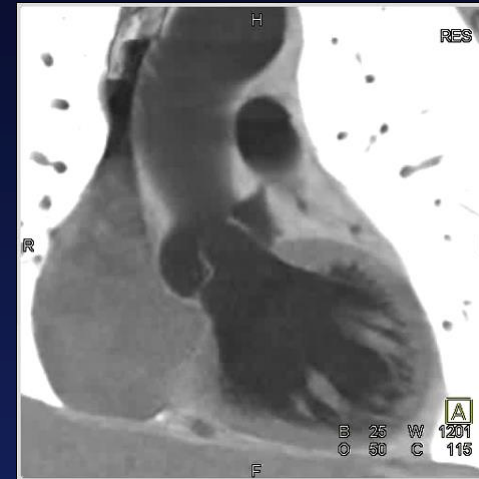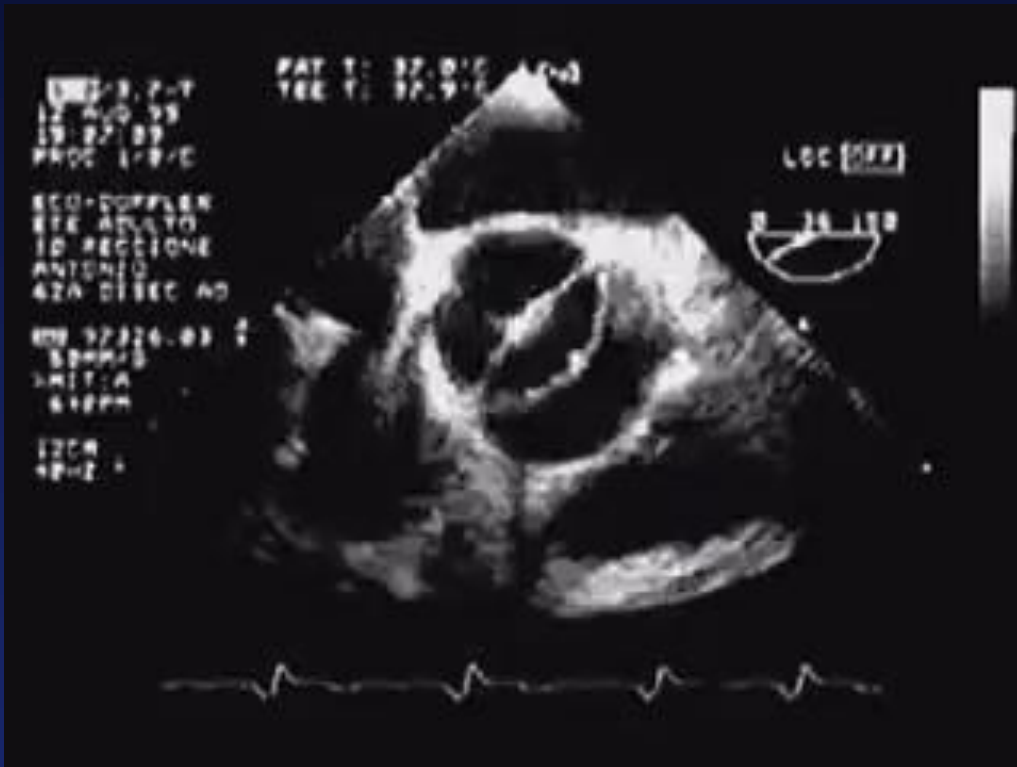1- Bicuspid aortic valve




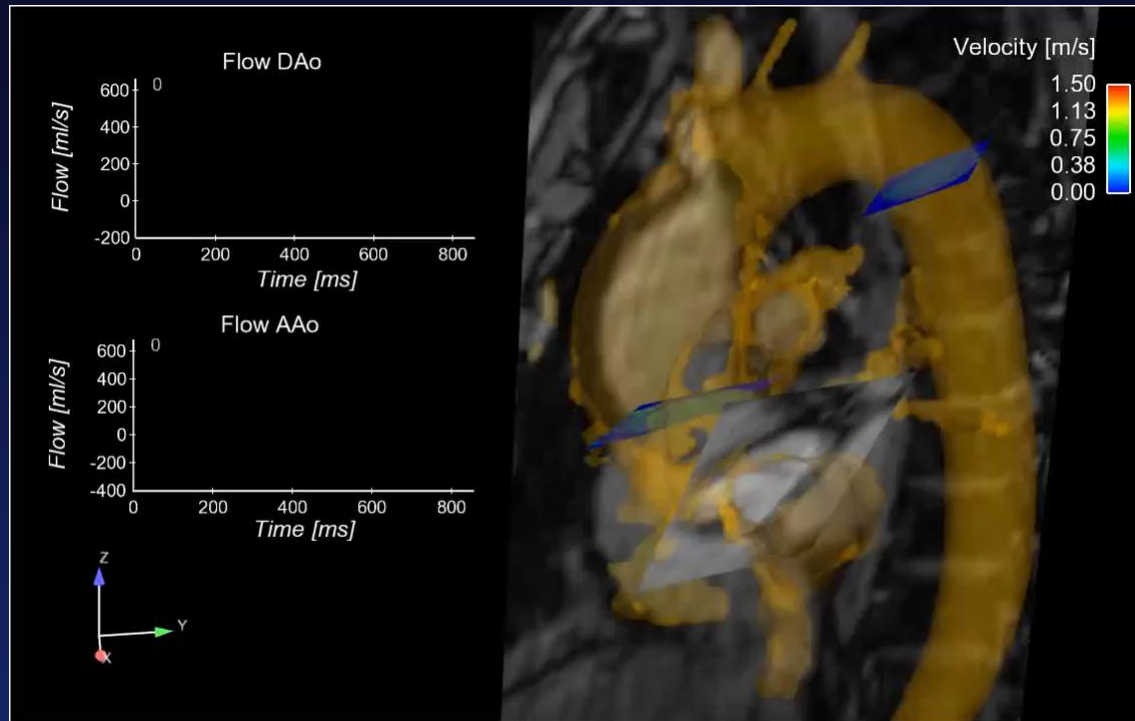
NATURAL HISTORY OF BICUSPID AORTIC VALVE

- Ascending aortic growth rates range from 0.3 to 2.0 mm/year,
- while ~40% of patients show stable diameters over several years, emphasising heterogeneity within the BAV population.
- Factors associated with increased growth, including greater baseline diameter, valvular dysfunction and aortic stiffness, are inconsistently found, complicating risk stratification.
- Dissection incidence is 3.1 cases per 10 000 person-years, 8.4 times the risk in the age-matched population.
- Dissections occur at similar diameters as in degenerative aneurysms (ie, those related to atherosclerotic risk factors).

BICUSPID AORTIC VALVE



MRI OF DILATED AORTIC ROOT AND SINUS OF VALSALVA IN PATIENT WITH BICUSPID AORTIC VALVE



4D MRI OF BICUSPID VALVE

**AORTIC FLOW 4D MRI IN A PATIENT
WITH BICUSPID AORTIC VALVE**

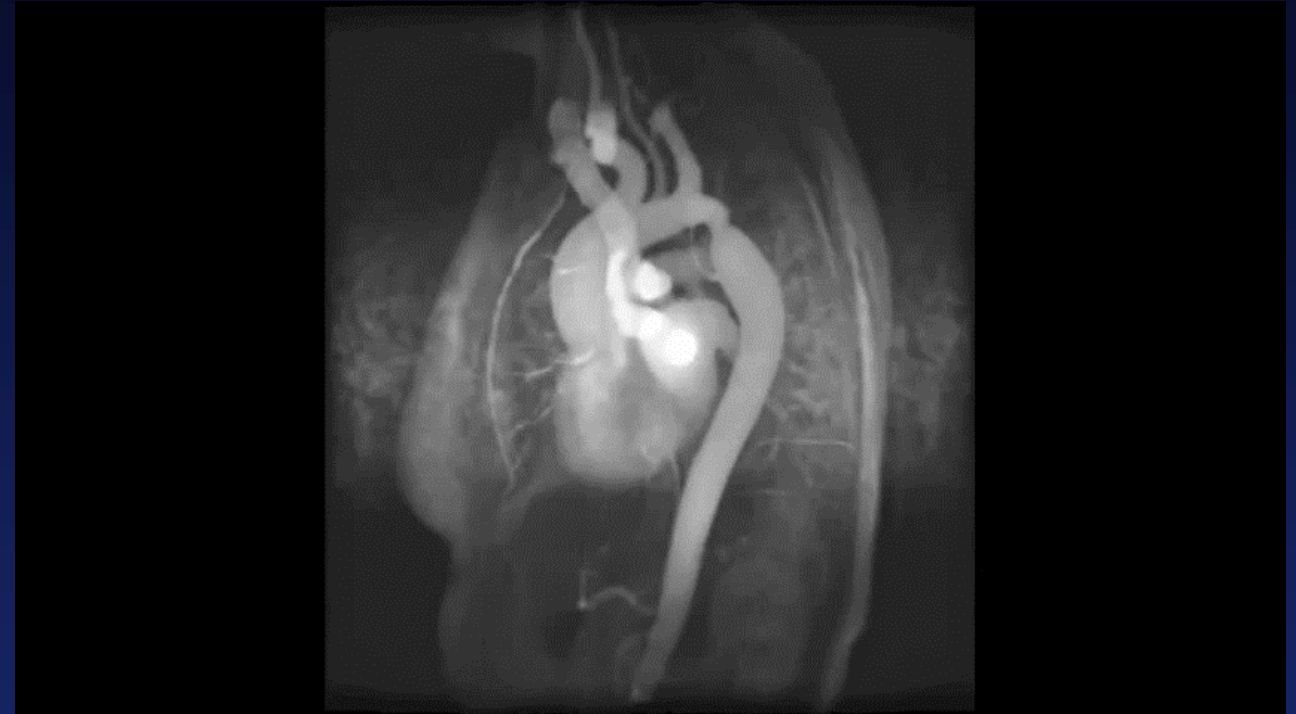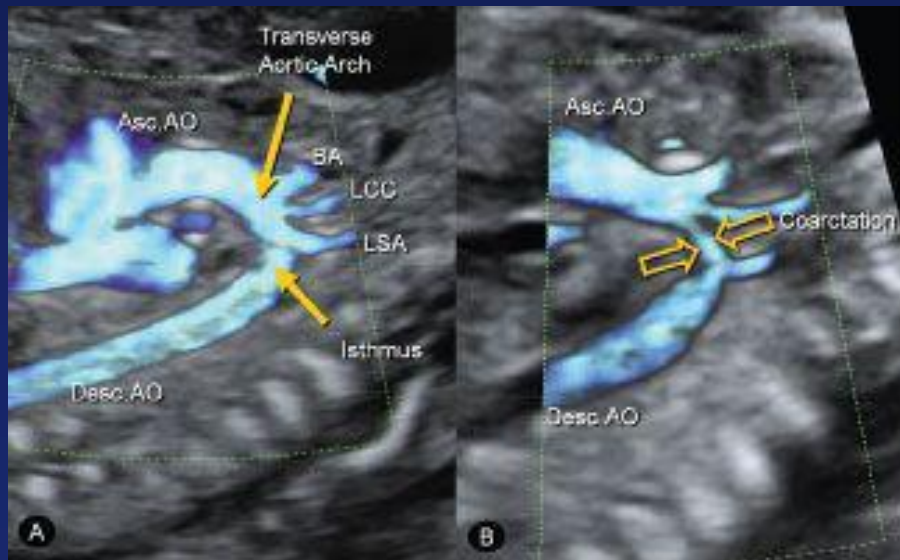
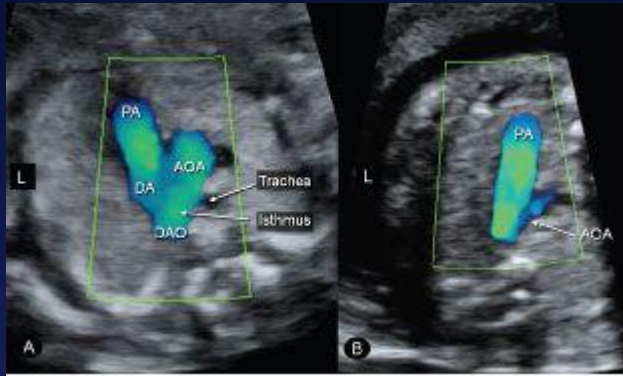
2-AORTIC COARCTATION

- ❑ CoA accounts for 5%–8% of all CHD
- ❑ Presence of BAV in ~60% and similar aortic wall abnormalities between these anomalies suggests they represent separate manifestations of an inherited aortopathy.
- ❑ CoA is a generalised arteriopathy with impaired elasticity and functionality of the precoarctation vasculature that persists after—even early—repair
- ❑ Associated risk of late morbidity, including aortic dilatation, dissection and rupture, necessitates continued follow-up after repair.
- ❑ The CoA site itself remains an area of concern, with chance of re-CoA, dilatation and rupture,

2-AORTIC COARCTATION

- In retrospective series of adults after surgical CoA repair
 - aneurysm formation was found in ~14%,
 - dissection or rupture in ~2.5%.
 - Postcoarctectomy ascending aortic growth rate is greater in 'complex' CoA (ie, associated with BAV, ventricular septal defect (VSD), hypoplastic aortic arch or increased left ventricular mass), compared with isolated CoA.
- A recent study found that
 - advancing age
 - concomitant BAV independently predicted aortic complications,
- while
 - age at repair,
 - repair type,
 - residual or re-CoA and hypertension did not.

COARCATATION CAN START IN FETAL LIFE OR POST NATAL

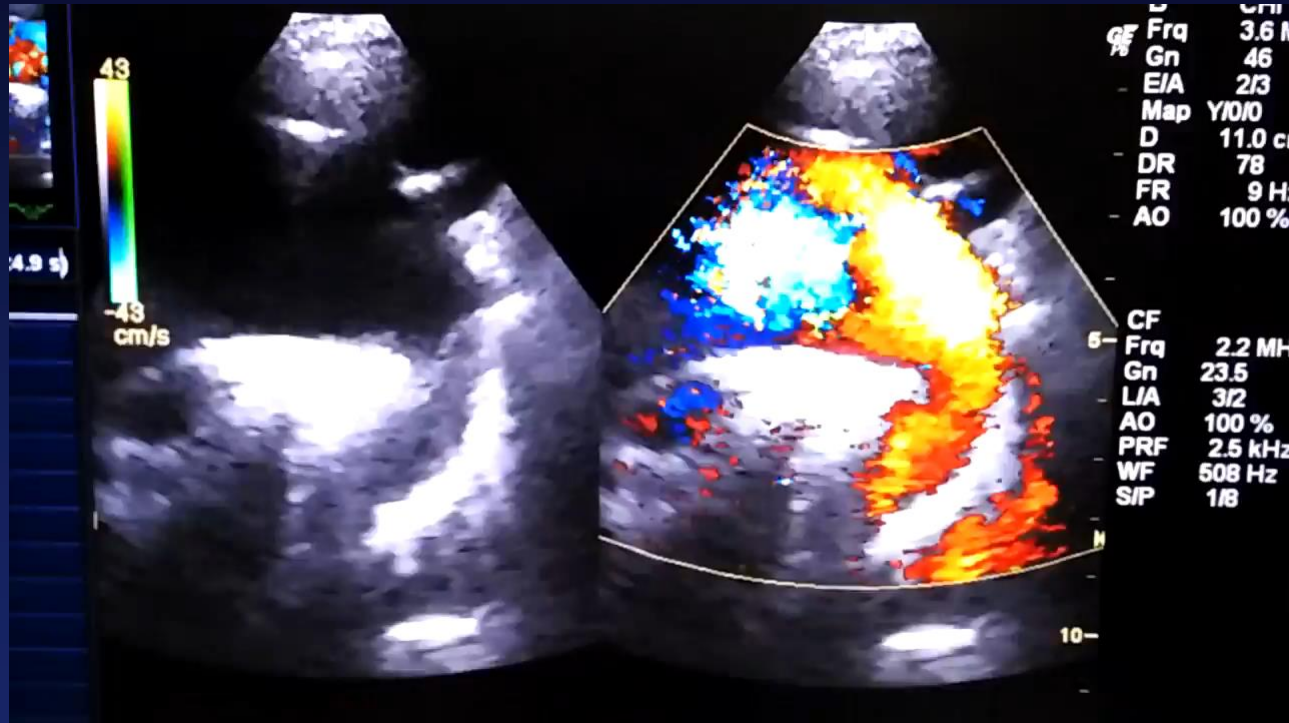


BLOOD FLOW MODELLING IN AORTIC COARCATATION

3- CONOTRUNCAL DEFECTS

- tetralogy of Fallot (ToF)
 - pulmonary atresia with VSD (PA+VSD),
 - double outlet right ventricle, , DORV
 - truncus arteriosus and transposition of the great arteries (TGA)
-
- All are characterised by abnormalities of the ventricular outflow tracts and great vessels

AORTIC ROOT DILATION IN TOF



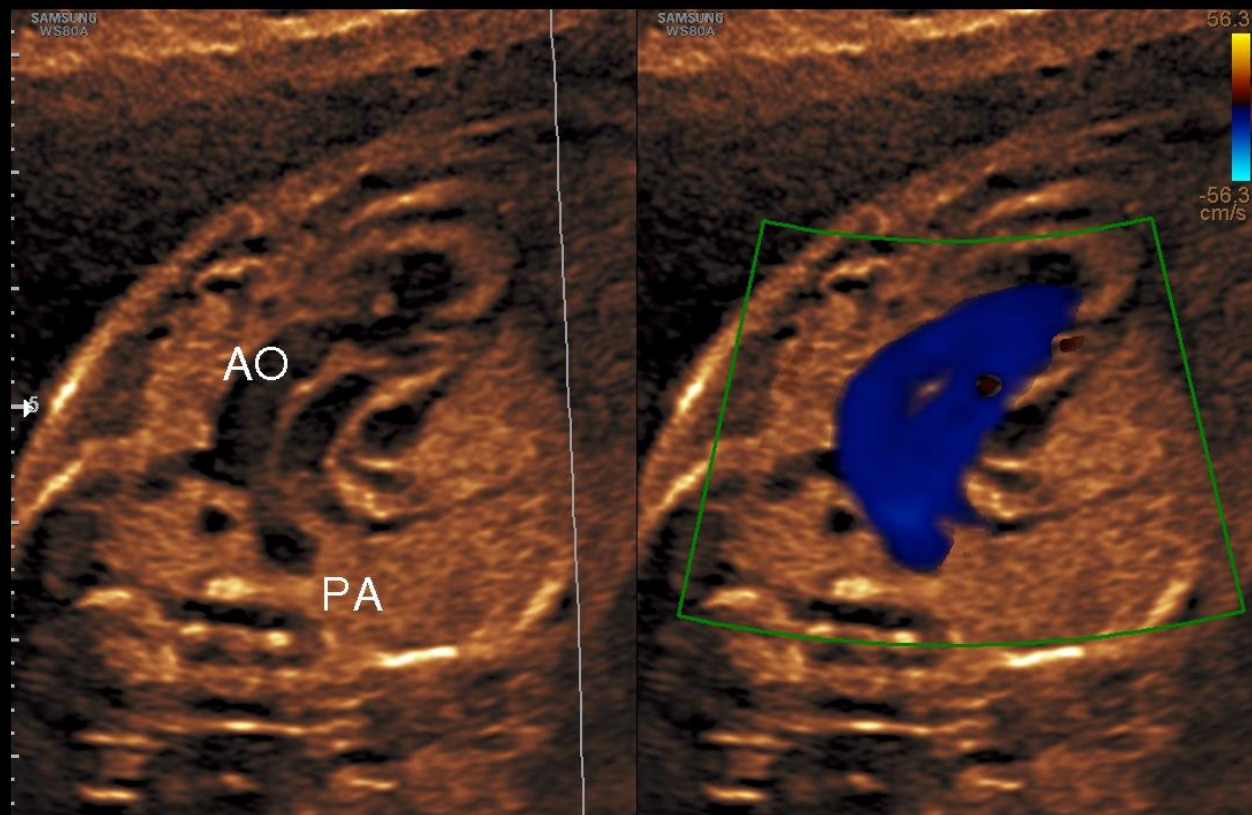
TGA STARTS ON FETAL LIFE

V4-8/OB/FPS17D1/11.0cm/M1.2/Tlb0.5/2015-05-24 04:54:48 PM

2D G53/DR108/FA7/P90/Frq Res./11.0cm



C G50/4.50kHz/F1/FA5

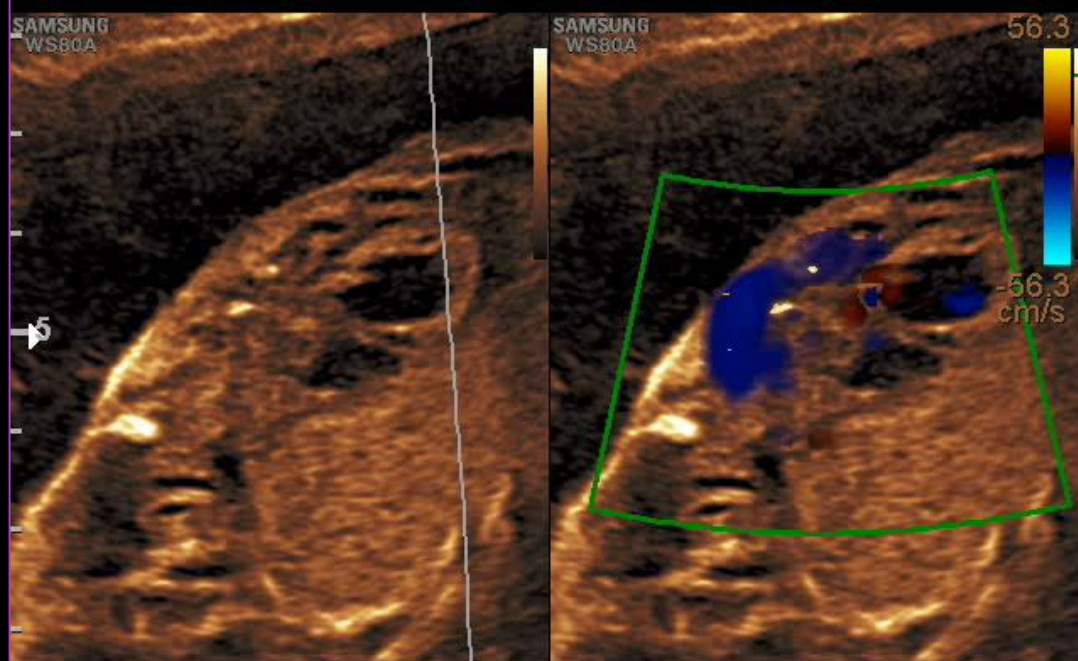


V4-8/OB/COEUYR/FPS17/M1.2/Tlb0.5/2015-05-24 04:54:50 PM

2D G53/DR108/FA7/P90/Frq Res./11.0cm

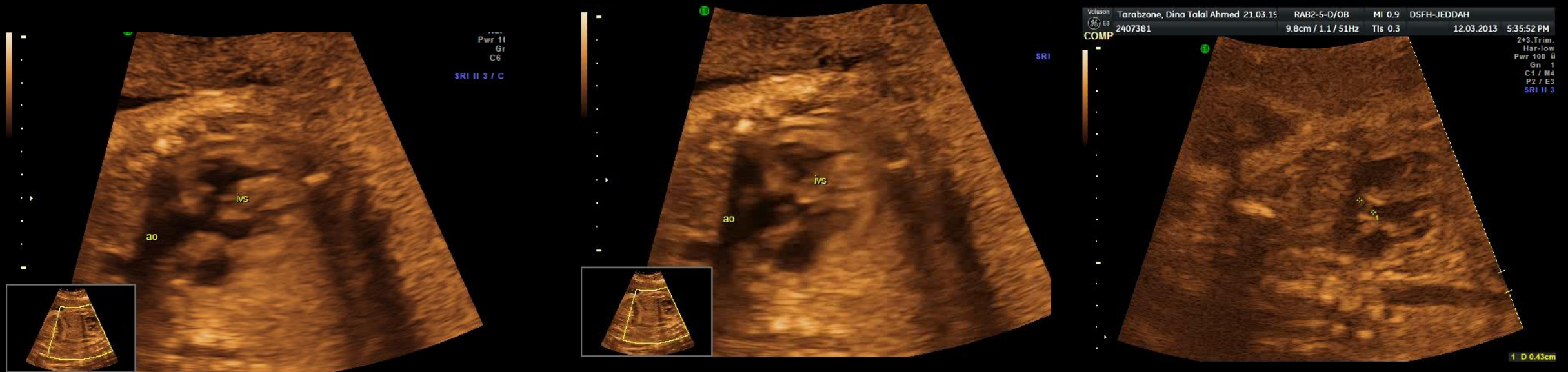


C G50/4.50kHz/F1/FA5



- Literature on associated aortopathy is scarce and focuses mainly on ToF/PA+VSD and TGA.
- While thoracic aortic dilatation is common after repair of conotruncal defects—with aortic wall abnormalities similar to MFS
 - dissection risk is low, with only a few reported cases in ToF
 - TGA patients
- A population-based study covering ~100% of hospitalisation in Texas over 13.5 years found no association between conotruncal defects and risk for aortic dissection: cases per 100 000 conotruncal patient-years (vs 10/100 000 patientyears in the reference population).

Aortic dilatation in ToF (~10% of all CHD)6 has been found on fetal echocardiography. It mainly involves the root but may extend to or predominantly affect the ascending aorta.



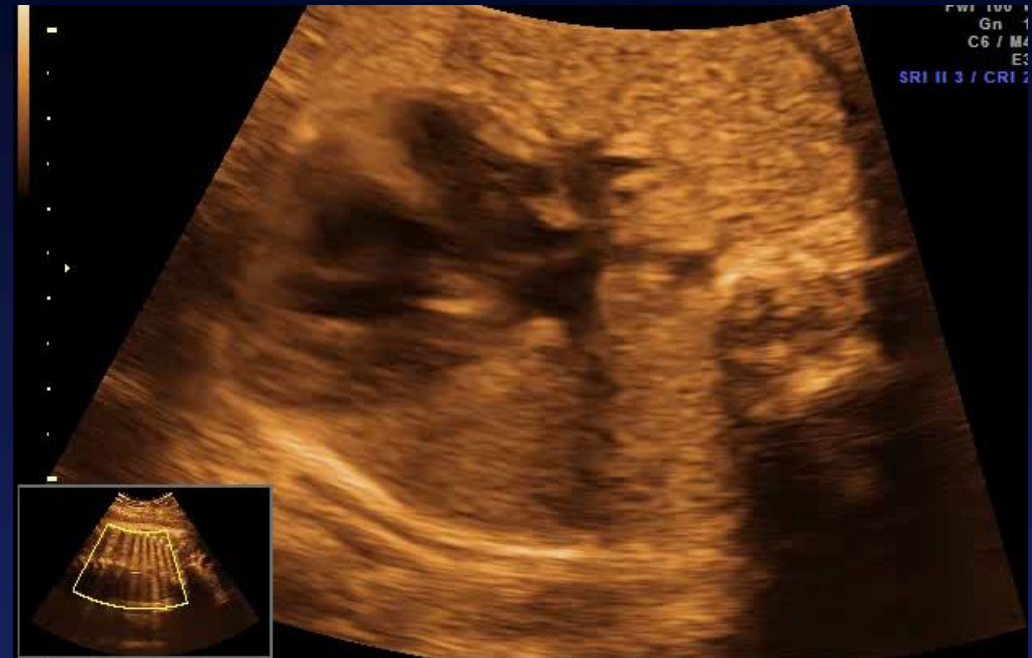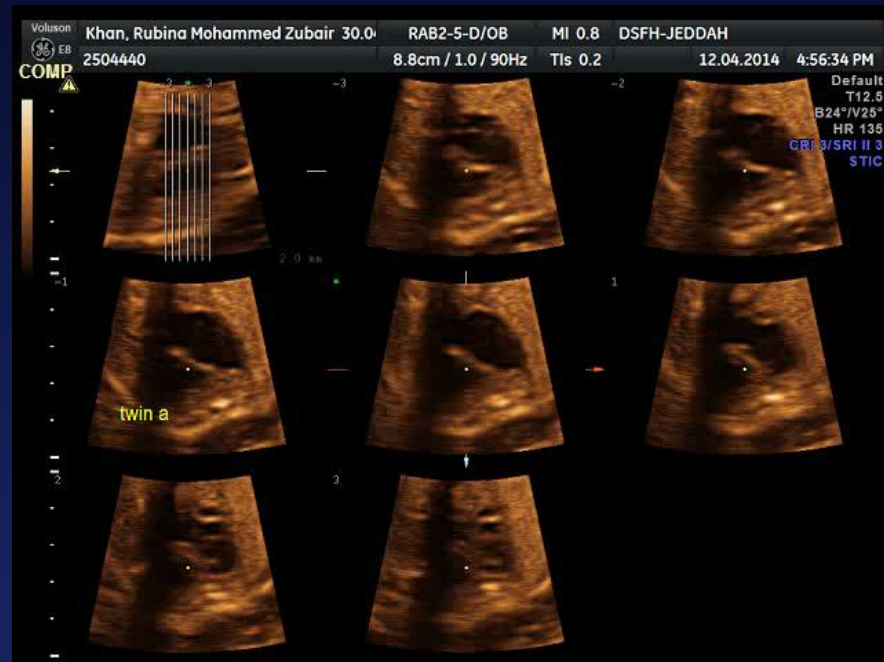
OTHER CHD AND POSTOPERATIVE STATES WITH POSSIBLE AORTIC ROOT DILATION

- After the **Ross procedure**—replacement of the aortic valve and/or root with a pulmonary autograft—autograft dilatation is common
- Need for reoperation, mainly indicated for neo-aortic dilatation,
- is ~20% at 12 years.
- At least 4 dissections in dilated autografts have been reported.
- Propagation of dissection is often limited by the suture lines, possibly improving prognosis relative to native aortic-root dissection
- **Dissection may be asymptomatic due to its limited size and autograft denervation,** thus going undetected while risk of rupture of the weakened autograft is increased

HYPOPLASTIC LEFT HEART SYNDROME (HLHS)—

- HLHS structures and proximal aorta and other univentricular physiologies are preferably treated with three-stage palliative surgery.
 - Stage 1 (Norwood procedure) involves aortic replacement (root) and reconstruction (ascending aorta, arch) using pulmonary homograft material.
 - Stages 2 (Glenn)
 - Stage 3 (Fontan) create bidirectional and total cavopulmonary connections, respectively.
-

HLHS STARTS IN FETAL LIFE



MANAGEMENT GENERAL CONSIDERATIONS

IMAGING

1. Cardiac MRI ***

Measurement of maximal aortic diameter is most accurate perpendicular to its longitudinal axis (figure 2A), while asymmetric root dilatation—particularly relevant to MFS—is best assessed on short-axis views (figure 2B).w

2. Transthoracic echocardiography (TTE) generally adequately visualises the aortic valve, root and proximal ascending aorta, but not the more distal segments. Transoesophageal echocardiography may provide an alternative in patients with poor acoustic windows but is semi-invasive, while CT and MRI provide better assessment and allow aortic diameter measurement perpendicular to the centerline
3. Multidetector CT provides high-resolution images in a short acquisition time, but ionising radiation exposure makes CT less favourable for young patients and routine monitoring.

RISK FACTOR MANAGEMENT

1-MEDICAL THERAPY

- Blood-pressure control is indicated in all patients with thoracic aortic dilatation.
- General blood-pressure targets are recommended in the absence of connective tissue disease.
- Prophylactic pharmacotherapeutic strategies to reduce aortic growth have been studied mainly in MFS: data to support selection of such agents stem largely from studies in MFS

2- SURGICAL MANAGEMENT

AORTIC ROOT DILATATION AND PREGNANCY

- Haemodynamic changes and hormone-induced aortic-wall weakening make pregnancy a period of increased risk for women with aortopathy.
- Risk of dissection is highest in the third trimester and thus, proximal aortic diameter ≥ 45 mm should be a reasonable threshold for prophylactic surgery in MFS women contemplating pregnancy,
- Risk is reportedly high in Loeys-Dietz and vascular Ehlers-Danlos syndrome,
- But data on pregnancy in non-MFS genetic aortopathies are scarce.

- Pregnancy has **not been** associated with increased aortic growth rate or **complication risk in BAV**.
- In a **large series of pregnancies in patients with repaired CoA**, pregnancy was well tolerated, and no aortic dissection or rupture occurred.
- The effect of pregnancy on aortic diameter was not assessed.

AORTIC ROOT DILATATION & SPORTS/EXERCISE

- No specific recommendations for CHD-associated aortopathy other than BAV exist.
- Importantly, all patients with thoracic aortic dilatation should avoid strenuous isometric and resistance exercises.^{4 w108} In general, dynamic (endurance) sports are preferable. Task Force 3 provides recommendations regarding aortic regurgitation.^{w106}

Thank you



1- MARFAN SYNDROME

- As autosomal-dominant disorder variably involving the cardiovascular, skeletal and ocular systems, skin and dura mater results from mutations in the fibrillin-1-encoding FBN-1 gene.
- Incidence is 1:3000–5000 individuals.⁶ Life-expectancy, averaging ~45 years in the pre-open-heart surgery era (with the majority of deaths from aortic dissection or rupture), has increased to ~70 years due to surgical and medical advancements.¹⁰ Aortic dilatation, found in 60%–80% of patients, usually starts at the root but often extends distally later in its natural course.¹¹

2- SURGICAL MANAGEMENT

- Thoracic aortic aneurysms are generally treated by surgical replacement of the affected segment using a tube graft
- **DEFECT-SPECIFIC CONSIDERATIONS**
- Marfan syndrome :
 - Prophylactic aortic surgery is indicated at proximal aortic diameters ≥ 50 mm, as risk of dissection or rupture increases steeply from that diameter onward.
 - A lower diameter threshold may be considered with additional risk factors, including rapid growth, family history of dissection, desired pregnancy and severe aortic or mitral regurgitation.^{2–4}

PATHOPHYSIOLOGY MFS

- The pathophysiology of MFS aortopathy probably involves reduced fibrillin-1 functionality in the aortic wall.
- Fibrillin-1 anchors VSMCs to elastic laminae in the medial extracellular matrix (ECM).
- Deficient functional fibrillin-1 causes VSMC dissociation, inducing elastolytic matrix metalloproteinase (MMP) expression

- Bicuspid aortic valve
- Diagnosis of BAV and associated aortic dilatation may be (incidentally) made on TTE. Given the heterogeneity in pathogenesis³⁰ w31 and natural history¹⁷ w32 w33 of BAV aortopathy and the existence of distinct phenotypic subtypes,w37 w38 an individualised approach to surveillance and treatment may be required.
- Tetralogy of Fallot
- Guidelines focus on follow-up and management of the right ventricular outflow tract but do recognise the occurrence of aortic root dilatation and aortic regurgitation
- While there are no reports suggesting increased risk of aortic dissection or rupture at diameters <55 mm, data to establish specific surgical thresholds for patients with ToF are lacking (table 3).

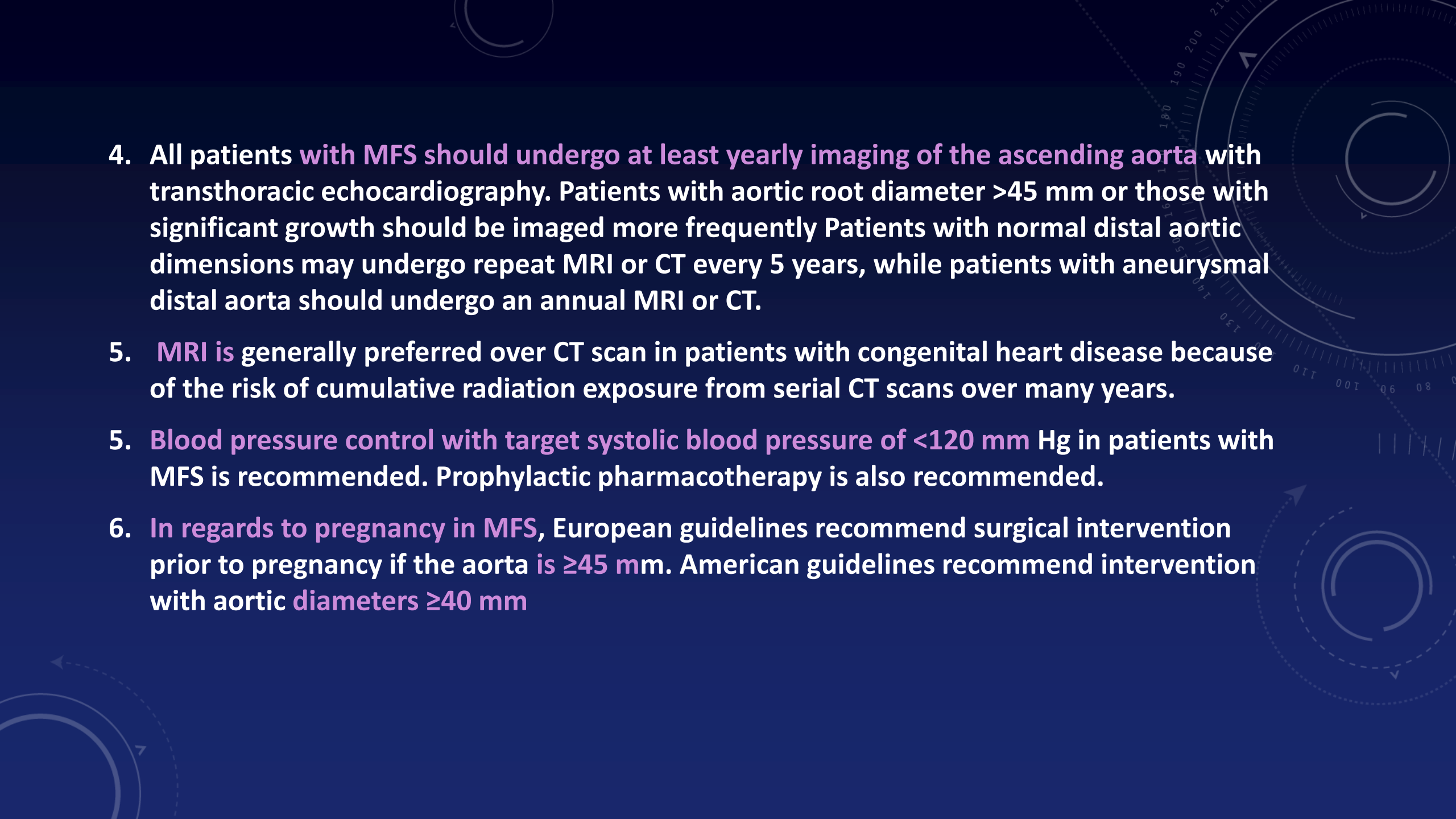
- **Other CHD and postoperative states**
- **Neo-aortic root diameters should be regularly monitored after the Ross procedure, as dilatation and need for reoperation are common.w62 While neo-aortic root dilatation and regurgitation after palliation (Norwood/Fontan) of univentricular physiologies have little impact on outcome, periodic (MRI) follow-up of the aorta is warranted.w65**

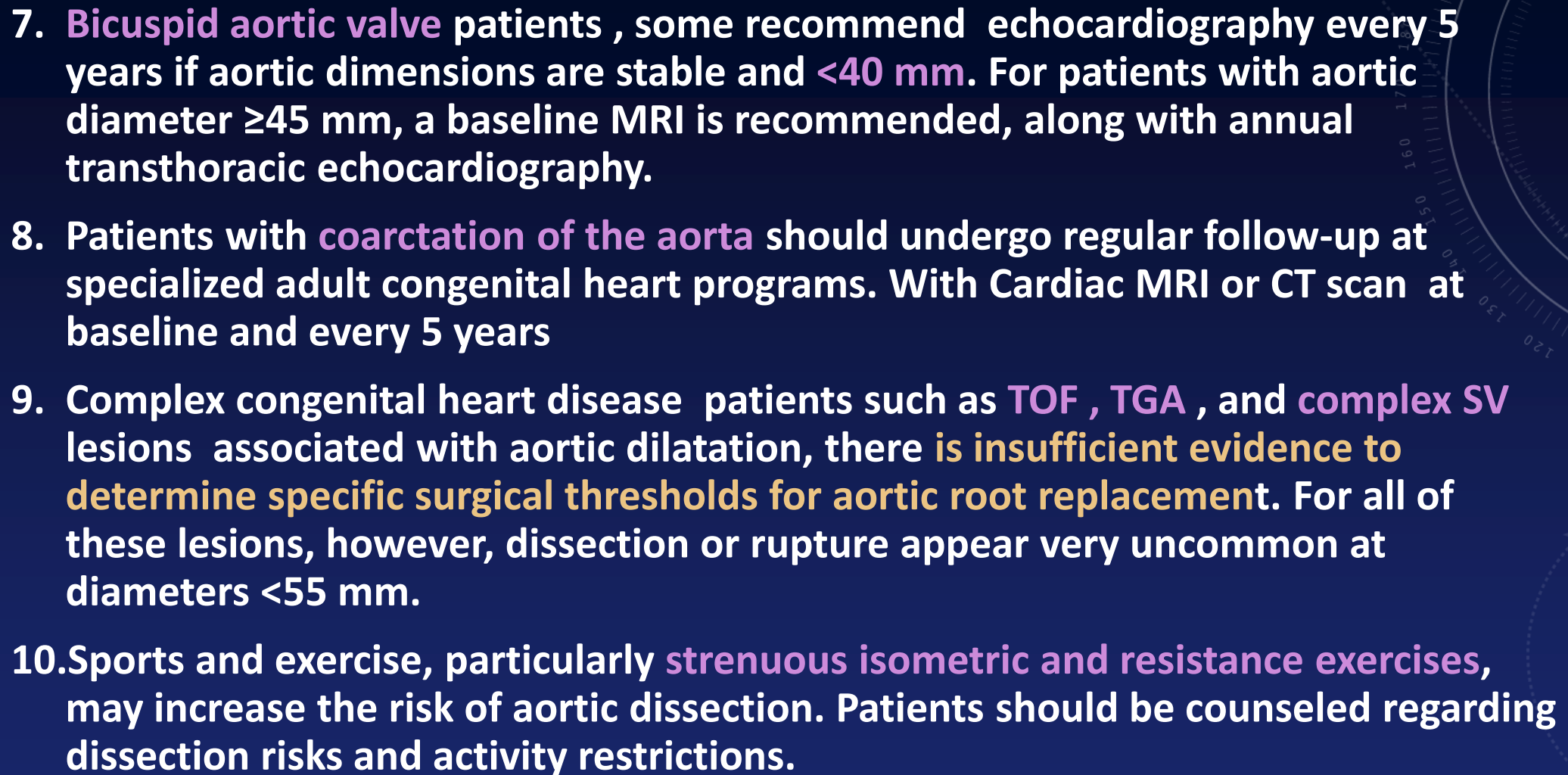
- **After HLHS palliation, progressive dilatation and reduced distensibility of the neo-aortic root, ascending aorta and arch are found**
- **Neo-aortic insufficiency was present in 61% of patients at a median of 9 years after Norwood but was rarely greater than mild.**
- **Root dilatation requiring surgical intervention and neo-aortic dissection are probably rare, with only a few cases and one reported case, respectively.**
- **Moreover, aortic dissection is an uncommon cause of death longterm after Fontan palliation: in 261 patients with various underlying defects followed for a median of 12 years after Fontan surgery, aortic dissection was the cause of only one of 76 deaths.**

TAKE HOME MESSAGE:

MANAGING AORTOPATHIES IN ADULT CONGENITAL HEART DISEASE AND GENETIC AORTOPATHY SYNDROMES

1. **Progressive proximal aortic dilatation** is common in adults with congenital heart disease.
2. The heterogeneity of disease processes **and limited data for dissection risk for most complex congenital heart disease** present a challenge to providers.
3. In patients with Marfan syndrome (MFS), risk for dissection increases significantly at **aortic diameters ≥ 50 mm**. Risk factors for dissection include family history of aortic dissection and pregnancy.
4. **Neo-aortic dilatation is common in patients after ASO for TGA**, occurring in 50-65% of patients. Significant aortic valve regurgitation and the need for aortic surgery appear to be rare

- 
4. All patients with MFS should undergo at least yearly imaging of the ascending aorta with transthoracic echocardiography. Patients with aortic root diameter >45 mm or those with significant growth should be imaged more frequently. Patients with normal distal aortic dimensions may undergo repeat MRI or CT every 5 years, while patients with aneurysmal distal aorta should undergo an annual MRI or CT.
 5. MRI is generally preferred over CT scan in patients with congenital heart disease because of the risk of cumulative radiation exposure from serial CT scans over many years.
 5. Blood pressure control with target systolic blood pressure of <120 mm Hg in patients with MFS is recommended. Prophylactic pharmacotherapy is also recommended.
 6. In regards to pregnancy in MFS, European guidelines recommend surgical intervention prior to pregnancy if the aorta is ≥ 45 mm. American guidelines recommend intervention with aortic diameters ≥ 40 mm.

- 
7. **Bicuspid aortic valve** patients , some recommend echocardiography every 5 years if aortic dimensions are stable and **<40 mm**. For patients with aortic diameter ≥ 45 mm, a baseline MRI is recommended, along with annual transthoracic echocardiography.
 8. Patients with **coarctation of the aorta** should undergo regular follow-up at specialized adult congenital heart programs. With Cardiac MRI or CT scan at baseline and every 5 years
 9. Complex congenital heart disease patients such as **TOF , TGA , and complex SV** lesions associated with aortic dilatation, there **is insufficient evidence to determine specific surgical thresholds for aortic root replacement**. For all of these lesions, however, dissection or rupture appear very uncommon at diameters < 55 mm.
 10. Sports and exercise, particularly **strenuous isometric and resistance exercises**, may increase the risk of aortic dissection. Patients should be counseled regarding dissection risks and activity restrictions.

REFERENCES

1. Massive aortic aneurysm and dissection in repaired tetralogy of Fallot; diagnosis by cardiovascular magnetic resonance imaging. Rathi VK, Doyle M, Williams RB, Yamrozik J, Shannon RP, Biederman RW. Int J Cardiol. 2005 May 11;101(1):169-70.
2. Progression rate and early surgical experience in the new aggressive aneurysms-osteoarthritis syndrome. van der Linde D, Bekkers JA, Mattace-Raso FU, van de Laar IM, Moelker A, van den Bosch AE, van Dalen BM, Timmermans J, Bertoli-Avella AM, Wessels MW, Bogers AJ, Roos-Hesselink JW. Ann Thorac Surg. 2013 Feb;95(2):563-9. doi: 10.1016/j
3. Pattern of ascending aortic dimensions predicts the growth rate of the aorta in patients with bicuspid aortic valve. Della Corte A, Bancone C, Buonocore M, Dialetto G, Covino FE, Manduca S, Scognamiglio G, D'Oria V, De Feo M. JACC Cardiovasc Imaging. 2013 Dec;6(12):1301-10. doi: 10.1016/j.jcmg.2013.07.009. Epub 2013 Oct 23.

- **Transposition of the great arteries**
- Imaging surveillance is indicated in all TGA patients, with TTE follow-up of the (neo-) aortic valve and root particularly in post-ASO patients.
- Assessment of arch geometry may be incorporated: acute angulation is associated with aortic dilatation.^{w96} Prophylactic surgery after ASO has been recommended for neo-aortic root dilatation ≥ 55 mm, based on recommendations for degenerative aortic root aneurysms.
- While there are no reports suggesting increased risk of neo-aortic dissection or rupture at diameters < 55 mm, data to establish specific surgical thresholds for post-ASO patients are lacking (table 3).
- Neo-aortic root operations are safe, despite technical challenges imposed by complex anatomy, but are uncommon up to 15 years after ASO.

❑ Evidence suggests fibrillin-1 additionally sequesters and stabilizes transforming growth factor (TGF)- β in latent complexes.

❑ In fibrillin-1-deficient mice, typical aortic wall damage was associated with increased TGF- β activity and was prevented by administration of TGF- β antibodies or angiotensin II type 1 receptor blockers (ARB; TGF- β signalling down-regulators).

HISTOPATHOLOGY AND PATHOPHYSIOLOGY

- ❑ MFS aortopathy is characterised by elastic lamina fragmentation, vascular smooth muscle cell (VSMC)
- ❑ loss and extracellular mucoid material accumulation in the aortic wall media.
- ❑ This ‘cystic medial necrosis’ is also found in dilated/dissected aortas of other aetiologies and the ageing aorta but is more extensive in MFS.

LIMITATIONS

- **❓ Insufficient validation**
- **❓ Limited applicability to children**
- **❓ Requirement of expensive and specialized evaluation**
- **❓ Overdiagnosis even when Aorta not involved – clinically less important phenotype**
- **❓ Dural ectasia, a major criteria, is often seen in other connective tissue disorders (including both LDS and SGS)**

- ❑ The pathophysiology of MFS aortopathy probably involves reduced fibrillin-1 functionality
- ❑ in the aortic wall. Fibrillin-1 anchors VSMCs to elastic laminae in the medial extracellular matrix
- ❑ (ECM). Deficient functional fibrillin-1 causes VSMC dissociation, inducing elastolytic matrix metalloproteinase (MMP) expression. Resultant elastic laminar fragmentation, ECM disruption
- ❑ VSMC apoptosis impair aortic wall structural integrity and elasticity.