



# ACC Middle East Conference 2018

In partnership with:



الجمعية السعودية لأمراض القلب  
Saudi Heart Association

## *Advanced Heart Failure*

Waleed AlHabeeb, MD, MHA

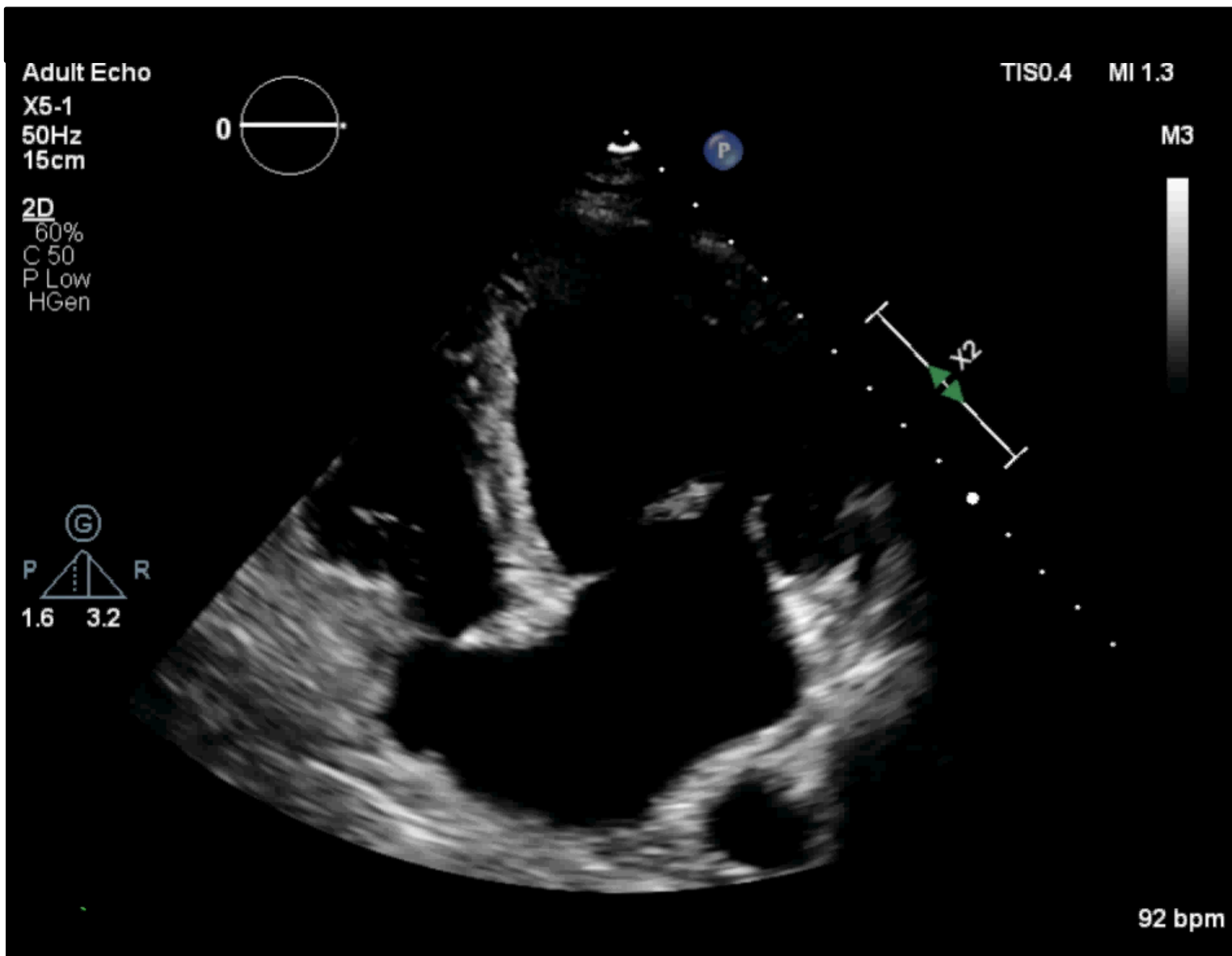


- 63 Y/O gentleman
- Businessman
- No DM or HTN
- Heavy smoker
- Presented in January 2018 with chest pain for 2 hours and SOB
- AWWMI
- Code STEMI

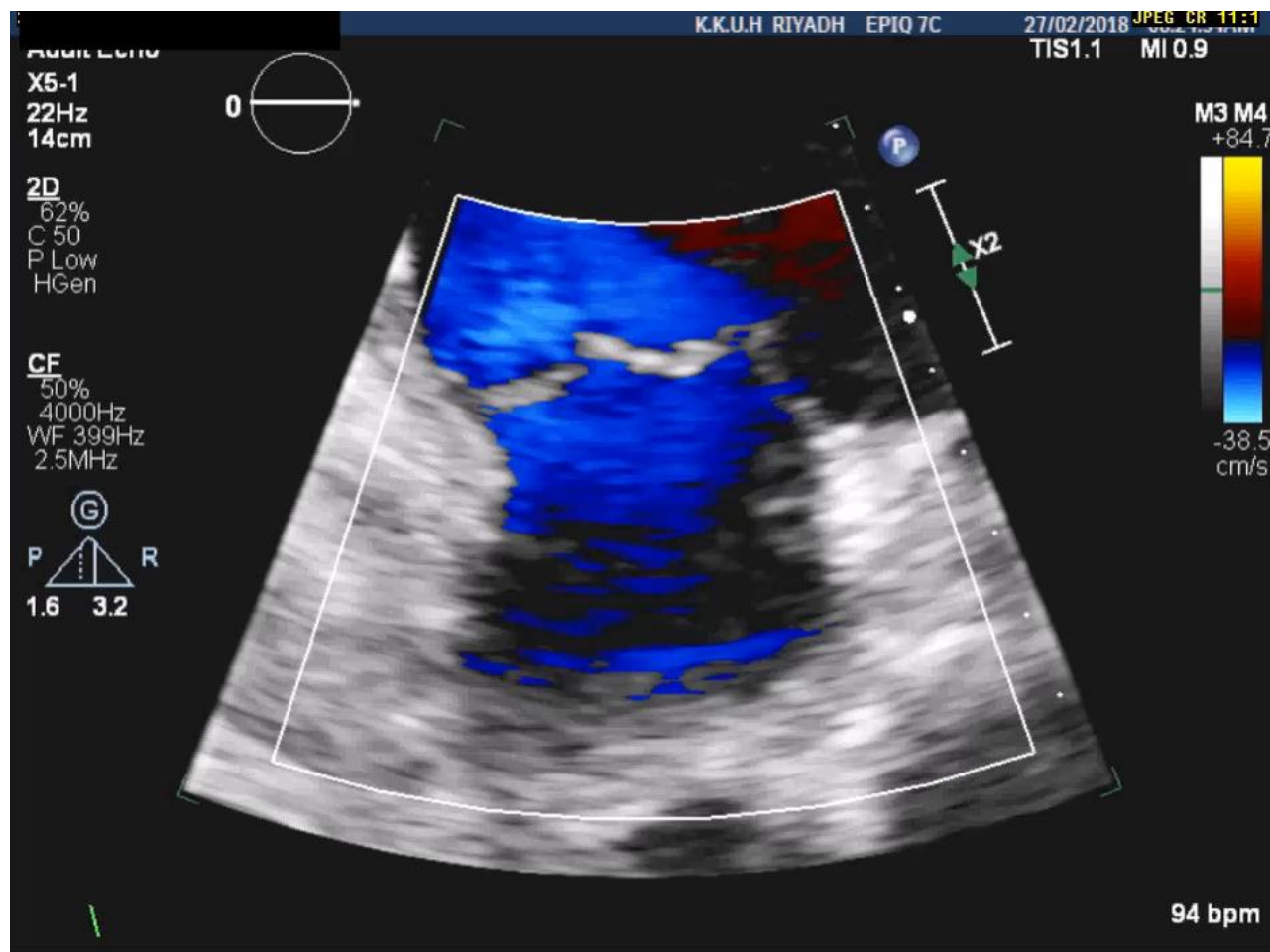


- Patient remained in heart failure for few days requiring high dose diuretics and cautious vasodilators
- Discharged on small doses of neurohormonal blockers and close followup
- In less than a month he was admitted again with decompensation





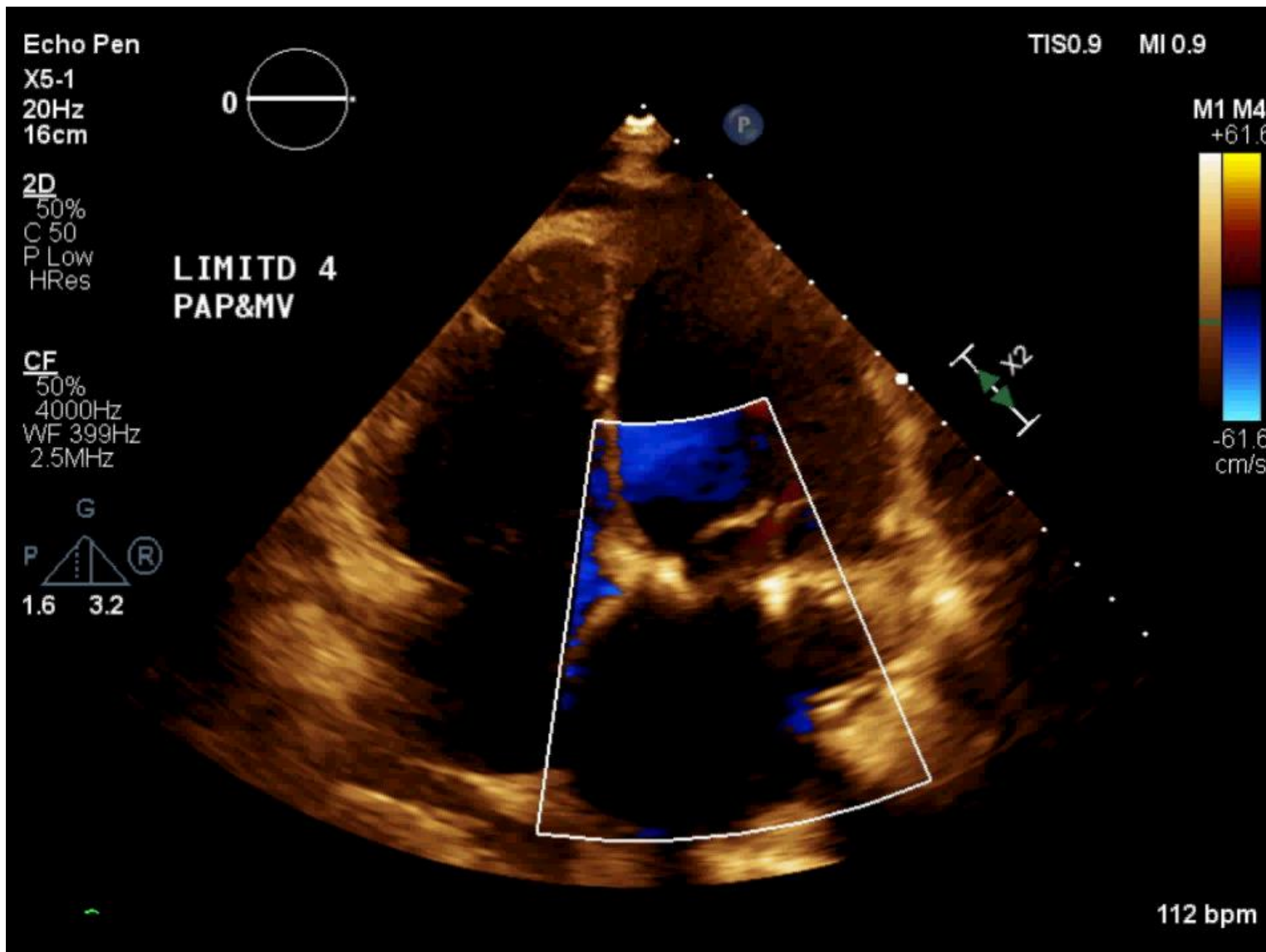
ACC.18



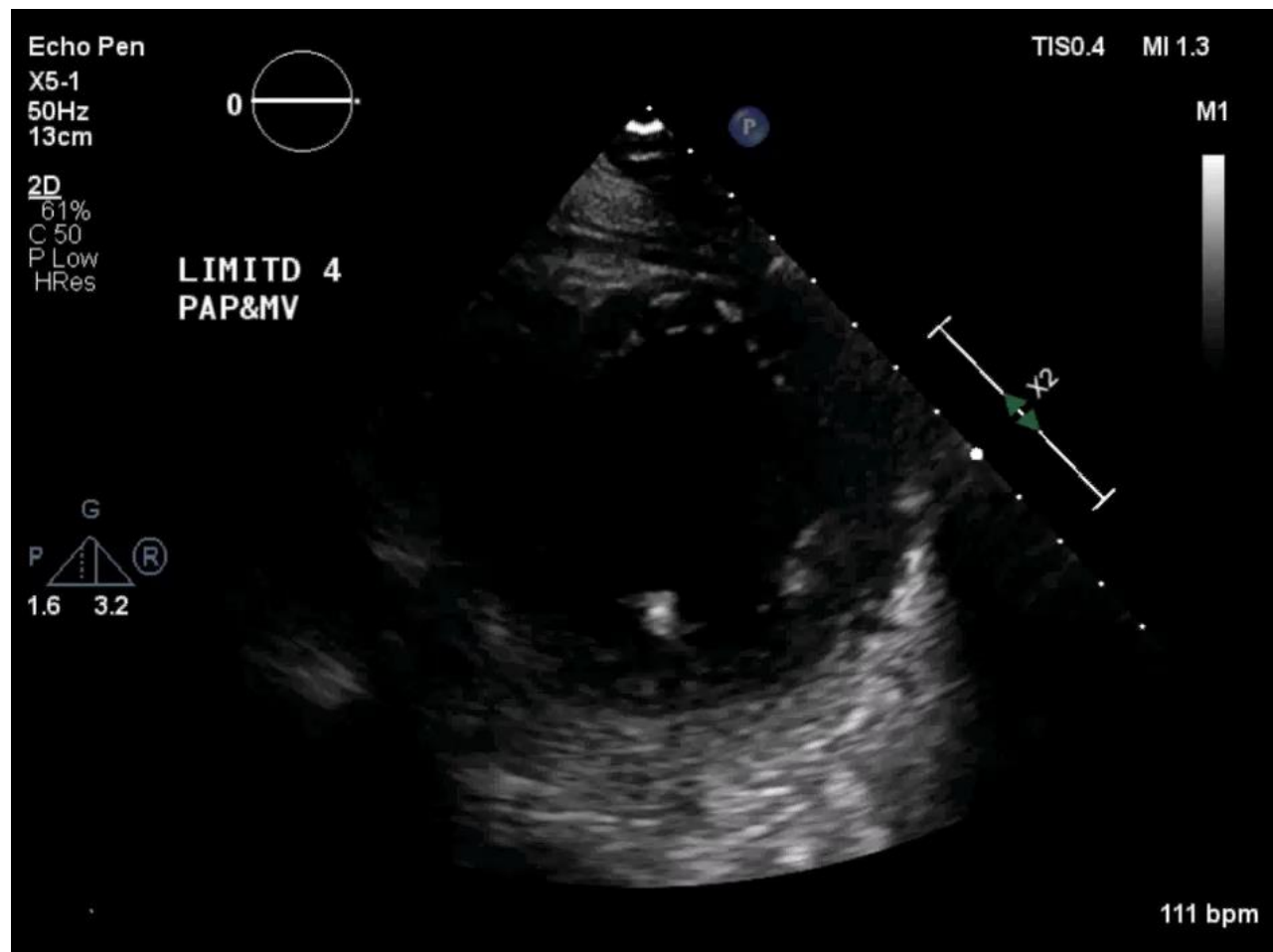
ACC.18™

- Switched to Sacubitril/Valsartan started 50mg BID because of BP 90s
- Had MV repair + CABG in March



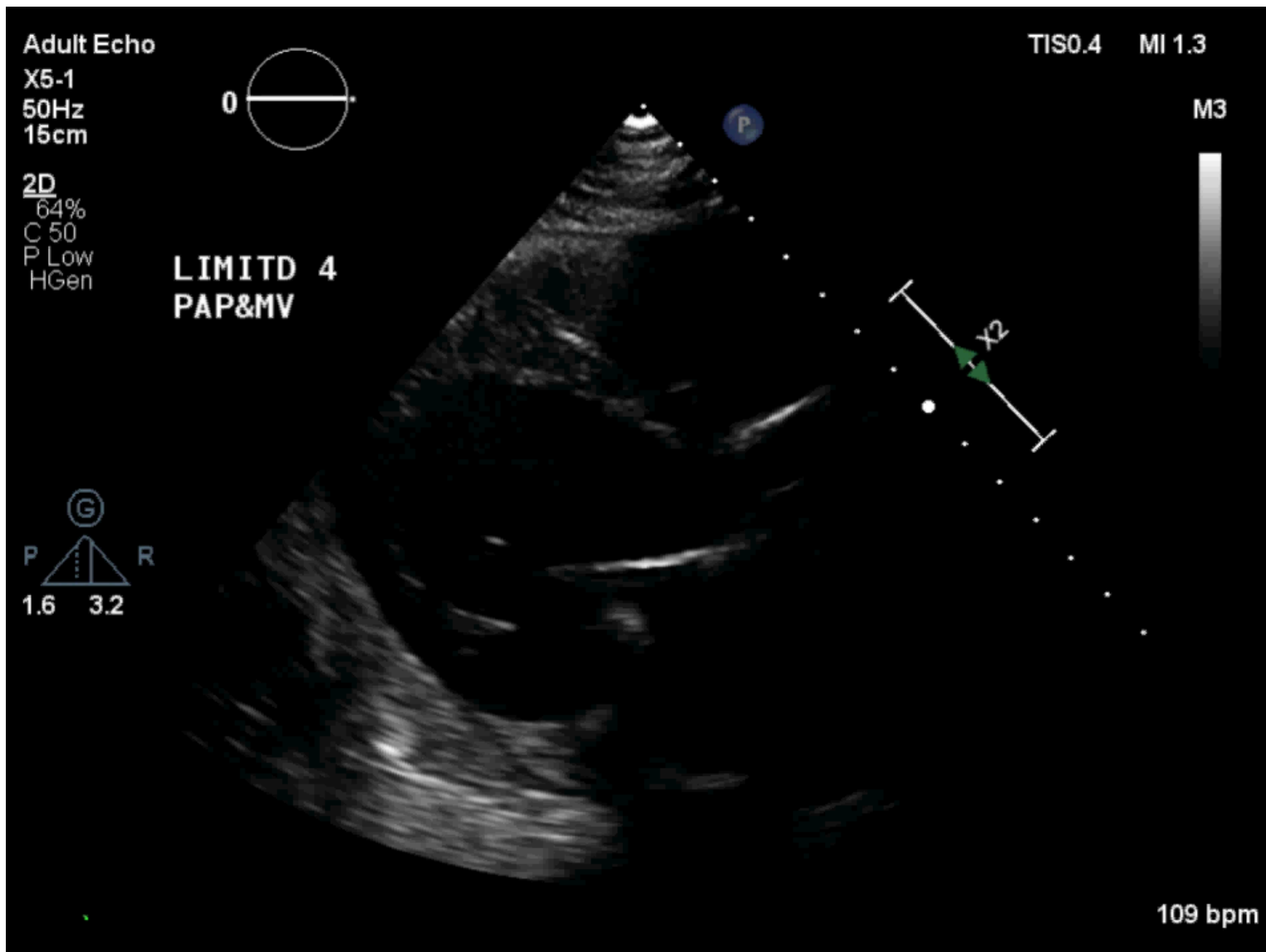


ACC.18™



ACC.18





ACC.18

X5-1  
50Hz  
15cm

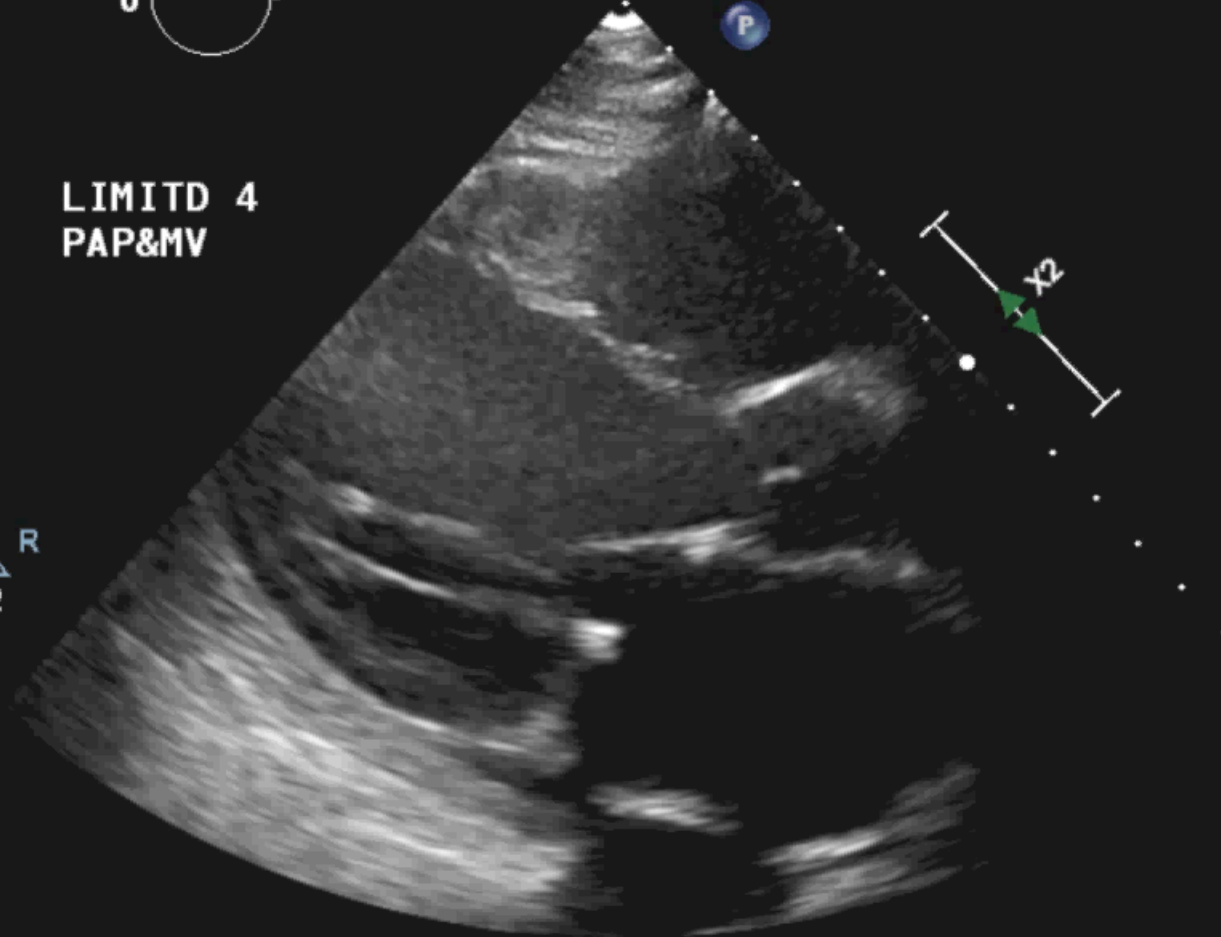
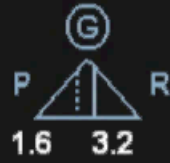

TISO.4 MI 1.3

M3

2D  
64%  
C 50  
P Low  
HGen

LIMITD 4  
PAP&MV



90 bpm



ACC.18

- Followed in outpatient, slowly up-titrating, creatinine up to 220 (80)
- Switched to Hydralazine/Nitrates
- Admitted again in May and September
- Current BP 90/60 HR 90
- Cr 160 K 4 Na 138 NtProBNP 5000





# ACC Middle East Conference 2018

In partnership with:



Support your heart  
Middle East Heart Association

# Thank You..

