Vasovagal Syncope and Bradyarrhythmias Mechanisms, distinguishing cause and effect

Walid Saliba, MD, FHRS, FACC

Director EP lab

Director Atrial Fibrillation Center

Department of Cardiovascular Medicine

Cleveland Clinic

Cleveland Clinic

ESC 2018

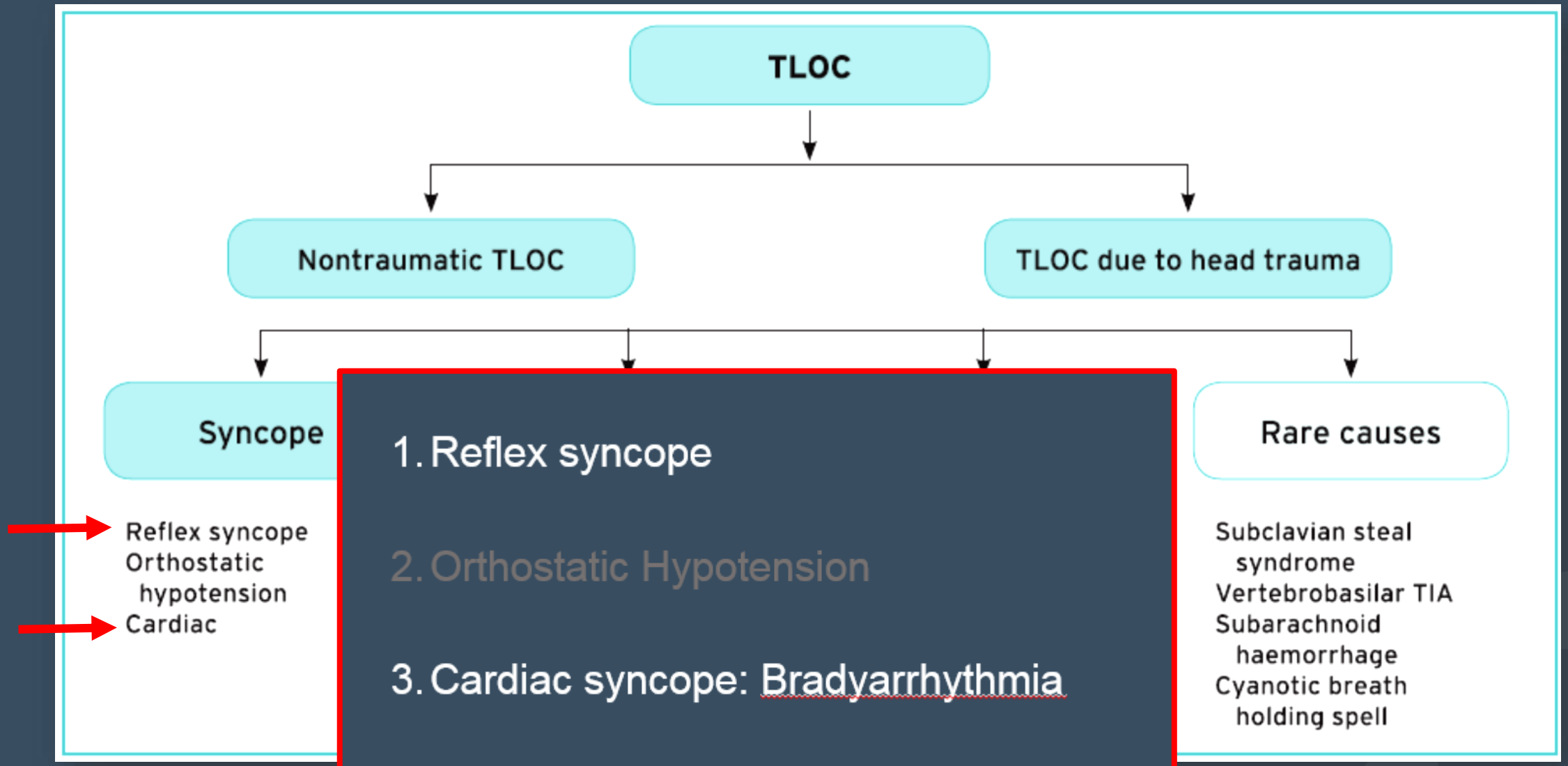

1. Reflex syncope
2. Orthostatic Hypotension
3. Cardiac syncope: Bradyarrhythmia

Eur Heart J. 2018 Jun 1;39(21):1883-1948.

1. *Reflex Syncope (aka NMS / NCS)*

- **Vasovagal syncope**
  1. Upright posture or sitting, emotional stress, pain, or medical settings.
  2. Features: diaphoresis, warmth, nausea, and pallor;
  3. Vasodepressor hypotension and/or inappropriate bradycardia
  4. Followed by fatigue
- **Situational syncope**
  - Coughing, laughing, swallowing, micturition, or defecation
- **Carotid Sinus Syndrome**
  - Tight collar, necktie, carotid massage

Eur Heart J. 2009 Nov;30(21)
Heart Rhythm, Vol 12, No 6, June 2015

1. Reflex Syncope - Vasovagal Mechanisms

- Exagerated Cardiovascular reflexes in regulating BP

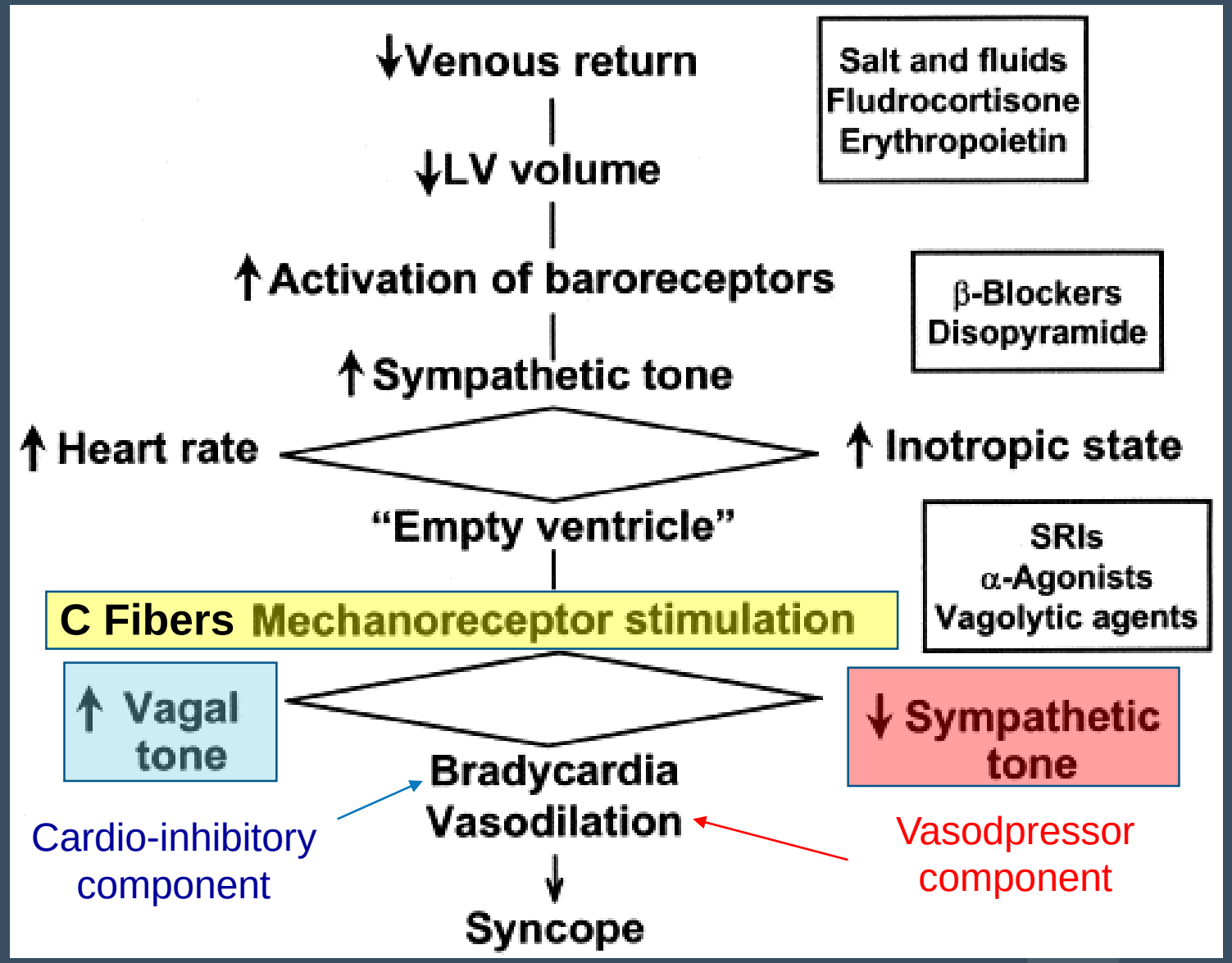

Reflex Vasovagal Syncope

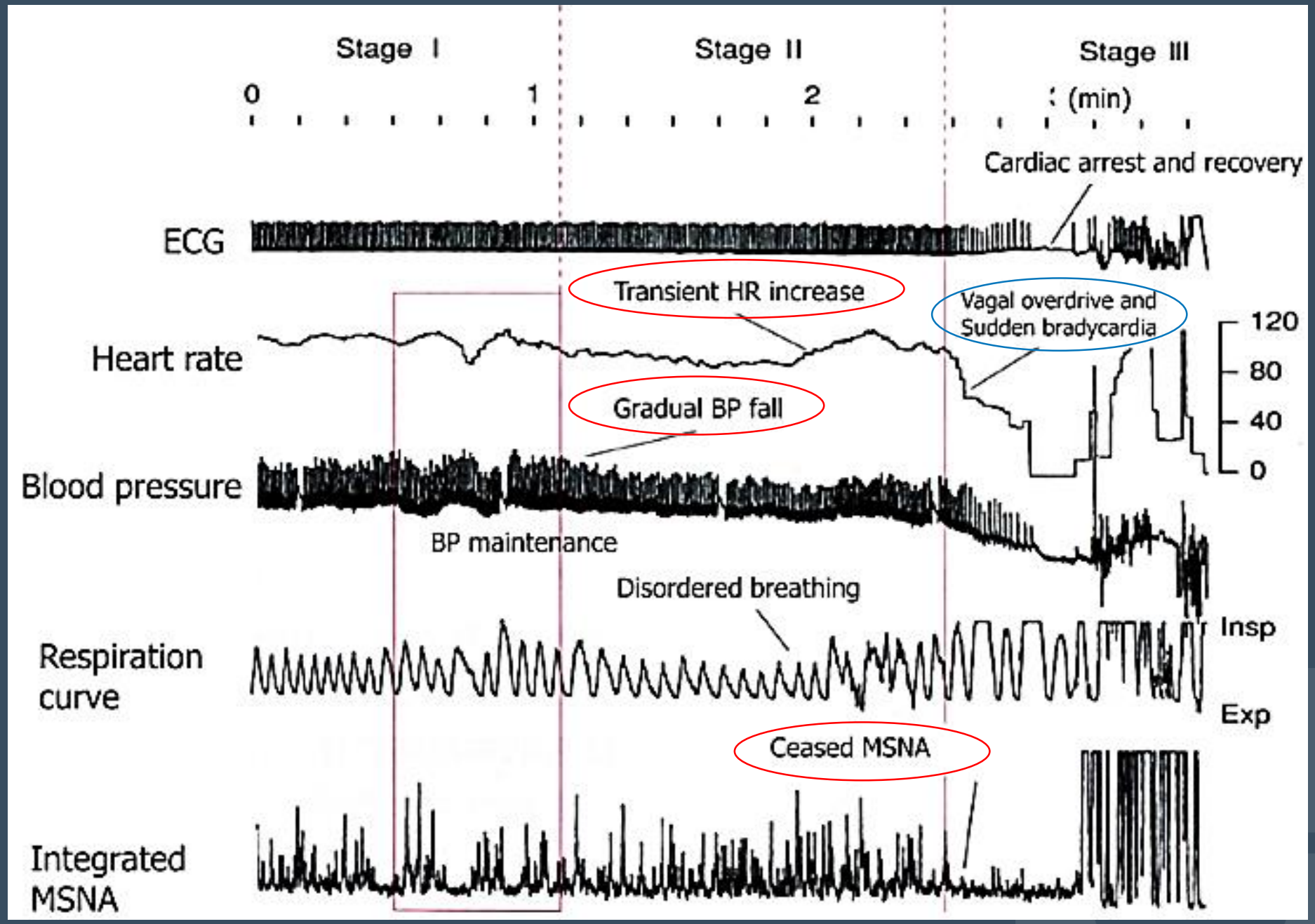

EKG

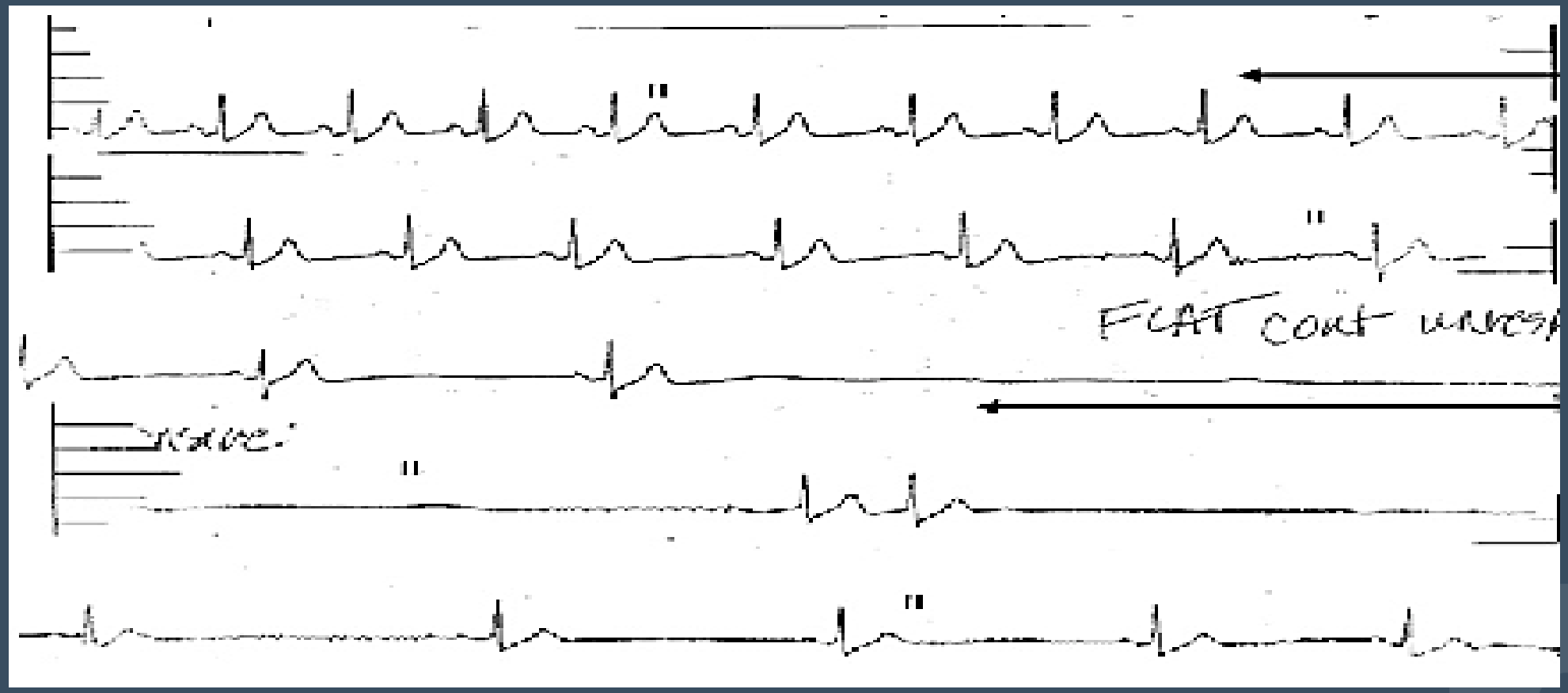

Progressive slowing of the SR (may be rapid) +/- Increase in PR
→Sinus Arrest or AVB→ Asystole

Diagnosis

History
History
History
History
History
History
History
History
History
History
History

- Younger age (CSS more in elderely)
- No Known Cardiac disease
- Syncope in the standing position
- Presence of prodrome : Nausea, vomiting, yawning, feeling warmth, diaphoresis
- Presence of specific triggers: pain, distressful stimulus, medical environment
- Situational triggers: cough, laugh, micturition, deglutition, defecation, prolonged standing.
- Recurrences of syncope with similar characteristics.

Management of reflex syncope

ACC/AHA Treatment for VVS

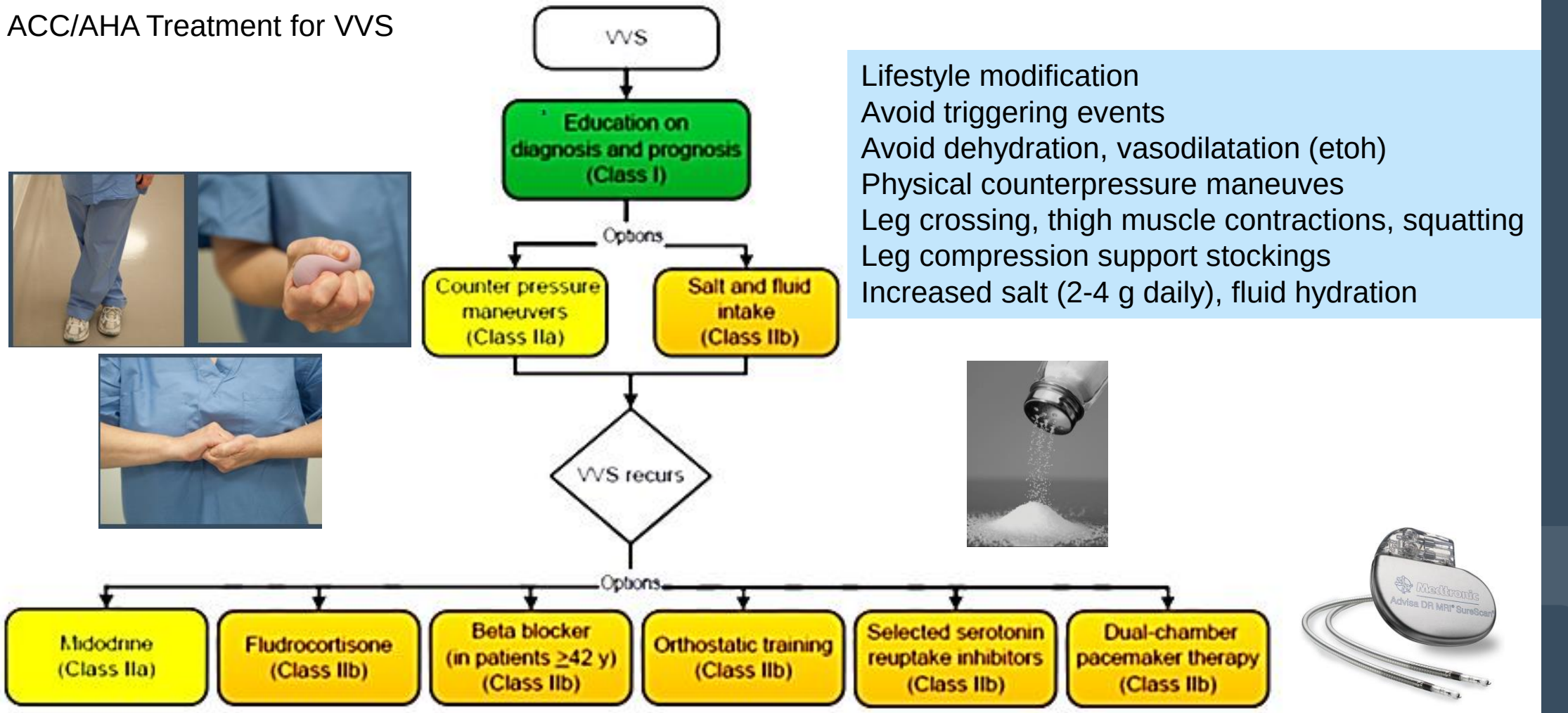

Lifestyle modification
Avoid triggering events
Avoid dehydration, vasodilatation (etoh)
Physical counterpressure maneuves
Leg crossing, thigh muscle contractions, squatting
Leg compression support stockings
Increased salt (2-4 g daily), fluid hydration

Disappointing/ Frustrating

Circulation. **2017** Aug 1;136(5):e25-e59

Pacemakers

- Overall limited role in Vasovagal Syncope

- Vasovagal syncope usually both vasodepressor as well as cardioinhibitory
  - Tilt test can be used to help identify patient who may not benefit from PPM (2B)

ISSUE 3

- 77 pts (age >40 yrs)
- Syncope (with asystole)
  - >3 sec asystole or
  - 6 sec asystole without syncope on ILR
- PPM implanted
- Rate Drop Response vs Sensing only

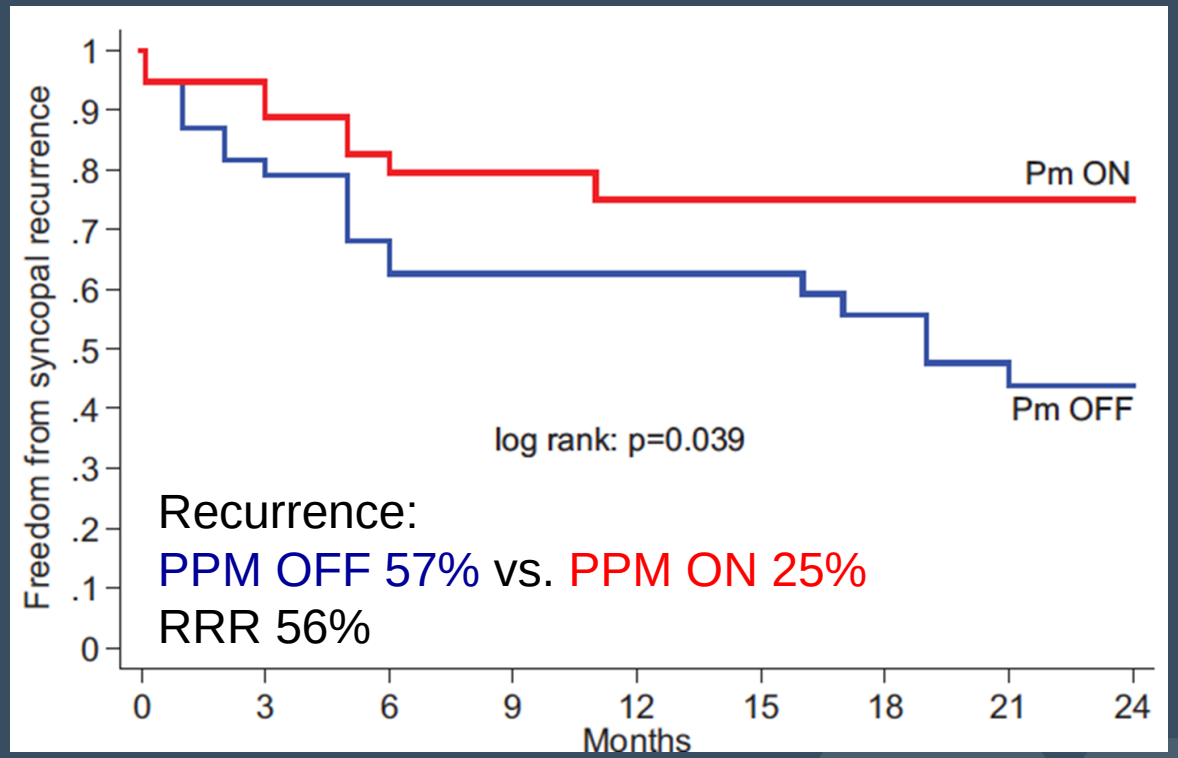

COR	LOE	Recommendation
IIb	B-R SR	Dual-chamber pacing might be reasonable in a select population of patients 40 years of age or older with recurrent VVS and prolonged spontaneous pauses.

Circulation. 2012; 125: 2566-257

2. *Bradyarrhythmia*

- Sinus node Dysfunction (SSS)

- AV block
  - 2nd / 3rd. Degree AVB
  - High Grade
  - 2:1 AV block

Sinus Node / AV node Dysfunction: Causes

- Idiopathic degenerative fibrosis
- Congenital heart disease
- Musculoskeletal disorder

- Infiltrative disorders (amyloid..)
- Infectious diseases (Lyme..)
- Inflammatory disease (Sarcoid..)
- Cardiothoracic surgery

- Pharmacologic agents* (BB,CCB,AAD..)
- Electrolyte disturbances
- Hypothyroidism
- Ischemia (including infarction)
- Hypothermia

- Sleep apnea
- Increased vagal tone (athlete..)
- Coughing, Vomiting , Defecation, micturition

Pathologic
Reversible
Physiologic

Case 1

- 55 year old architect
- No structural heart disease
- Athletic, jogs 45 minutes every day
- Developed recurrent palpitations and 2 episodes of syncope

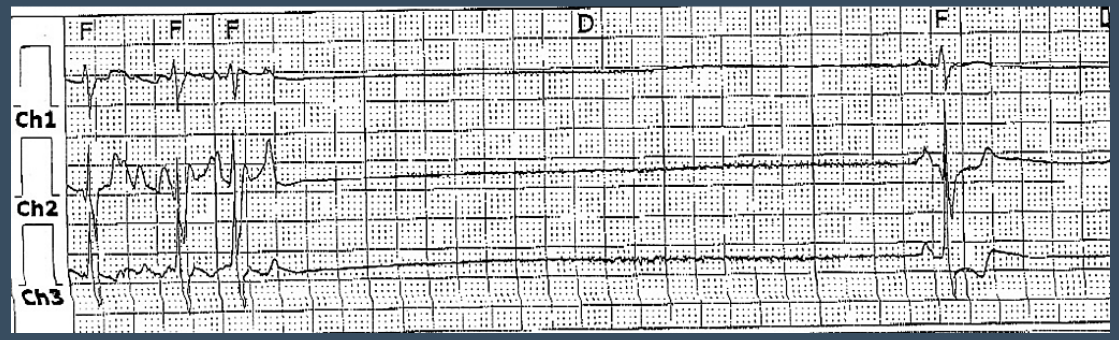

WHAT NEXT?

1. PPM + Beta Blockers
2. PPM + AAD
3. Reassure
4. Other: AF ablation…

Pulmonary Vein Isolation for Atrial Fibrillation in Patients with Symptomatic Sinus Bradycardia or Pauses

YAARIV KHAYKIN, M.D., NASSIR F. MARROUCHE, M.D., DAVID O. MARTIN, M.D., WALID SALIBA, M.D., ROBERT SCHWEIKERT, M.D., MARK WEXMAN, M.D.,* BRIAN STRUNK, M.D.,* SALWA BEHEIRY, R.N.,* EDUARDO SAAD, M.D., MANDEEP BHARGAVA, M.D., J. DAVID BURKHARDT, M.D., GEORGE JOSEPH, M.D., PATRICK TCHOU, M.D., and ANDREA NATALE, M.D.

Sinus node dysfunction improved after AF catheter ablation

- No
pati
- Pati
(64

Brief Rapid Communication

Reverse Remodeling of Sinus Node Function After Catheter Ablation of Atrial Fibrillation in Patients With Prolonged Sinus Pauses

Mélèze Hocini, MD; Prashanthan Sanders, MBBS; Isabel Deisenhofer, MD; Pierre Jaïs, MD; Li-Fern Hsu, MBBS; Christophe Scavée, MD; Rukshen Weerasoriya, BMedSc(Hons), MBBS; Florence Raybaud, MD; Laurent Macle, MD; Dipen C. Shah, MD; Stéphane Garrigue, MD; Philippe Le Metayer, MD; Jacques Clémenty, MD; Michel Haïssaguerre, MD

Case 2

- 51 year old male with no significant PMH
- Admitted for recurrent syncope
- EKG: 2:1 AV block; does not improve with walking
- Echo: LVEF 50%, Inf WMA
- Cath: Normal coronaries
- ? h/o tick bite 1 year ago → lime titers negative
- Thyroid normal / no meds

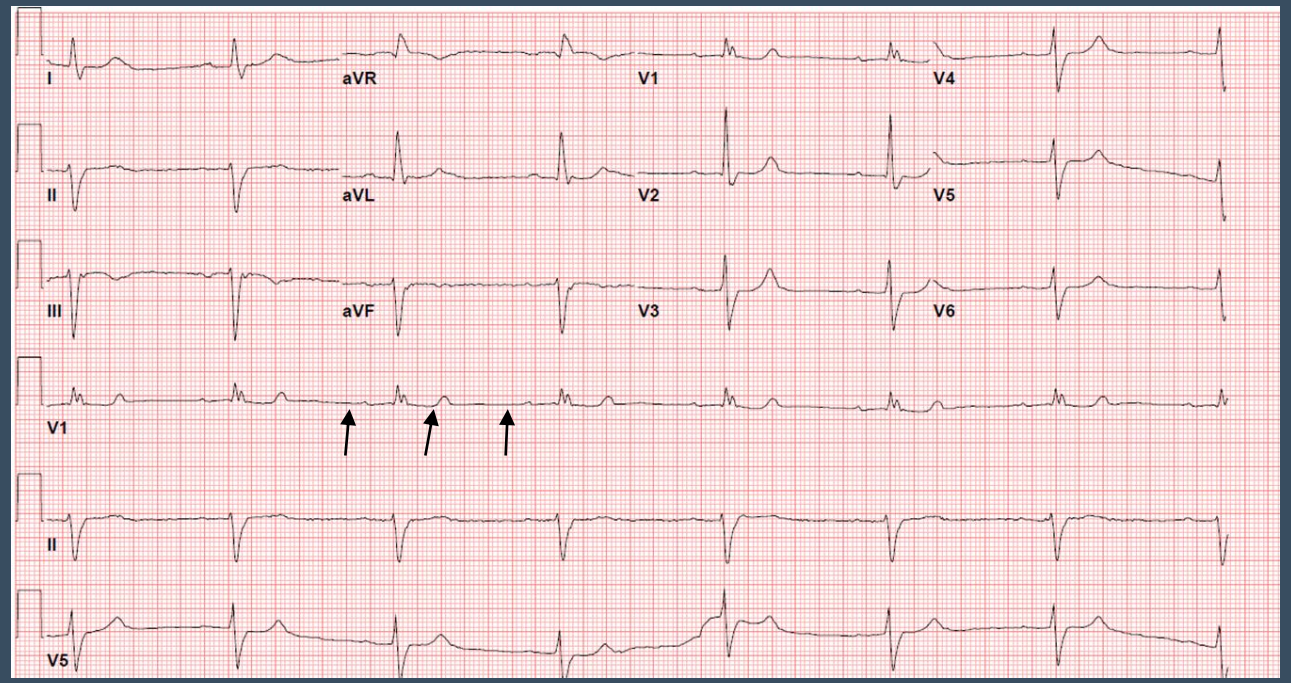

- EKG following day; feels better

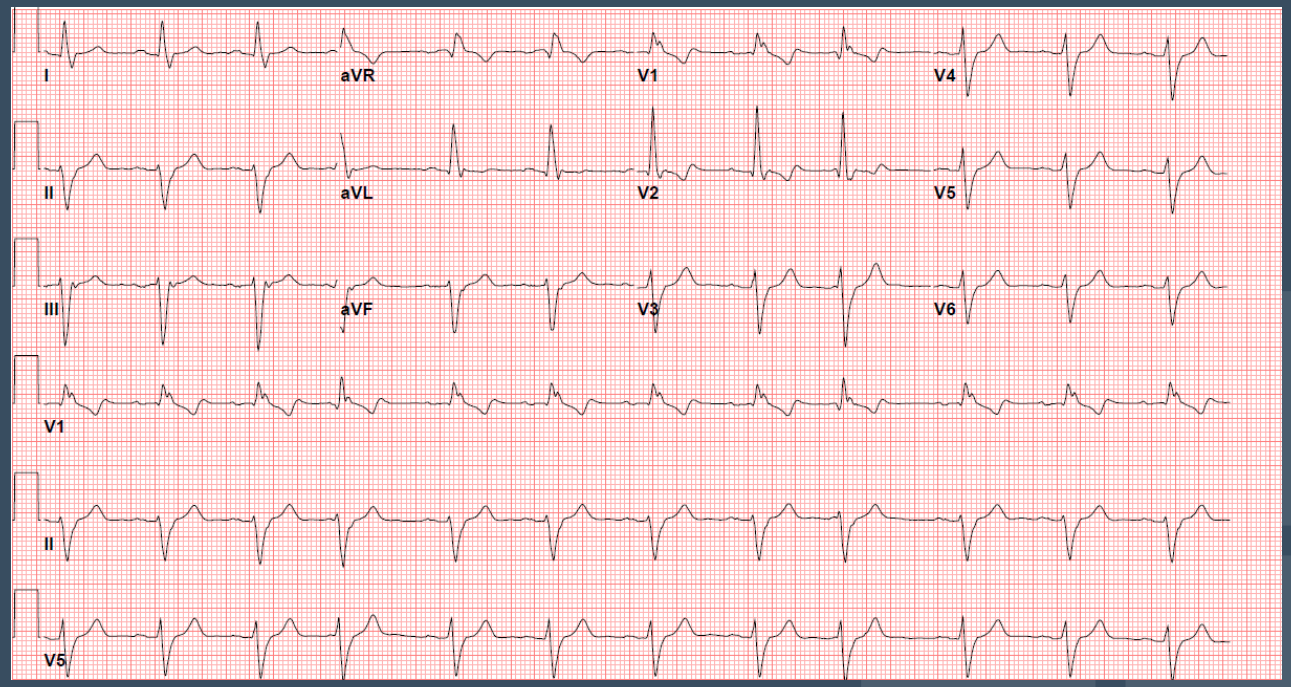

Case 2

- FDG-PET
  - The total Myocardium Perfusion Defect is 6 %.
  - The total Myocardium with Inflammation is 40 %
- Bronch: TBNA: Non caseating granuloma
- Started on Prednisone 30 mg/d

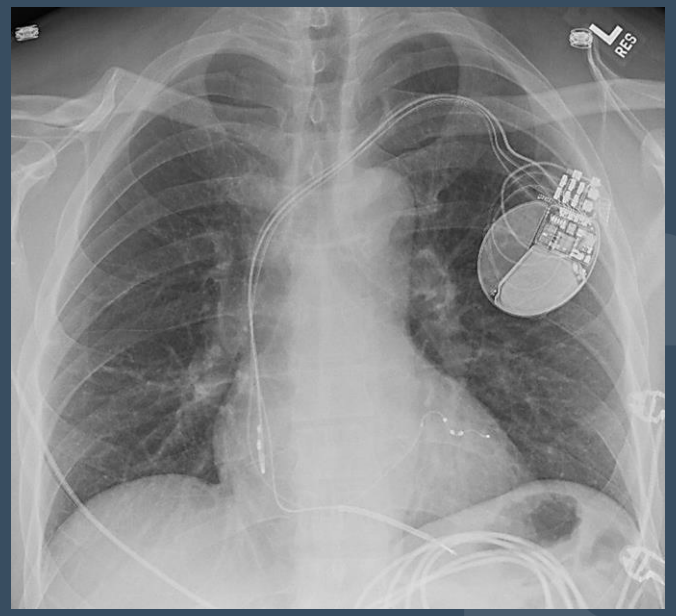

- Do we have a diagnosis?

- Now what? →PPM? ICD? CRT? CRT-D?

Case 3

- 66 year old male
- Known to have “slow heart beat”
- Refused pacemaker in the past
- Good exercise tolerance
- No syncope
- Echo: Normal size LV. Normal LVEF

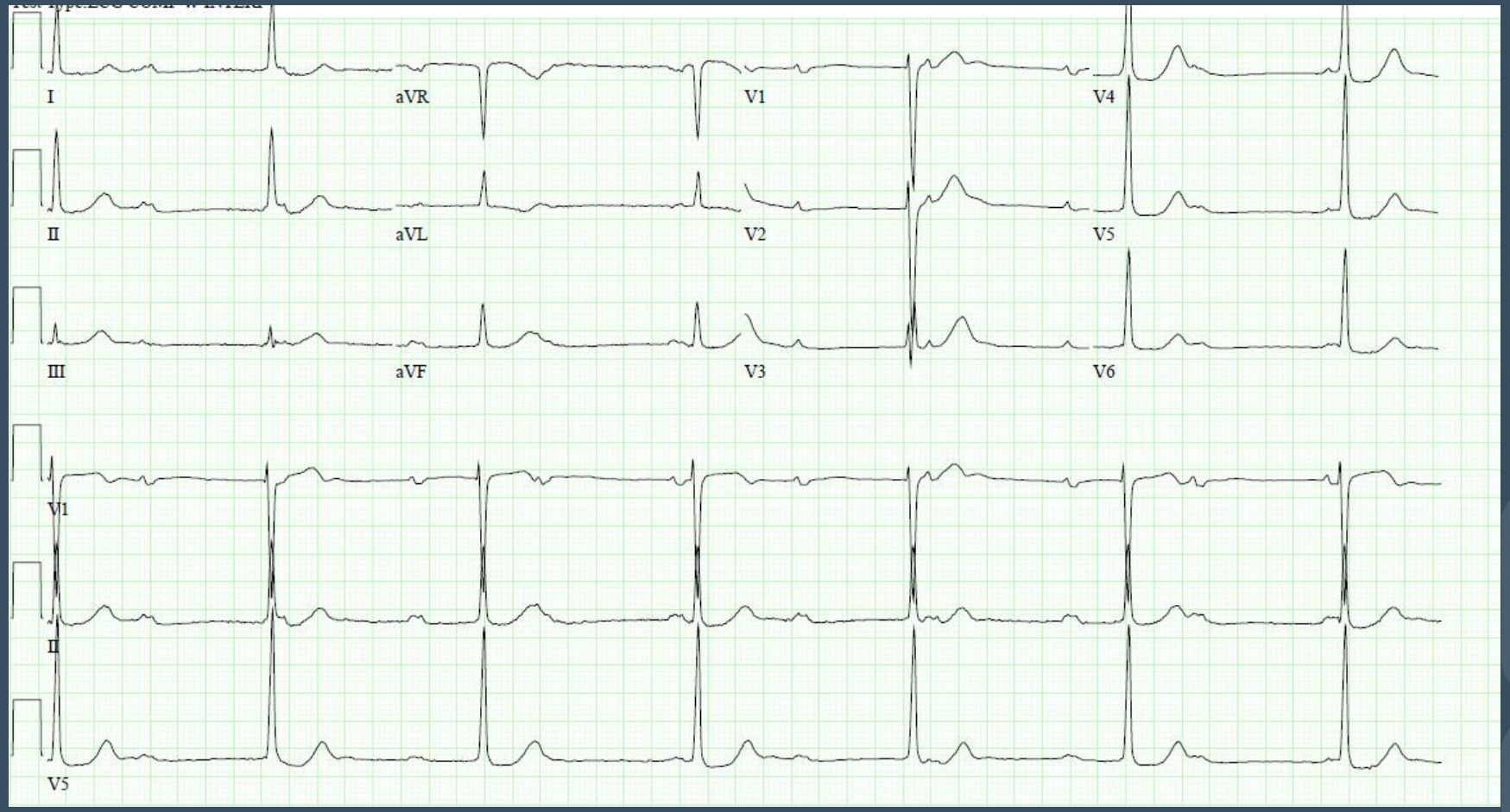

Case 4

68 year old ; BMI 28kg/m2
HTN on Lisinopril
Intermittent Palpitations
Given atenolol 100/d

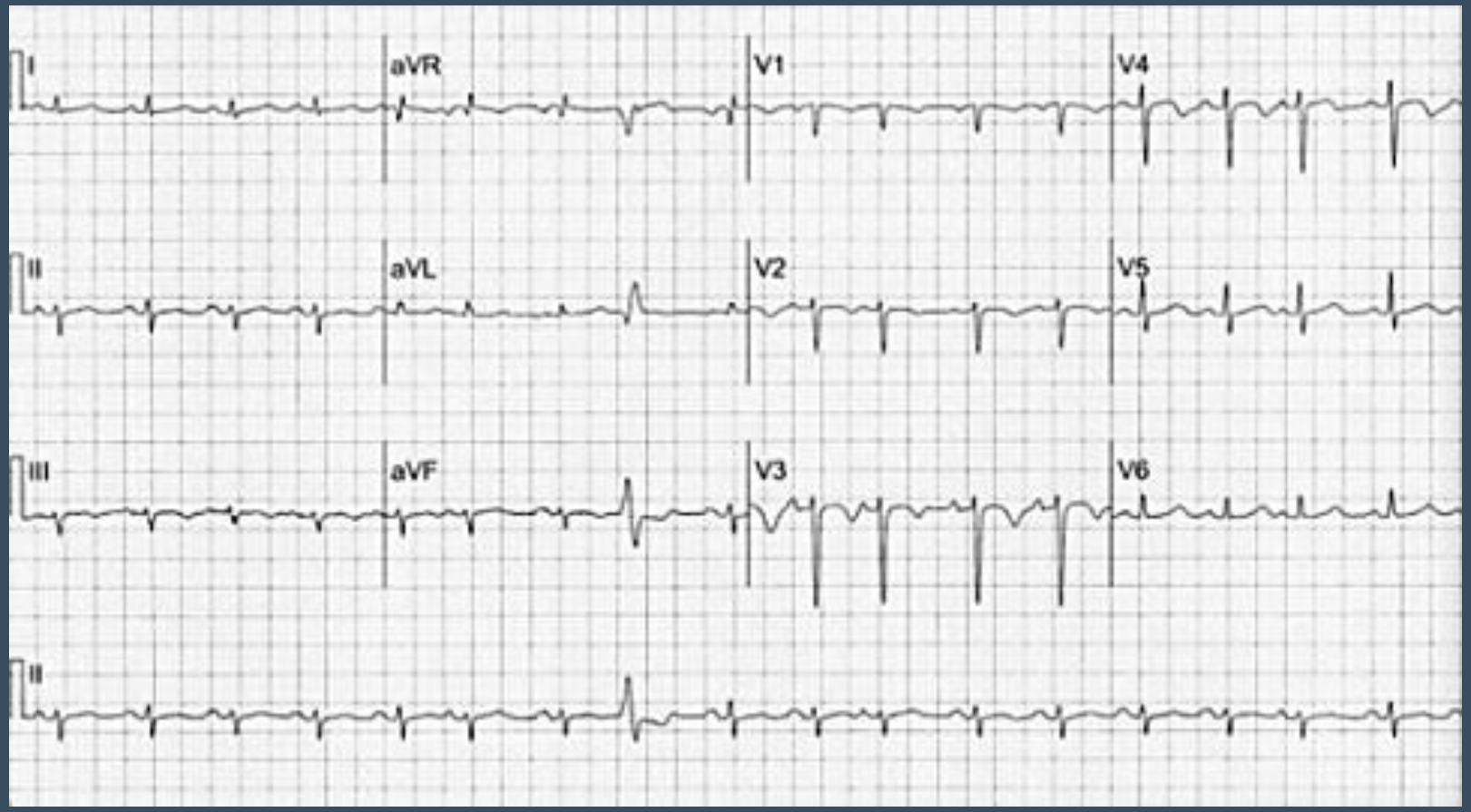

Infrequent dizziness upon getting up from a sitting position

Case 4

Holter:
Intermittent episodes of….
Dizziness at 11: 00am correlated with SR at 95bpm

Holter

Case 5

19 year old male athlete
Asymptomatic
Coming for check up: Told he had “irregular pulse”.

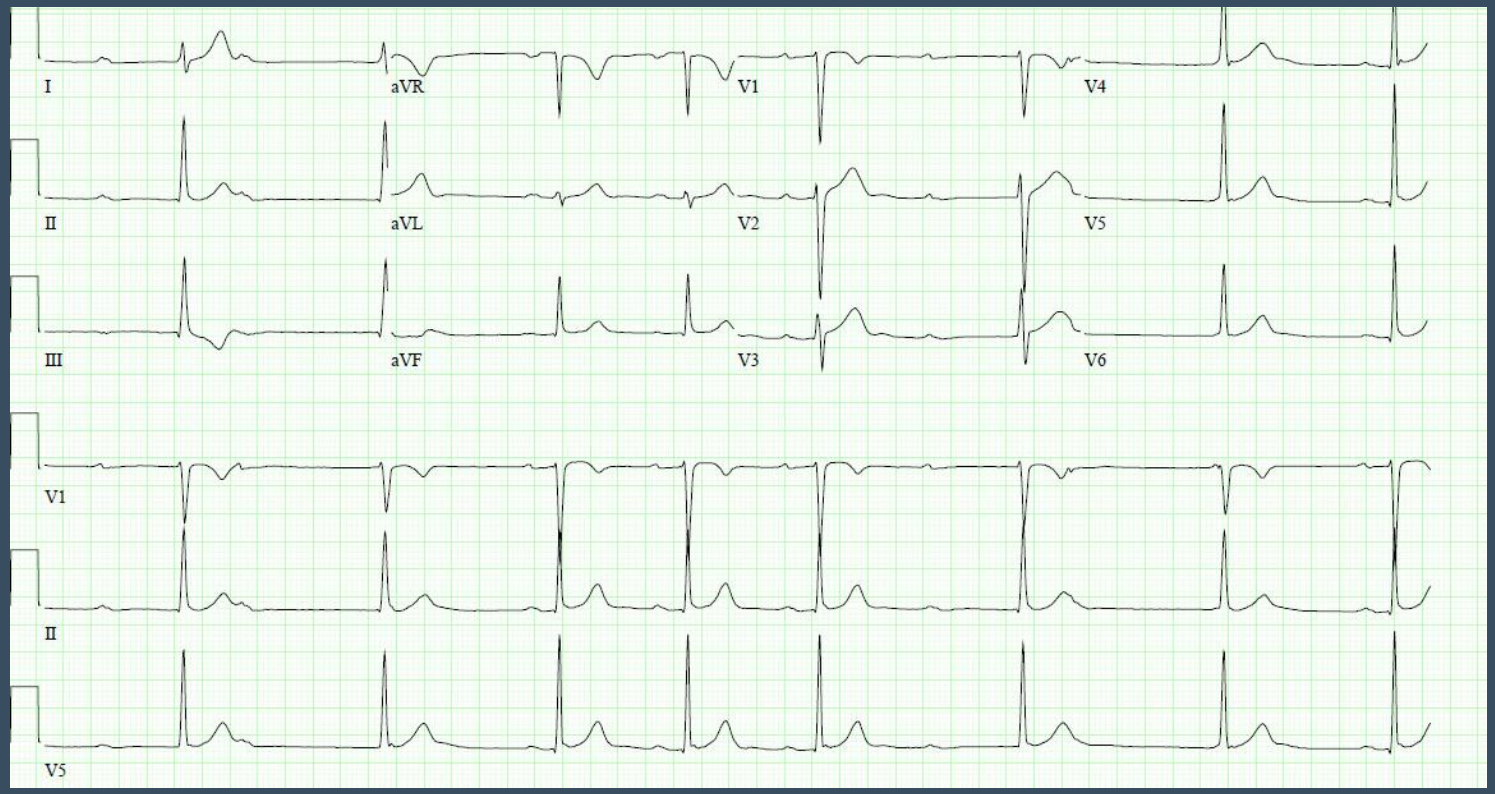

Case 6

- 56 year old
- Infrequent Parox AF with dizziness
- ASA and Metoprolol 25 mg bid.
- Normal LVEF, Normal Stress 90% THR
- MCOT to evaluate AF burden
- No syncope/presyncope

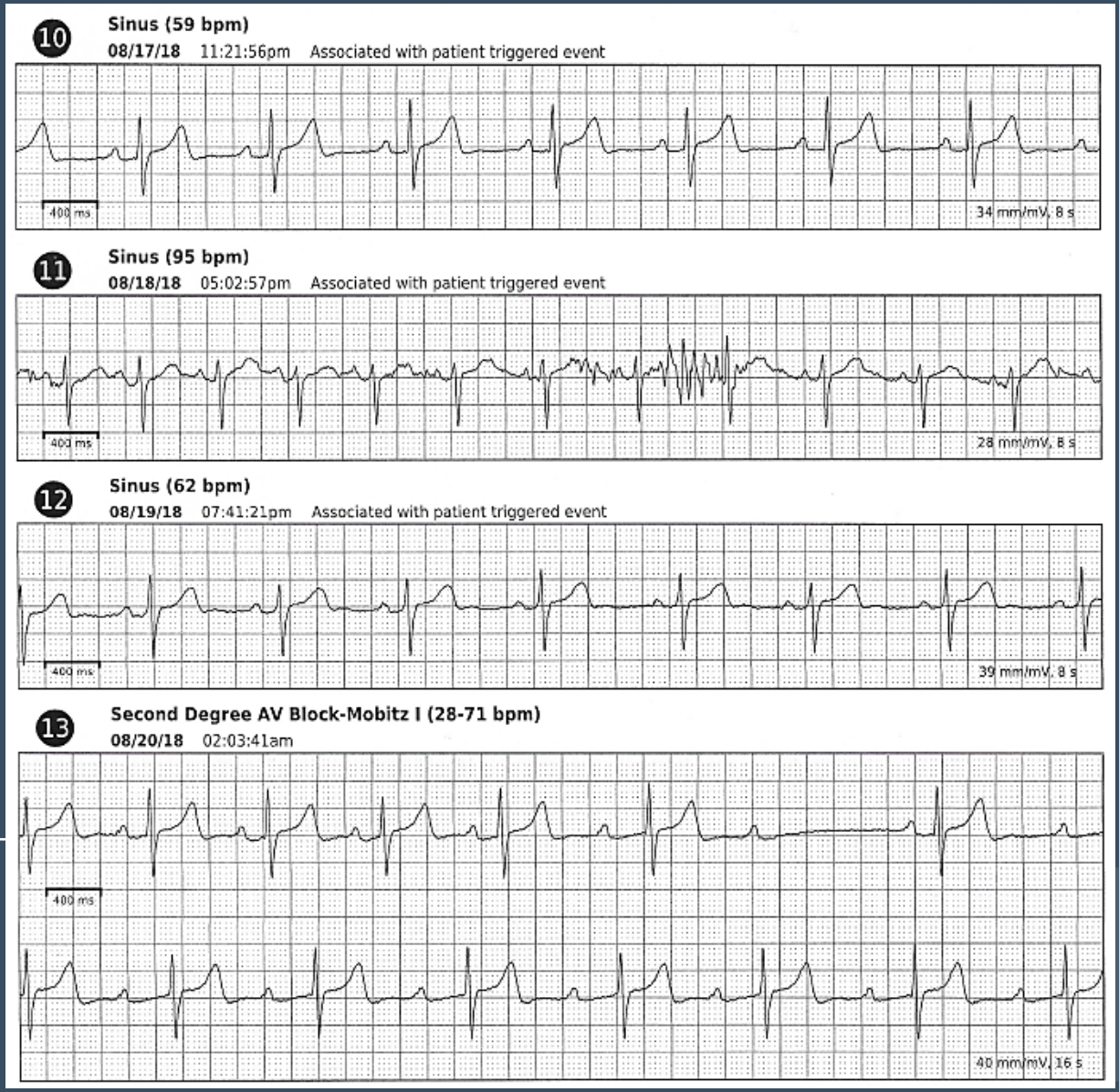

AV Block

1. Should you be concerned?
2. Stop BB?
3. Reassurance

Paroxysmal AV block

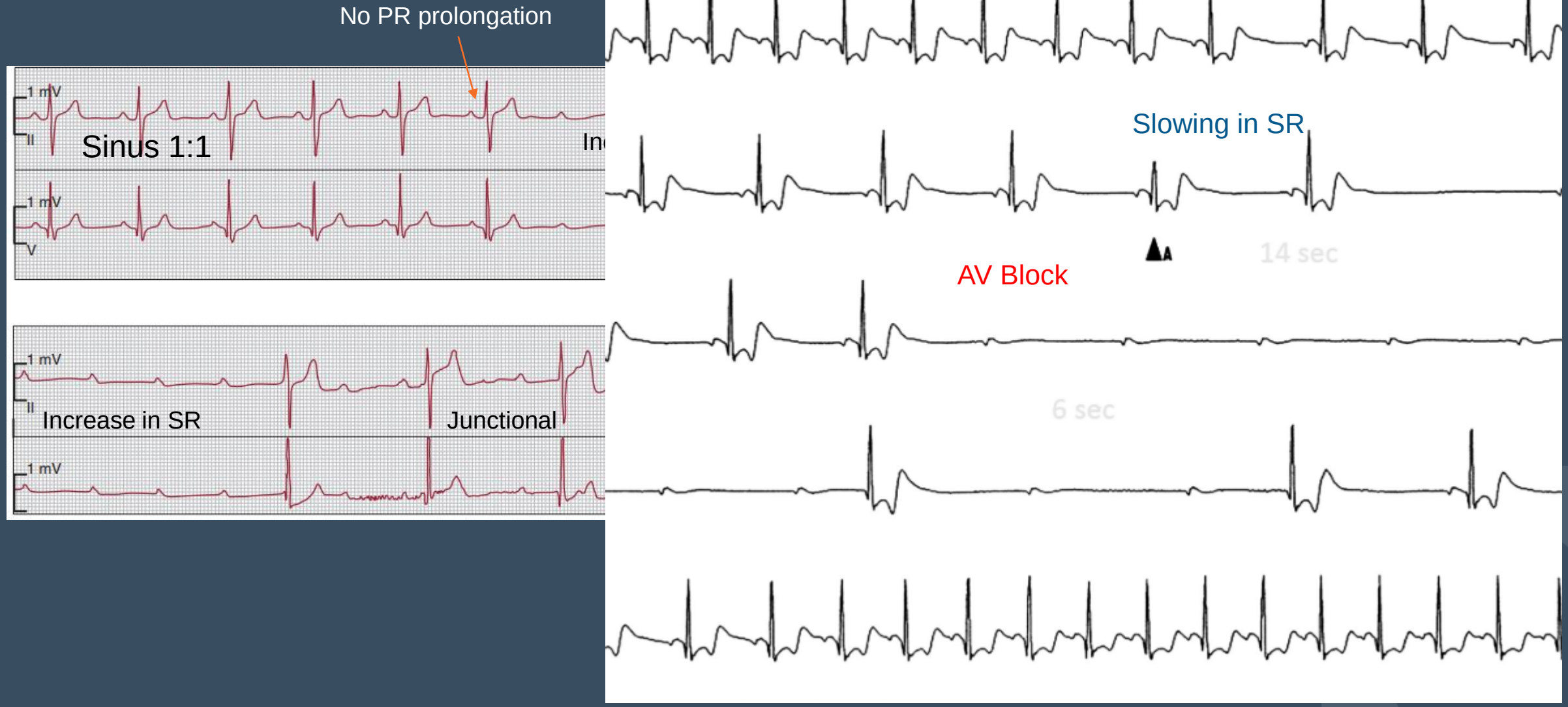

Case 7

68 year old female s/p liver transplant, intubated in the ICU, s/p tracheostomy
We are called to evaluate recurrent pauses for possible Pacemaker placement

1. Mobitz type I block
2. Post conversion pause
3. Vagal mediated block
4. Sinus node exit block

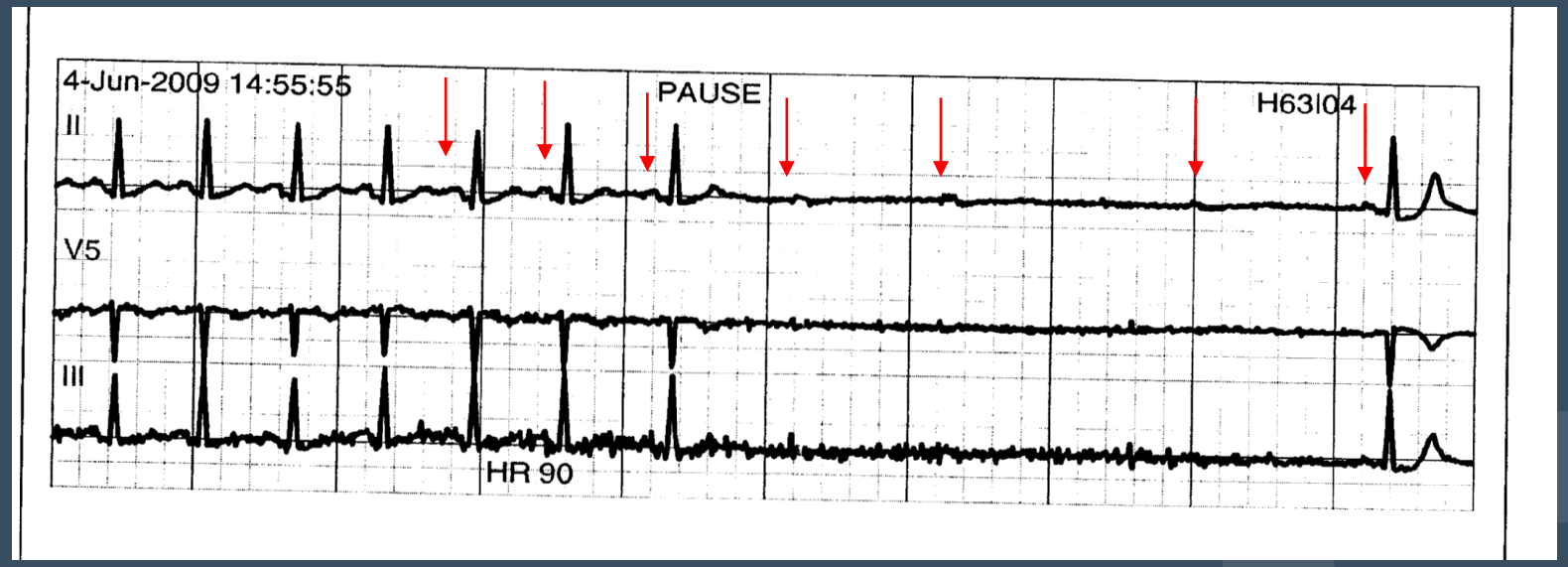

Case 8

70 year old with intermittent dizziness

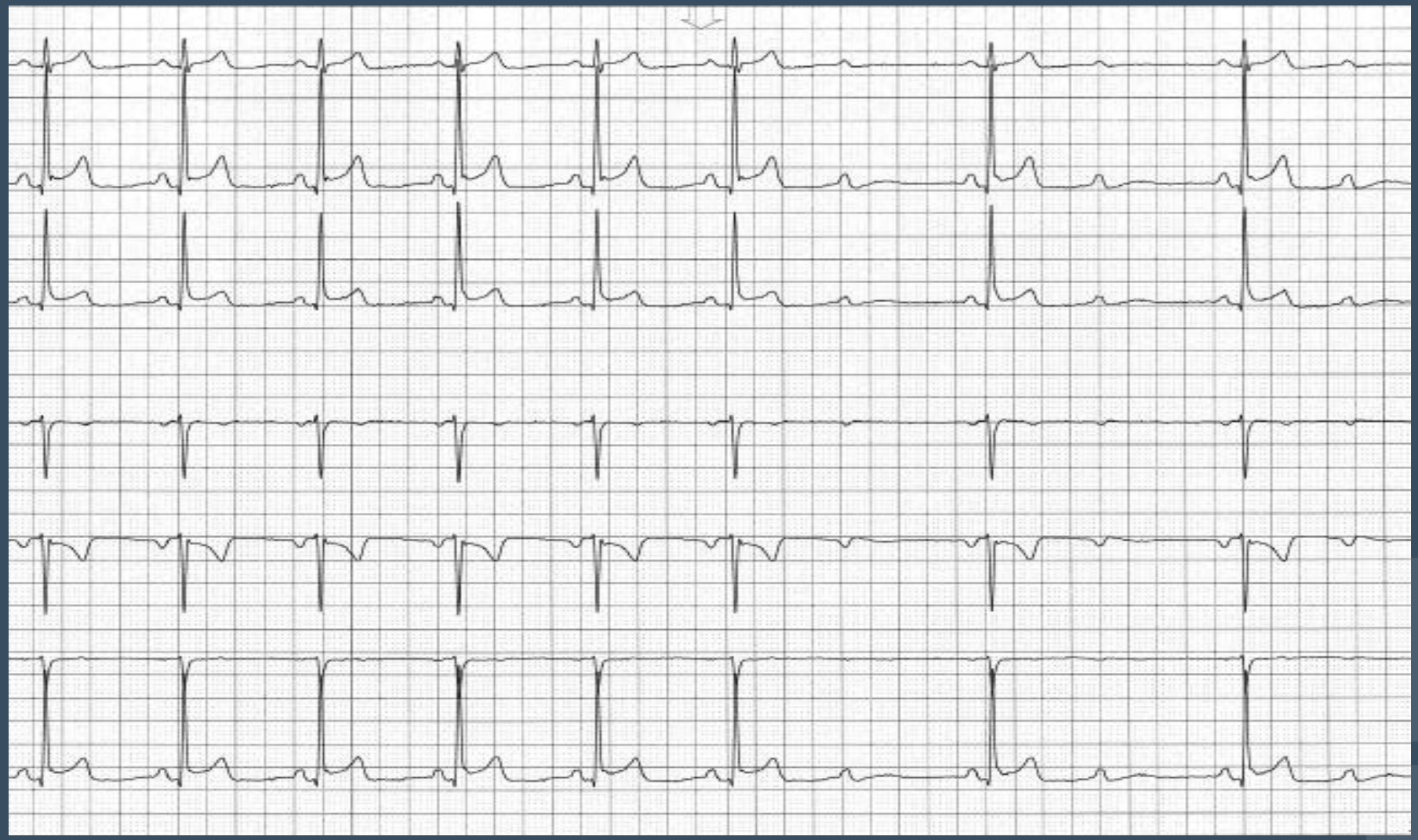

EP STUDY

- Risk of AVB in patients with conduction diseases

• HV < 55 ms	4%
• HV ≥ 70 ms	12%
• HV ≥ 100 ms	24%
• Pacing dependent infranodal block	High
• Pharmacologic HV ≥ 120 ms	Uncertain
• Syncope, -ve EPS with ILR implantation	One third

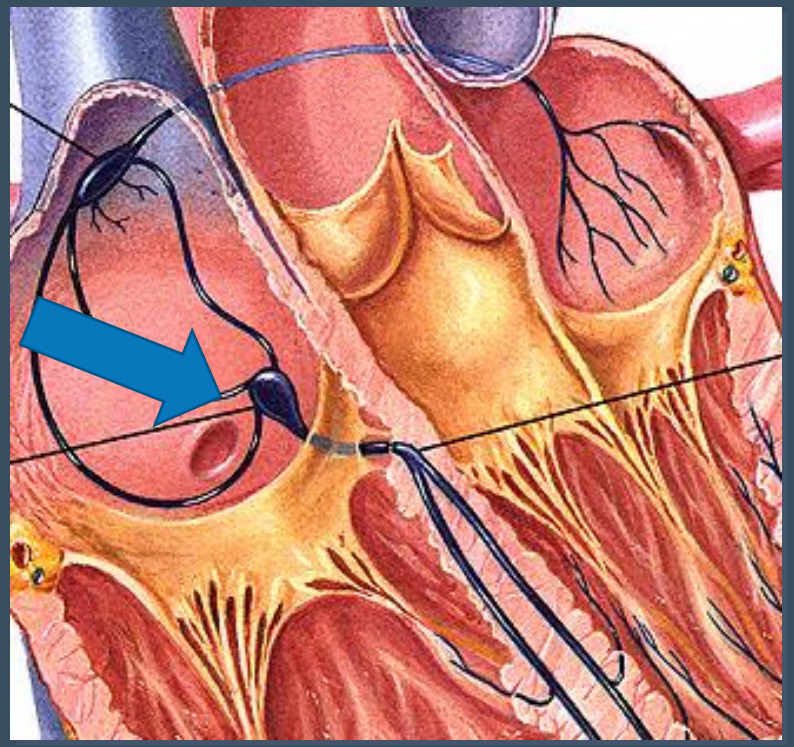

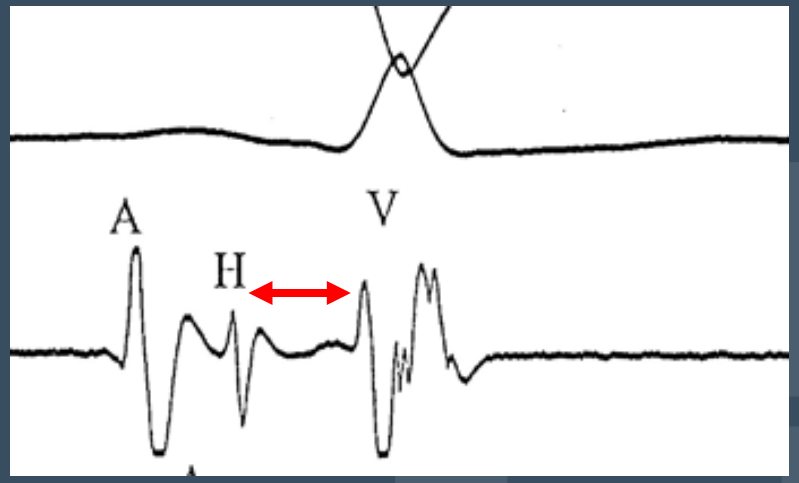

Baseline Intervals

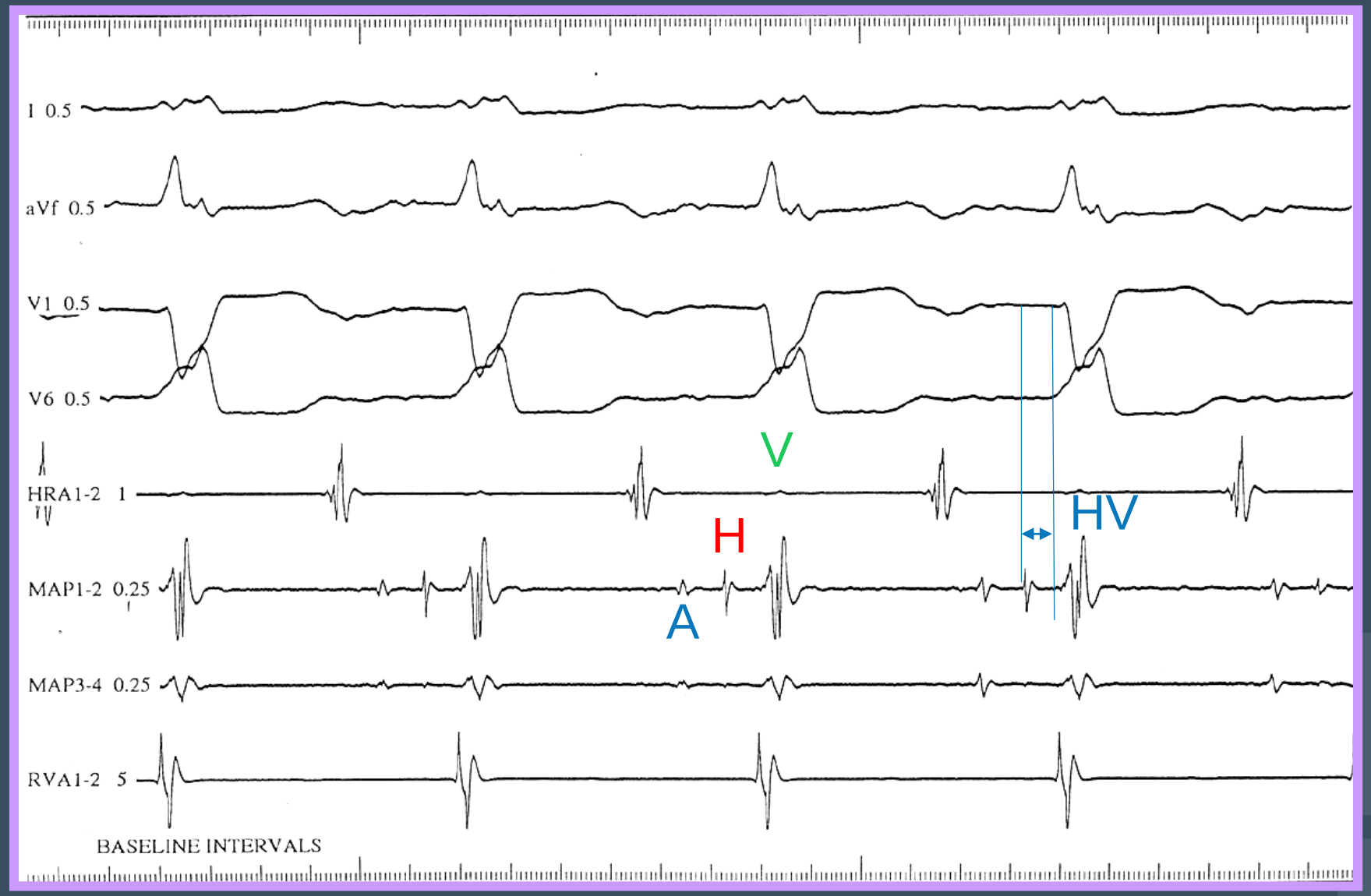

Case 8

Where is the site of block on this tracing?

1. **AV node**
2. **Infra His**

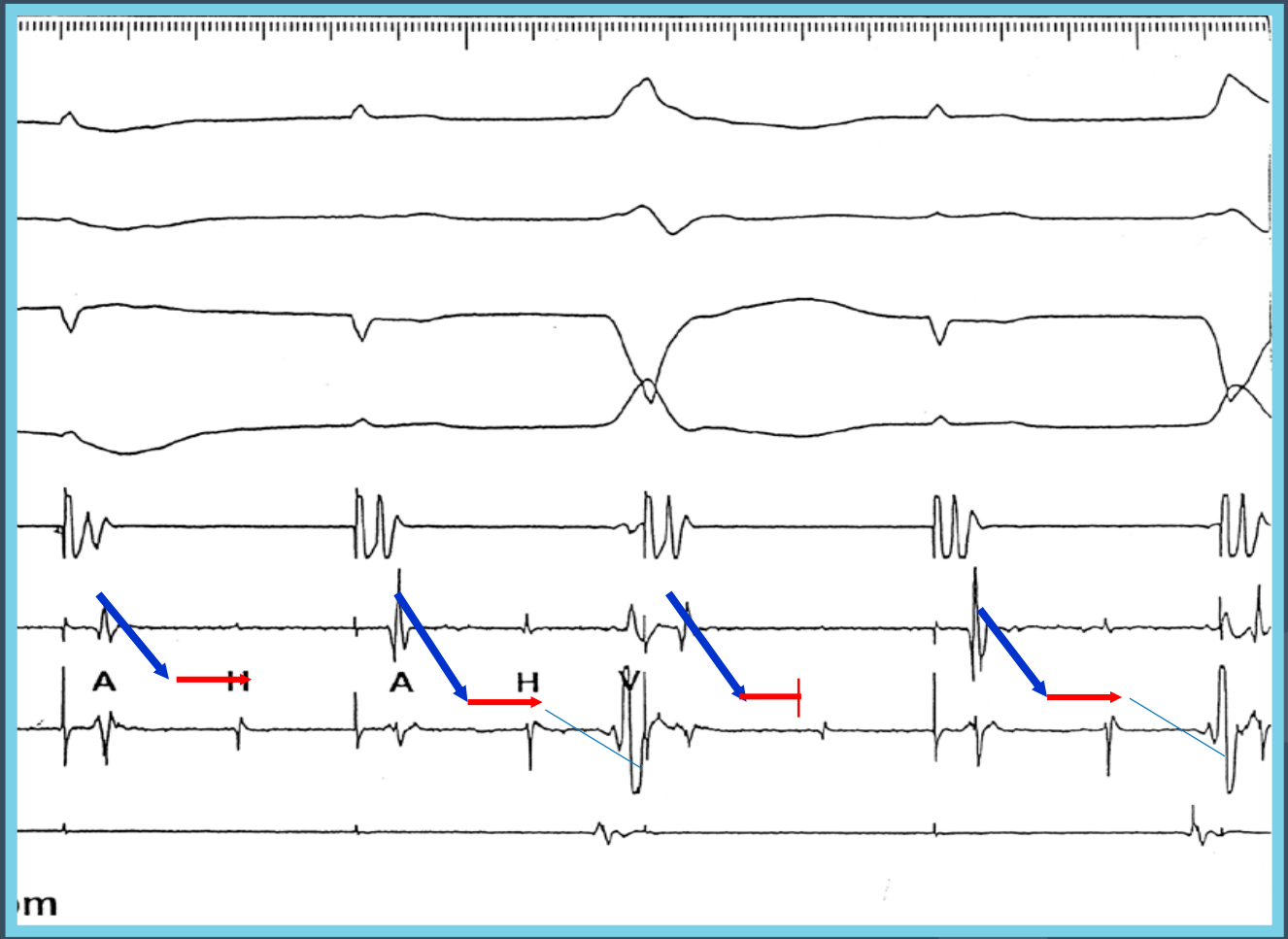

Case 9

- 45 year old female with several months history of palpitations, “bradycardia” and exercise intolerance; not feeling well. No syncope.
- No prior history of heart disease.
- Diagnosed with “Afib” and paroxysmal AV block and advised PPM placement and AAD therapy.
- Echo: Normal
- Other work up:
  - CT scan of chest normal.
  - Cardiac MRI Normal.

EKG #1 in the office

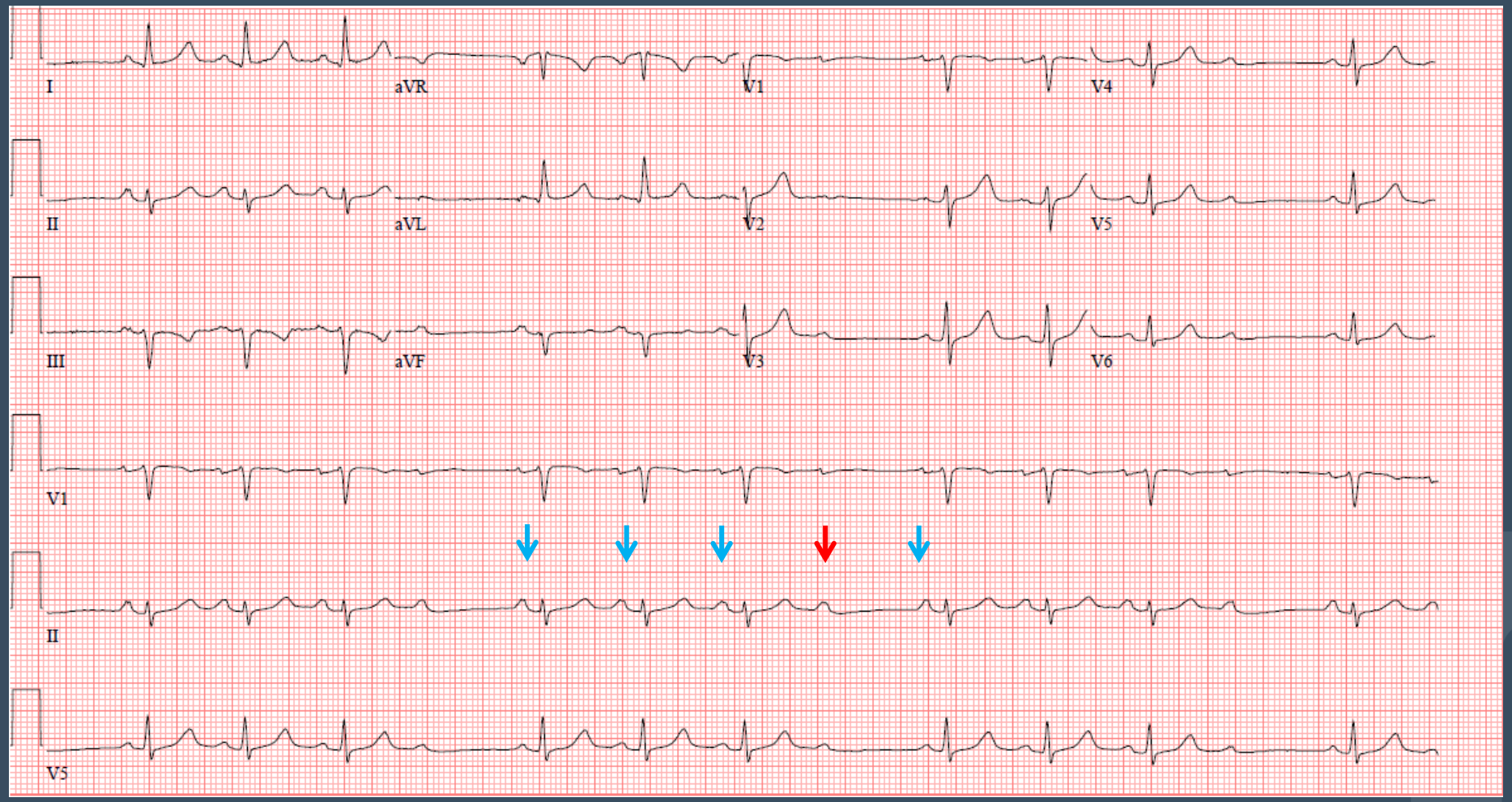

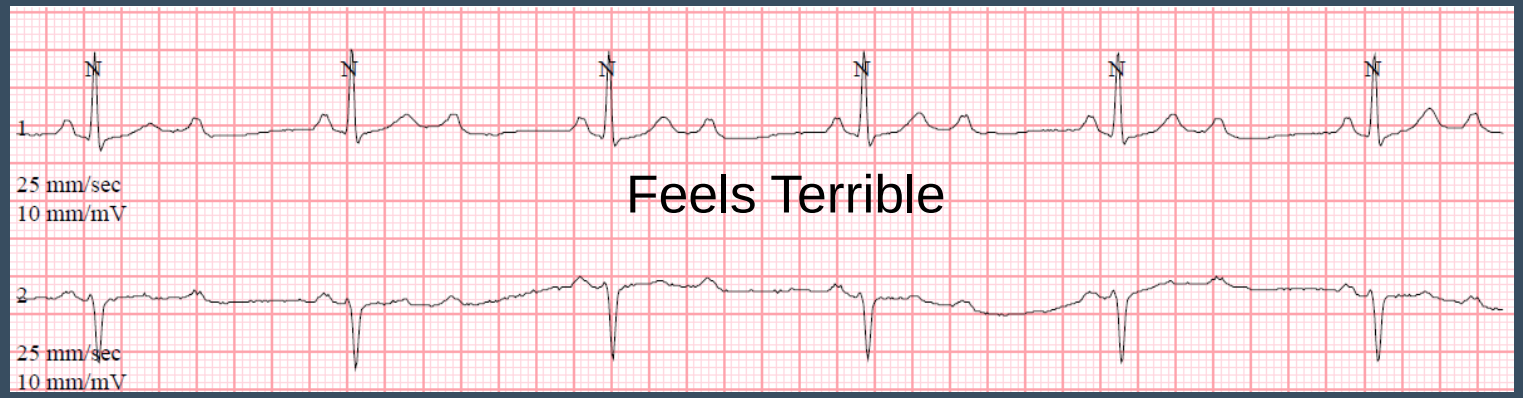

2:1 AV block ?

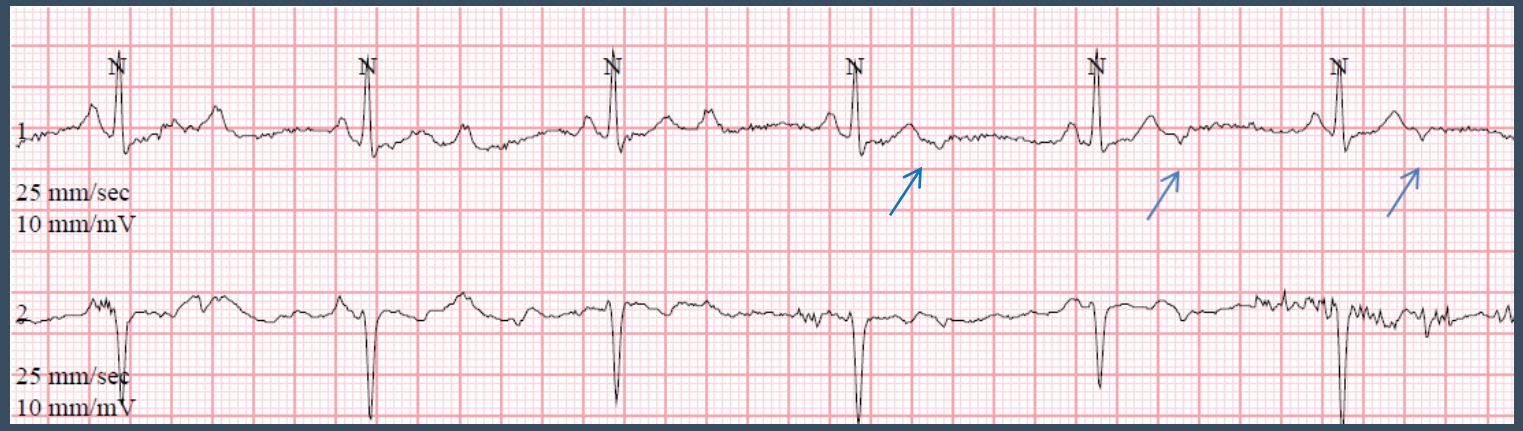

2:1 AV block with ?PAC's

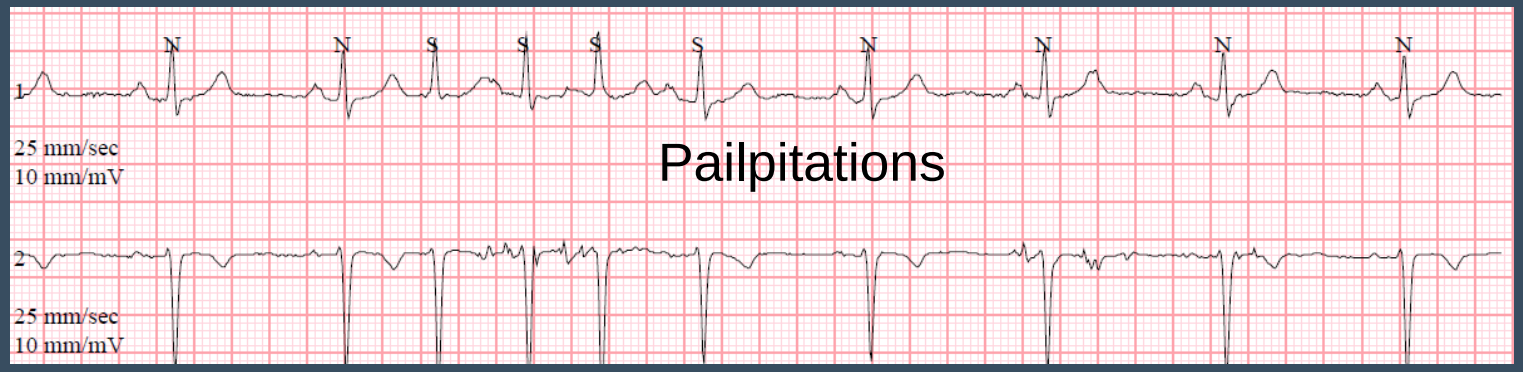

"Parox AF" ?

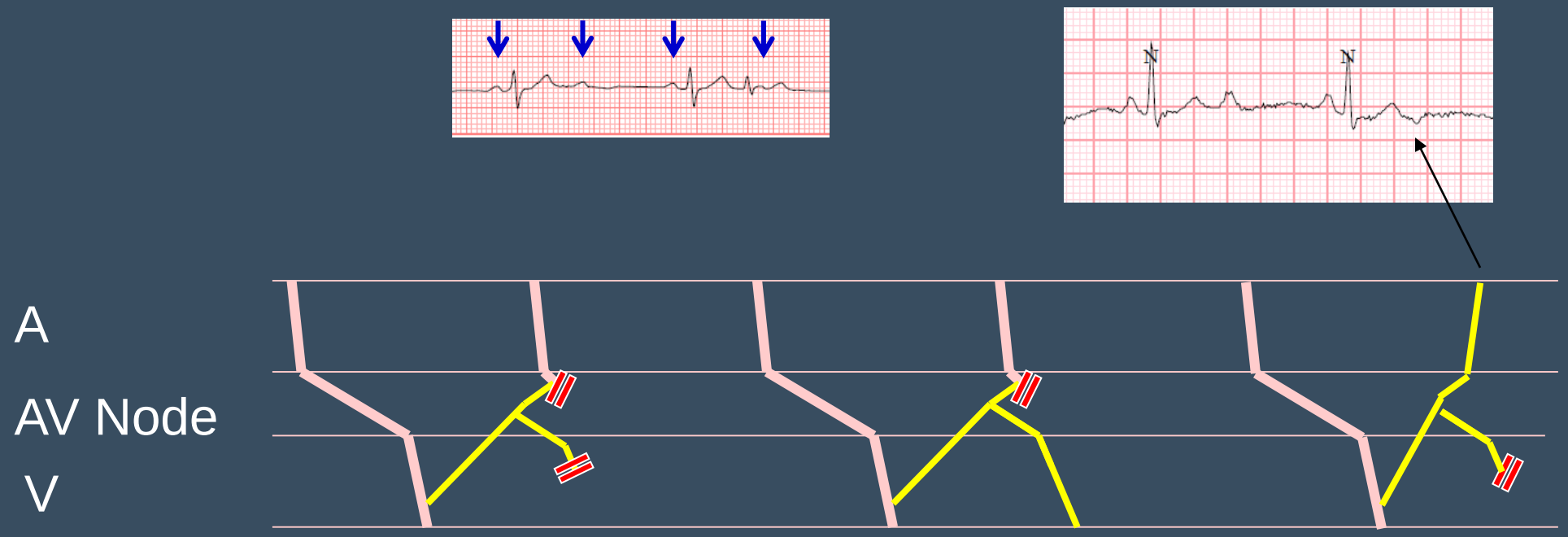

Presence of nodoventricular accessory pathway with retrograde conduction

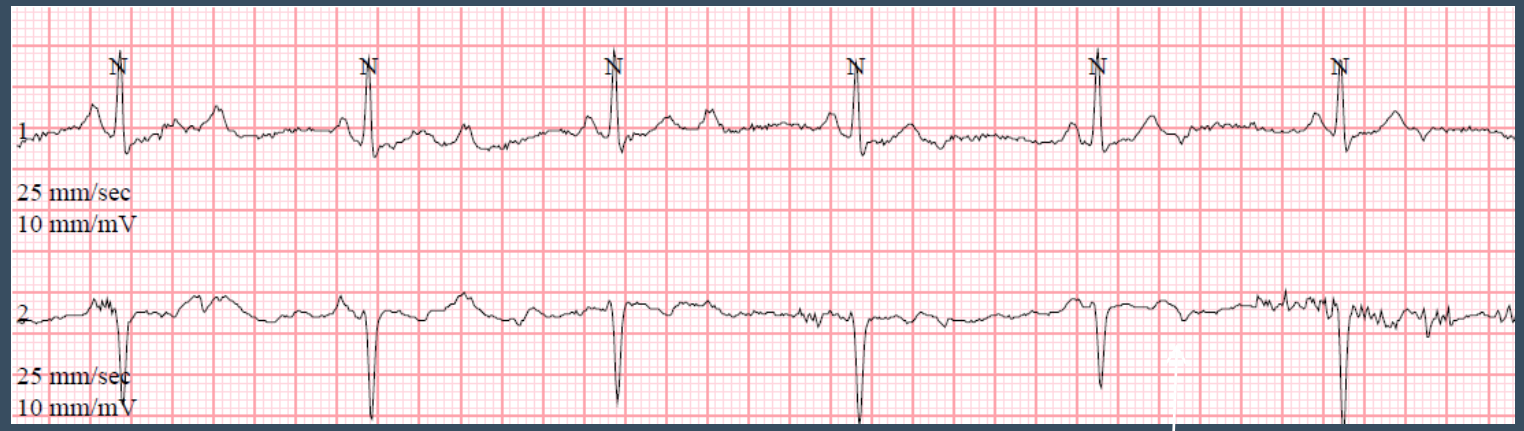
N
N
N
N
N
N
1
25 mm/sec
10 mm/mV
2
25 mm/sec
10 mm/mV

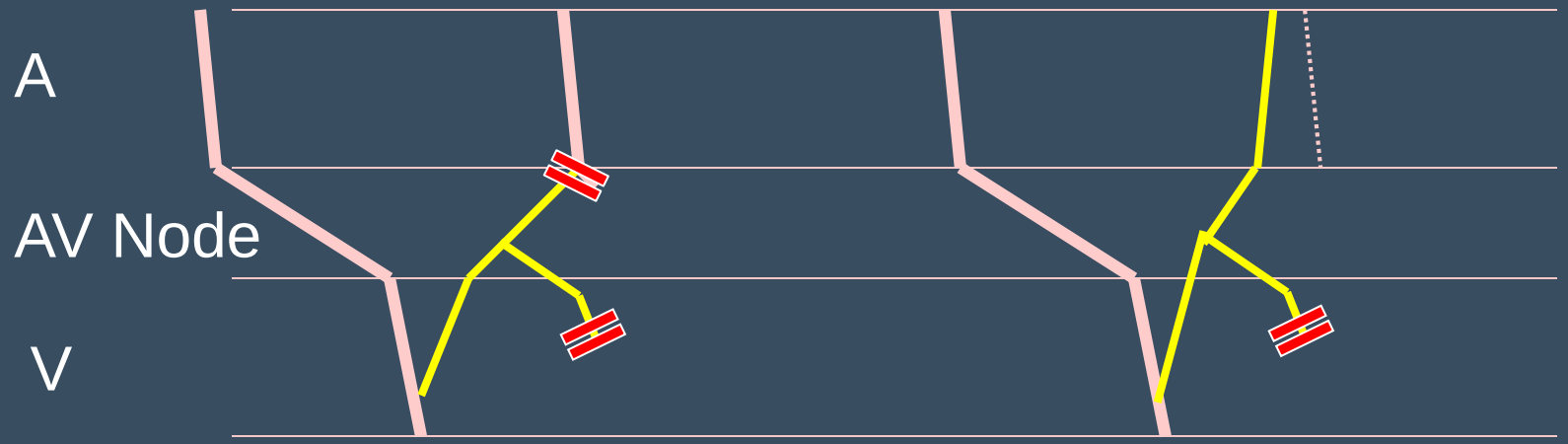
A
AV Node
V

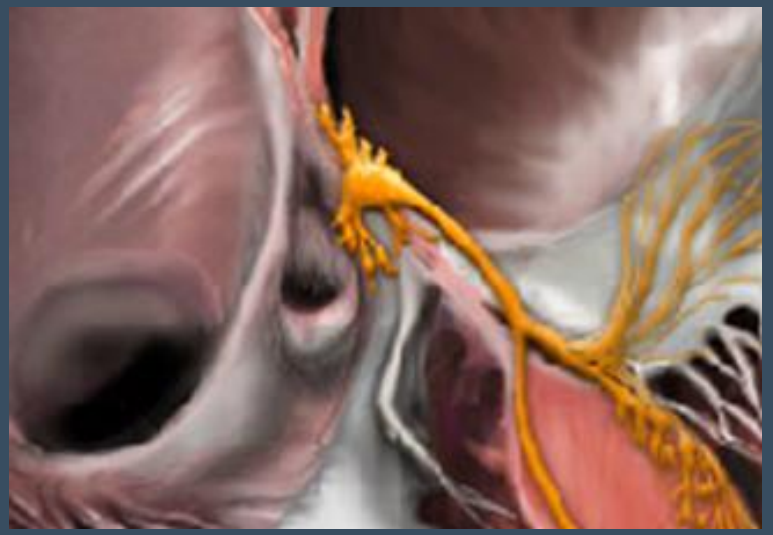

A case of AV block treated with Ablation