

Chapter 1: Surgical anatomy of the aortic and mitral valves

Jordan RH Hoffman MD, David A. Fullerton MD, FACC

University of Colorado School of Medicine, Department of Surgery, Division of Cardiothoracic Surgery, Denver, Colorado

Introduction

The central role of the mitral and aortic valves is to prevent the regurgitation of blood flow during the cardiac cycle. When either valve fails through stenosis, regurgitation, or the combination of both, the complexity of these structures become fully apparent. Given the conical nature of the left ventricle, intact and functioning aortic and mitral valves are essential to overall cardiac function. However, because these valves are intimately associated with each other, pathology is often coexistent.

Aortic Valve

Outflow Tract and Aortic Valve Annulus

The ventriculo-aortic junction is the convergence of the left ventricle and aorta. It is anatomically demarcated by the aortic valve annulus. While, unlike the mitral and tricuspid valves, there is no true aortic annulus, this structure can be thought of as a “virtual” ring represented by the junction of the left ventricular outflow tract (LVOT) and the aortic root (Figure 1) [1]. In surgical practice, the annulus is located at the nadirs of the aortic valve leaflet attachments and represents the area of smallest diameter in the ventriculo-aortic junction. Thus, the dimensions of the annulus have clear implications for prosthetic valve sizing and position.

During surgical aortic valve replacement, the native valve leaflets are excised and a prosthetic valve sizer is used to measure dimensions at the level of the annulus. A suitable prosthetic valve is then chosen using these measurements and the valve is anchored to the aortic root by sutures placed circumferentially through the aortic annulus. A key anatomical relationship is that portions of the noncoronary and left coronary cusps are in continuity with the anterior leaflet of the mitral valve (aorto-mitral valve curtain); an important consideration during combined valve replacement as well as during aortic root enlargement procedures.

The LVOT represents the caudal most aspect of the ventriculo-aortic junction and is anatomically indistinguishable from the left ventricle. The LVOT is demarcated by the interventricular septum anteriorly, and the anterior mitral leaflet posteriorly. Separating the inflow of blood from the left atrium from outflow of blood through the aortic valve is the anterior mitral valve leaflet. Imaging during transcatheter aortic valve replacement (TAVR) requires precise identification of the LVOT as a deeply placed aortic valve can limit mitral valve movement and subsequently limit flow of blood into the left ventricle.

The LVOT can be imaged distinctly by echocardiography as a continuity of the interventricular septum with the anterior wall of the aorta and a continuity of the mitral valve with the posterior wall of the aorta (Figure 2).

Aortic Root

The aortic root rests in the epicenter of the heart and is made up of the aortic valve leaflets with their attachments, three interleaflet triangles, the sinuses of Valsalva, and the left and right coronary ostia. The aortic root is demarcated inferiorly by the aortic annulus and superiorly by the sinotubular junction (Figure 3).

The aortic valve is a tri-leaflet valve composed of three cusps without a true fibrous skeleton. Aortic valve cusps are made up of a fibrous core with an endothelial lining. Each aortic valve cusp has a basilar attachment to the ventricular myocardium in the LVOT. Together, the outline of the valve leaflets as they attach to the sinus of Valsalva forms a “crown-like ring” (Figure 3) [2]. The base of the leaflets (i.e. the point of attachment to the aorta) is approximately 1.5 times as long as its free margin.

Between each valve leaflet is a bare area termed the interleaflet triangle, which is an upward extension of the left ventricular outflow tract formed by thinned aortic wall rather than ventricular myocardium [1,2]. A line drawn through the peak of the three interleaflet triangles defines the sinotubular junction (Figure 3). The interleaflet triangle formed between the right and non-coronary cusp is part of the “central fibrous body,” which represents the convergence of the two atrioventricular valves with the aortic valve. Additionally, below the same interleaflet triangle lies the membranous interventricular septum, bisected by the septal leaflet attachment of the tricuspid valve (Figure 1) [3]. Adjacent to this attachment sits the atrioventricular (A-V) node, located between the coronary sinus and interatrial septum. The A-V node gives off the bundle of His, which pierces the membranous interventricular septum and divides into the right and left bundle branch. Given the proximity of the conduction system to the inferior border of the aortic valve, a larger profile or deeply placed valve can cause new onset conduction disturbances [4].

In patients with normal anatomy, the ostia of the coronary arteries originate from the two anterior sinuses of Valsalva. The location of their origin is variable, and they can arise anywhere from 9 to 20 mm from the nadir of their respective valve cusp [2]. Accurate pre-procedure cross-sectional imaging is essential to define a patient’s coronary anatomy and coronary ostial location with respect to the base of the valve cusp.

Sinotubular Junction

The sinotubular junction (STJ) is defined by a thickened rim of aortic tissue called supra-aortic ridge. Anatomically, the STJ is the superior aspect of the sinuses of Valsalva and the transition from aortic root to ascending aorta. The STJ is represented by an imaginary line drawn through the apex of each interleaflet triangle (Figure 3). The diameter of the STJ is about 15-20% less than that of the base of the aorta. Along this imaginary line lie the aortic valve commissures, which is where the semicircular edge of the three aortic valve cusps coalesce to connect the apex of one valve leaflet to its neighboring valve leaflet [5]. The commissures are equally spaced around the circumference of the sinotubular

junction and provide strong support for the aortic valve cusps during the cardiac cycle, transmitting stress into the wall of the aorta. Clinically they are important because they act as markers for orientation of a prosthetic valve during surgical aortic valve replacement.

Mitral Valve

The mitral valvular complex comprises the annulus, the anterior and posterior valve leaflets, and the subvalvular structures which include the tendinous cords and papillary muscles. The left atrium and left ventricle play important roles as the foundation to which the mitral valve is secured. All structures within the mitral valve complex must function in union for valvular coaptation to occur, lest mitral regurgitation develop.

Left Atrium and Ventricle

The boundaries of the mitral valve are formed by the aortic annulus and aortic-mitral curtain anteriorly, and the muscular attachments of the left atrium posteriorly at the atrioventricular (AV) junction. These confines form the basis for the shape of mitral valve contour (Figure 5).

While the stiff aortic-mitral curtain prevents movement of the attachment point of the anterior leaflet, it has been suggested that left atrial stretch can displace the posterior leaflet, interrupting valve leaflet coaptation, eventually leading to mitral regurgitation [6,7]. Similarly, given the attachment of the valve leaflets to the left ventricular free wall, changes in compliance or geometry of the left ventricle can lead to alterations in flow dynamics through the mitral valve via the valve leaflet attachments with the tendinous cords and papillary muscle [8].

Mitral Valve Annulus

The mitral valve annulus is a tangible structure representing the left AV junction. The annular perimeter takes the shape of a “D,” with the linear edge being formed by the stiff aortic-mitral curtain and the curvilinear edge conforming to the highly pliant muscular attachments of the left atrium (Figure 5) [8,9].

The aortic-mitral curtain is a fibrous thickening separating the aortic valve leaflets from the mitral valve proper. On either end of the aortic-mitral curtain is a triangular junction of fibrous tissue known as the right and left fibrous trigones (Figure 4 & 5). Fibroelastic cords extend from aortic-mitral curtain, through the fibrous trigones, and partially surround the posterior mitral leaflet forming what is known as the mitral valve annulus. Because the posterior annulus is incomplete in most patients, there is a tendency for annular dilation and calcification to occur in this area, resulting in disfigurement of the mitral valve orifice and consequent pathology [8-10].

Mitral Valve Leaflets

The backflow of blood is prevented by two mitral valve leaflets, which are histologically trilaminar and covered with an endothelium. These leaflets are given the designation of anterior (or aortic)

and posterior (or mural), and are used to describe the position of the mitral valve leaflets within the heart (Figure 5) [9].

The anterior leaflet, which is larger in the AP diameter and more sail-like, occupies approximately one-third the circumference of the annulus while the posterior leaflet, which is smaller in the AP diameter and more rectangular-shaped, occupies the remaining two-thirds of the circumference. Given the redundancy of mitral valve tissue, each leaflet appears to have three scalloped segments which are termed A1, A2, A3 (anterior leaflet, from lateral to medial), and P1, P2, P3 (posterior leaflet, from lateral to medial). These redundant segments are most important for accurate coaptation of the valve.

At the ends of the line of coaptation between the anterior and posterior valve leaflet, lie the anterolateral and posteromedial commissures. These are not true commissures, since the line of leaflet coaptation does not actually extend to meet the annulus. Accessory leaflet tissue, termed the commissural leaflet, is found in this location (Figure 6) [8-9].

Subvalvular Structures

The tendinous cords and papillary muscles make up the subvalvular structures tethering the mitral valve leaflets to the left ventricular free wall. The anterolateral, supplied by the left anterior descending artery and circumflex artery, and posteromedial papillary muscles, supplied by the posterior descending artery, are named after the commissures to which they project. Most patients have a single papillary muscle in the anterolateral position, while there are usually two or three distinct papillary muscles or a single papillary muscle with two or three muscle heads in the posteromedial position (Figure 6) [8-9].

Attaching the papillary muscles to the mitral valve leaflets are the multiple chordae tendineae. These are highly variable branching bands that insert broadly into the ventricular side of the valve leaflets. They are classified according to their site of insertion, with primary chordae inserting on the free margin of the leaflets and secondary chordae attaching on the ventricular side of the leaflets. To prevent anterior motion of the mitral valve, these cords, together with the papillary muscles, maintain constant posterior traction on the edges of the mitral valve leaflets [9].

Carpentier's functional classification of mitral valve disease describes valve dysfunction based on the malfunctioning opening and closing of the mitral valve leaflets. Type I dysfunction occurs because of annular dilation or leaflet perforation but retains normal leaflet motion. Type II dysfunction is a result of chordae or papillary muscle elongation or rupture and causes excess leaflet motion (leaflet prolapse). Type III dysfunction describes restricted opening / diastole (IIIa), or restricted closing / systole (IIIb). Type III lesions include leaflet or chordal thickening, commissural fusion, or ventricular aneurysm causing restricted valve motion [11].

Conclusion

Development of new valve technology has paralleled the growth in transcatheter therapies for functional heart disease. Newer transcatheter valves are now able to closely mimic the nuanced function of a patient's native heart valve, however, unlike transcatheter aortic valve replacement, the development

of transcatheter interventions for mitral valve pathology have progressed more slowly. In the case of mitral valve regurgitation, transcatheter technology has been delayed by challenges in the saddle-shaped geometry of the mitral annulus which often lacks a calcific landing zone. Nevertheless, mitral valve transcatheter technology is advancing rapidly.

During transcatheter valve placement, several radiographic landmarks act as surrogates for actual anatomic structures. A thorough understanding of the surgical anatomy and physiology is essential for completion of transcatheter procedures.

References

1. Charitos EI, Sievers HH. Anatomy of the Aortic Root: Implications for Valve-Sparing Surgery. *Ann Cardthorac Surg.* 2013; 2(1):53-56.
2. Piazza N, et al. Anatomy of the Aortic Valvar Complex and Its Implications for Transcatheter Implantation of the Aortic Valve. *Circulation.* 2008; 1:74-81.
3. Sutton JP, et al. The Forgotten Interleaflet Triangle: A Review of the Surgical Anatomy of the Aortic Valve. *Ann Thorac Surg.* 1995; 59:419-427.
4. Lee MY. Mechanisms of Heart Block After Transcatheter Aortic Valve Replacement- Cardiac Anatomy, Clinical Predictors and Mechanical Factors that Contribute to Permanent Pacemaker Implantation. *Arrhythm Electrophysiol Rev.* 2015; 4(2): 81-85.
5. Anderson RH, Wilcox BR. Understanding Cardiac Anatomy: The Prerequisite for Optimal Cardiac Surgery. *Ann Thorac Surg.* 1995; 59:1366-1375.
6. Perloff JK, Roberts WC. The Mitral Valve Apparatus. Functional Anatomy of Mitral Regurgitation. *Circulation.* 1972; 46:227-239.
7. Ho SY. Anatomy of the Mitral Valve. *Heart.* 2002; 88(iv):5-10.
8. Van Mieghem NM, et al. Anatomy of the Mitral Valvular Complex and Its Implications for Transcatheter Interventions for Mitral Regurgitation. *JACC.* 2010; 56(8):617-626.
9. Dal-Bianco JP, Levine RA. Anatomy of the Mitral Valve Apparatus- Role of 2D and 3D Echocardiography. *Cardiol Clin.* 2013; 31(2):1-23.
10. Angelini A, et al. A Histological Study of the Atrioventricular Junction in Hearts with Normal and Prolapsed Leaflets of the Mitral Valve. *Br Heart J.* 1988; 59:712-716.
11. Carpentier A, et al. Extensive Calcification of the Mitral Valve Annulus: Pathology and Surgical Management. *J Thorac Cardiovasc Surg.* 1996; 111:718-729.

Figure 1: The aortic valve annulus is a virtual ring represented by a line drawn through the nadirs of the aortic valve leaflets. The septal tricuspid valve leaflet bisects the membranous interventricular septum at the atrioventricular junction.

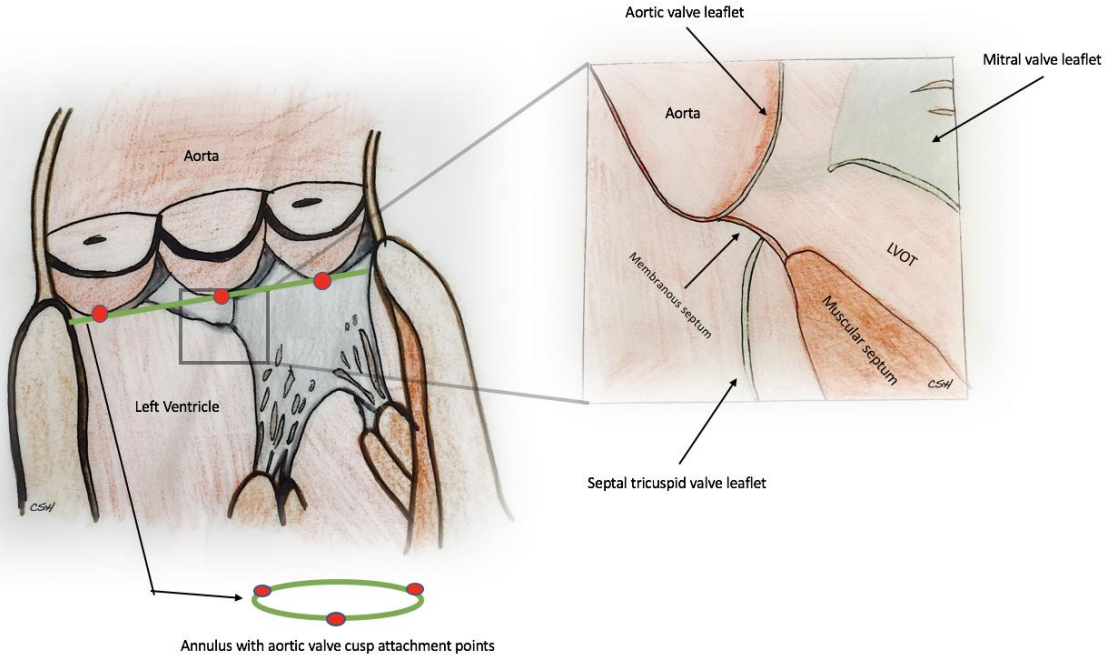


Figure 2: Left ventricular outflow tract as imaged by surface echocardiography. Note the continuity of the interventricular septum with the anterior aortic wall, and anterior mitral valve leaflet with the posterior aortic wall.

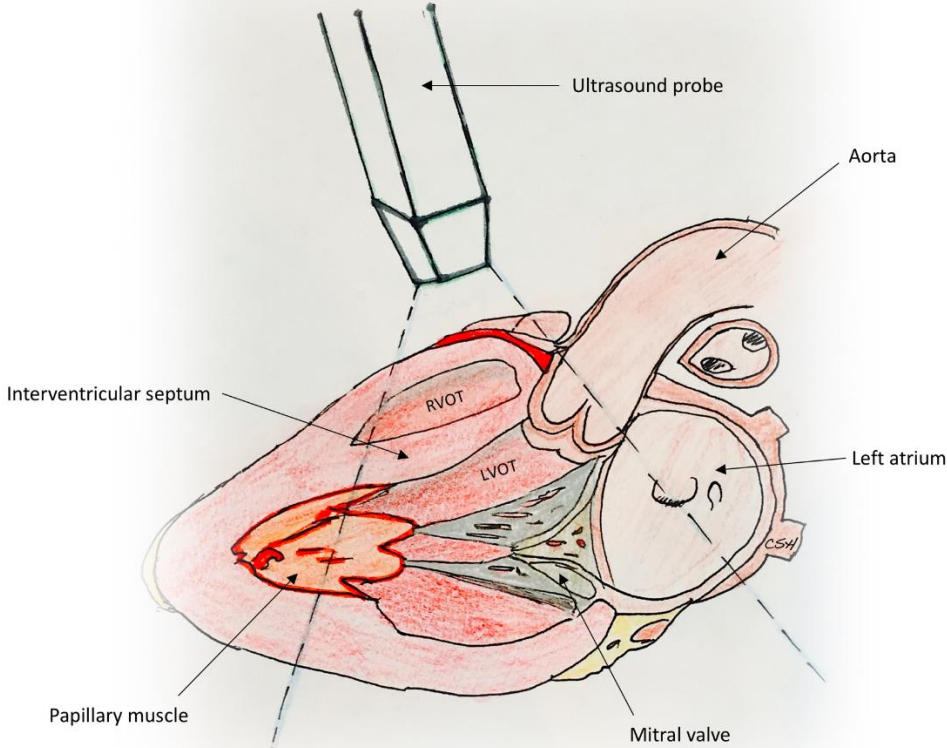


Figure 3: Anatomy of the aortic root. The contour of the aortic valve cusp resembles a “crown-like ring.” The aortic root is enclosed superiorly by the sinotubular junction and inferiorly by the aortic annulus.

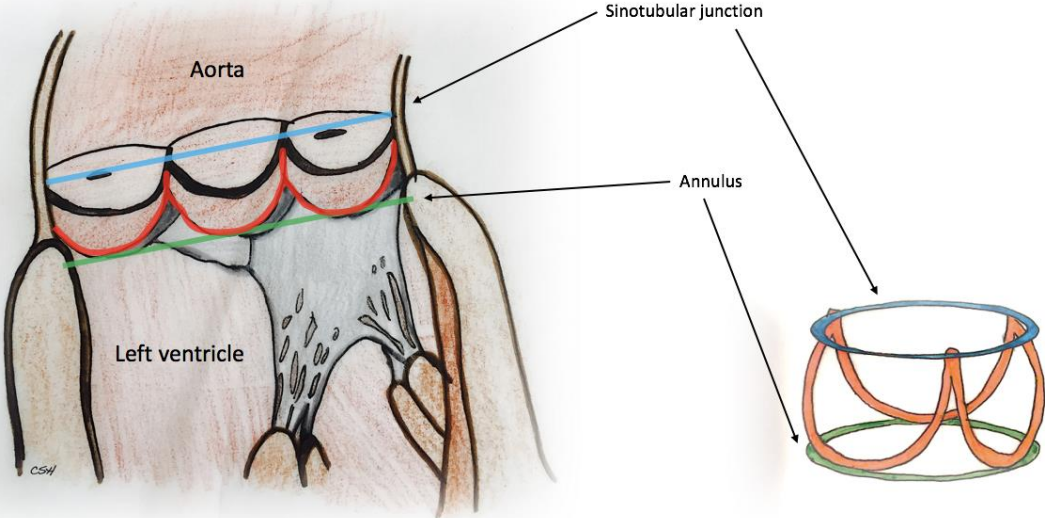


Figure 4: Anatomy of the interleaflet triangles and central fibrous body. Note the proximity of the aortic-mitral curtain, located between the right and left fibrous trigones.

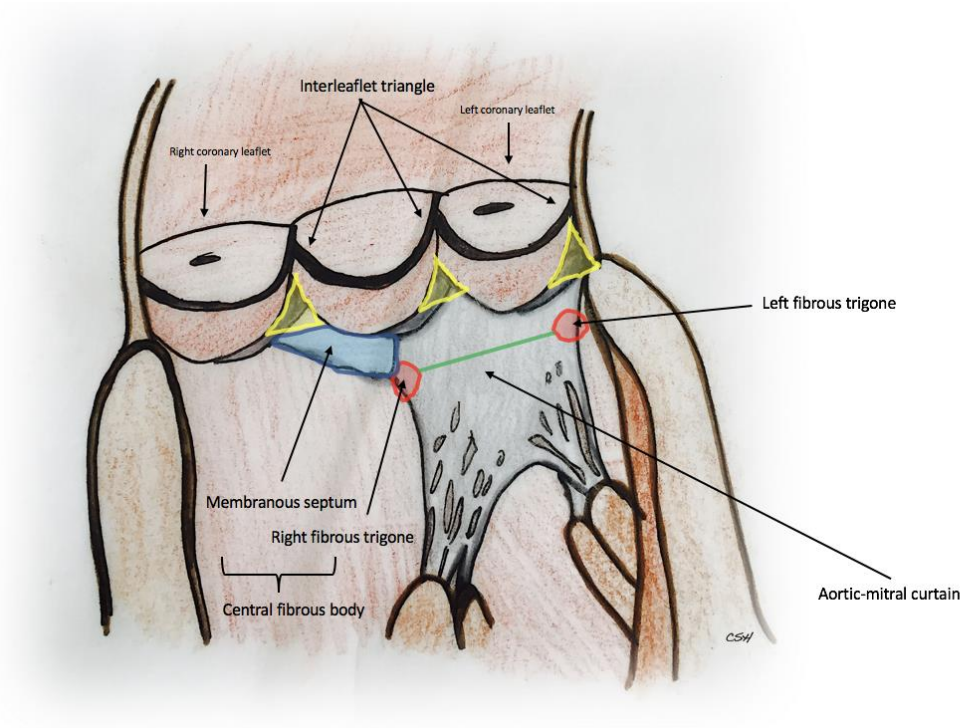


Figure 5: A superior view of the heart valves demonstrating the mitral valve annulus and its anatomic boundaries.

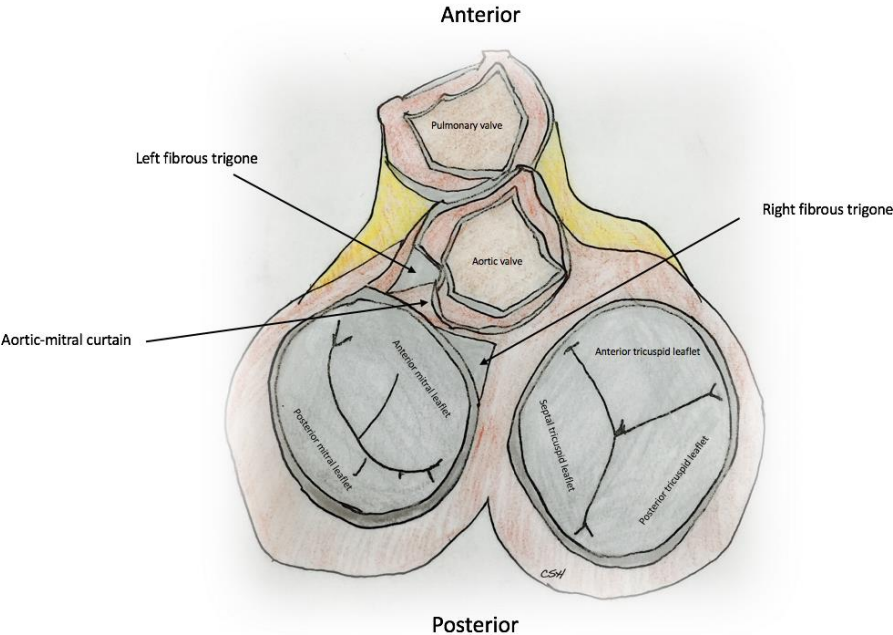


Figure 6: The unfolded mitral valve demonstrating the commissures and subvalvular attachments.

