

**Control Number:** 30

**Abstract Category:** Clinical Case Challenge in Cardio-Oncology

**Title:** Troponin Elevation during Treatment with Immune Checkpoint Inhibitors

## **ABSTRACT BODY**

### **Background and Purpose**

Cardiovascular assessment is challenging in patients with suspected immune checkpoint inhibitor (ICI) mediated myocarditis. The presentation is non-specific while a wide differential diagnosis needs to be considered. We present a case of an asymptomatic patient with troponin elevation and cardiac magnetic resonance image (MRI) abnormalities while on ICI therapy.

### **Case Description and Outcomes**

A 67-year-old man with metastatic gastroesophageal junction adenocarcinoma HER2 negative was enrolled in a clinical trial involving treatment with FOLFOX, Nivolumab (anti PD-1) and LAG 3 antibody. Past medical history was notable for hypertension and pre-diabetes; he was a current smoker. Trial protocol mandated surveillance with troponin I. Twelve days after his second cycle, his high sensitivity Troponin I increased to 31 ng/L from a baseline of 4 ng/L. He was asymptomatic. His ECG demonstrated a right bundle branch block with no change from baseline. The troponin elevation raised concern for ICI-related myocarditis. A cardiac MRI showed normal biventricular systolic function with diffuse late gadolinium enhancement suggestive of myocarditis with basal inferior edema versus an atypical appearance of ischemia. The trial monitors recommended steroids based on the MRI but we sought to confirm the diagnosis before treatment. Thus, urgent endomyocardial biopsy and coronary angiography were requested. This revealed critical multi-vessel disease with 60% distal left main stenosis and an occluded proximal right coronary artery. Endomyocardial biopsy reported non-specific degenerative changes. We concluded that the troponin elevation and cardiac MRI findings were explained by coronary disease, which we treated medically, reserving PCI only if he develops symptoms. Steroids were cancelled and he will continue his trial therapy.

### **Discussion**

Autoimmune myocarditis is the most common cardiac complication during treatment with ICI<sup>1</sup>. While troponin is the preferred biomarker for its detection, this diagnosis should not be made without considering other causes<sup>2,3</sup>. In this case, the patient may have been denied ICI therapy and critical coronary disease missed if the diagnosis was made based on troponin and MRI alone. A comprehensive cardiovascular assessment is necessary in the context of troponin elevation and cardiac MRI abnormal findings, as the development of immune-related adverse events can lead to the interruption or cessation of the treatment with immunotherapy<sup>4</sup>.

### **References**

1. Agrawal N, Khunger A, Vachhani P, et al. Cardiac Toxicity Associated with Immune Checkpoint Inhibitors: Case Series and Review of the Literature. *Case Rep Oncol* 2019; 12:260-276.
2. Bonaca MP, Olenchock BA, Salem JE, et al. Myocarditis in the Setting of Cancer Therapeutics. *Circulation* 2019; 140:80-91.
3. Sarocchi M, Grossi F, Arboscello E, et al. Serial Troponin for Early Detection of Nivolumab Cardiotoxicity in Advanced Non-Small Cell Lung Cancer Patients. *The Oncologist* 2018; 23:936-942.
4. Postow MA, Sidlow R and Hellmann M. Immune-Related Adverse Events Associated with Immune Checkpoint Blockade. *N Engl J Med* 2018; 378:158-68.

Image 1

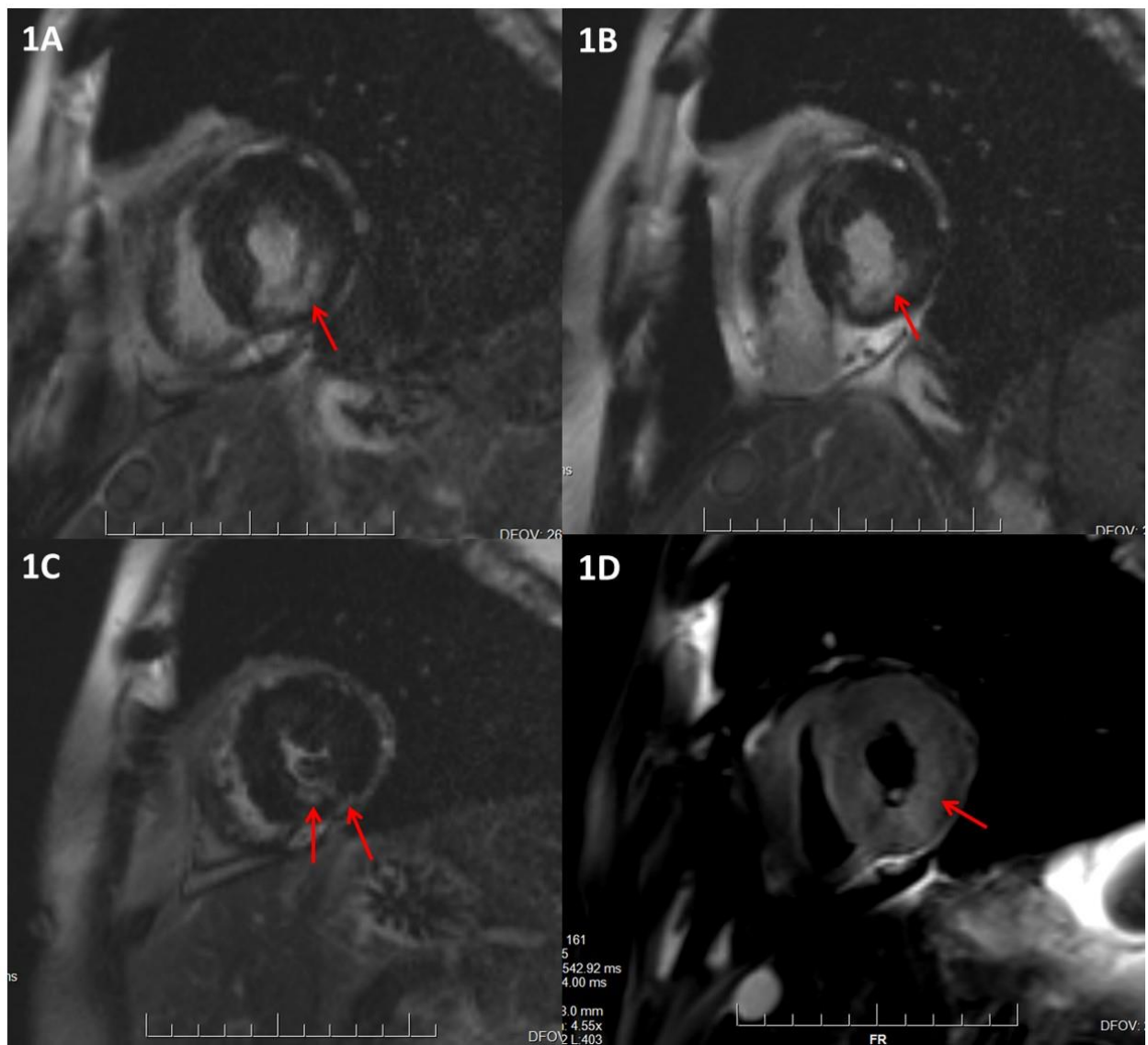


Image 2

