

Control Number: 40

Abstract Category: Clinical Case Challenge in Cardio-Oncology

Title: Surgical Resection for Cardiac Metastases of Uterine Leiomyosarcoma

ABSTRACT BODY

Background and Purpose

Uterine leiomyosarcoma is a rare malignancy and carries a poor prognosis. Cardiac metastasis from uterine leiomyosarcoma is even rarer and typically carries a very poor prognosis. Clinical manifestations vary based on the size, location, and extent of tumor infiltration ranging from asymptomatic state to obstructive shock. Although combination chemotherapy and local radiation therapy are usually the first lines of management, palliative surgery may be necessary to correct hemodynamics with cardiac involvement.

Case Description and Outcomes

A 76-year-old woman with a history of uterine leiomyosarcoma presented with syncope a year after surgical resection. An echocardiogram and CT scan revealed a large mass arising from the interventricular septum in the right ventricle (RV) extending to the right ventricular outflow tract (RVOT) and the pulmonic valve causing RVOT obstruction and involving the main and right pulmonary artery (PA). Patient underwent radical resection of the mass with reconstruction of the RV free wall, RVOT, the main and right PA as well as pulmonary and tricuspid valve replacement. Patient made an uneventful recovery and maintained a reasonable quality of life. Routine surveillance echocardiography and cardiac MRI 22 months later showed recurrence of RV mass. Subsequent PET/CT scan revealed progression of the disease despite palliative antineoplastic therapy. Two years after surgery, palliative antineoplastic therapy was discontinued and she was transitioned to hospice care.

Discussion

Cardiac metastasis of uterine leiomyosarcoma is very rare. Given associated high morbidity and mortality with cardiac involvement, a high index of suspicion should be maintained in patients with any new or worsening cardiac symptoms. Multimodality imaging can be useful for preliminary diagnosis and also to assess the hemodynamic impact of cardiac metastasis. Given the rarity of this entity, there is relatively lack of evidence about how to best manage it. However, palliative surgical intervention in selected cases like ours can be beneficial for restoration of hemodynamics and quality of life acknowledging overall poor prognosis.

References

1. Nguyen SKA, Wong F. Right atrial metastasis of uterine leiomyosarcoma causing obstructive shock. *Curr Oncol*. 2012 Aug;19(4):e292-4.
2. Artioli G, Borgato L, Calamelli S, Azzarello G. Unusual cardiac metastasis of uterine leiomyosarcoma: case report and literature review. *Tumori*. 2016 Nov;102(Suppl. 2).

Image 1

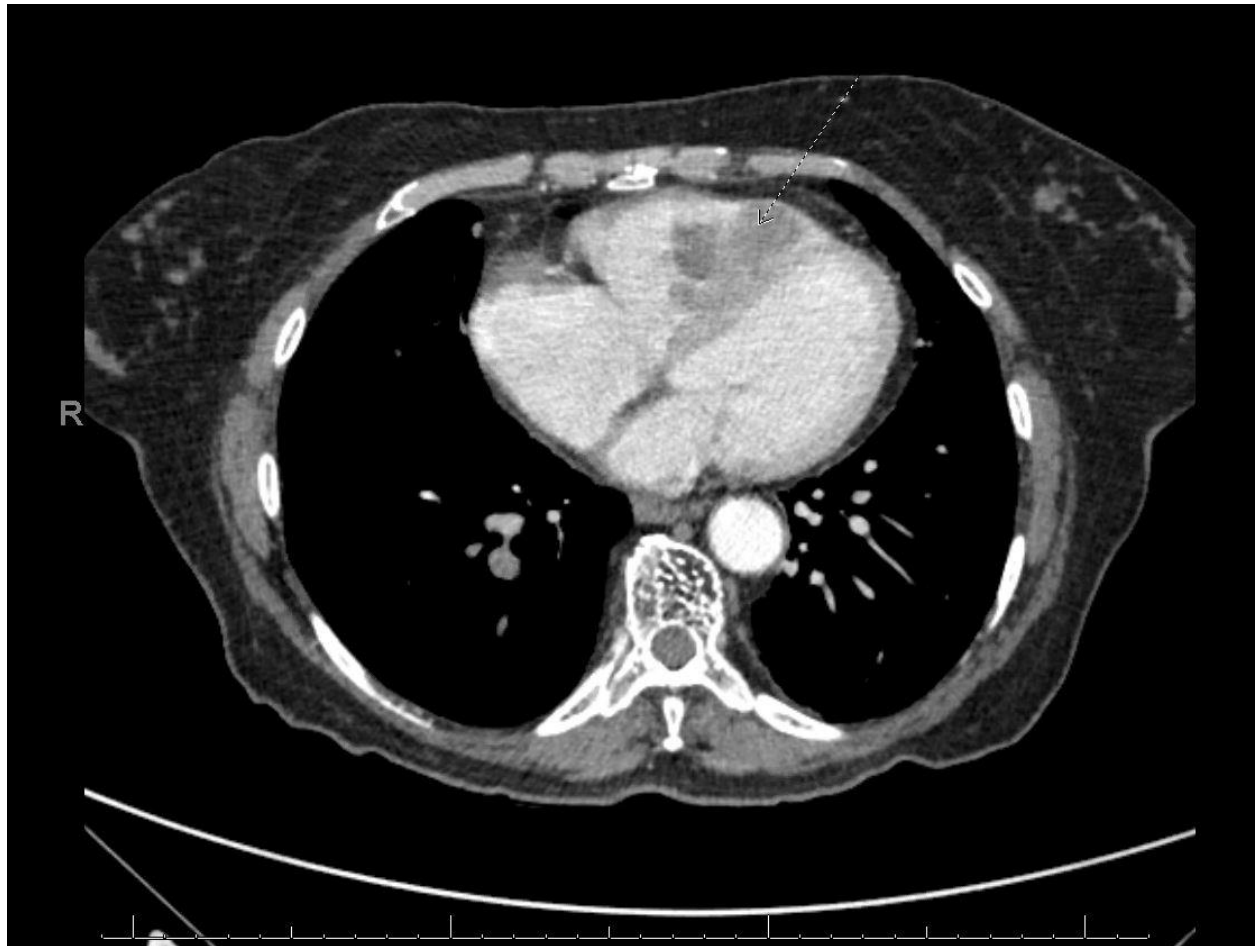


Image 2

