

Introduction

Ibrutinib is a bruton’s tyrosine kinsase inhibitor used for the treatment of a broad spectrum of B-cell proliferative disorders including refractory mantle cell lymphoma, marginal zone lymphoma, and Wal-denstrom macroglobulinemia.

Most common side effects are fatigue, diarrhea, hemorrhage, worsening creatinine clearance, and hy-pertension.

Of particular interest for us are the cardiac side effects of which atrial fibrillation has a well known as-sociation. However there have been case reports of *ventricular arrhythmias* and sudden cardiac death in patients treated with ibrutinib.

Case Presentation

68 year-old man with history of Waldenstrom macroglobulinemia on treatment with ibrutinib for two years presented with syncope.

History of present illness: He was watching television on his couch when he felt dizzy and lost consciousness. Subsequently regained consciousness after two minutes by when his wife had called EMS.

Upon initial evaluation by EMS, he was noted to be in atrial fibrillation. En route to the hospital he had three episodes of ventricular tachycardia with pulse that necessitated electrical cardioversion and one episode of ventricular fibrillation requiring defibrillation.

In the hospital, vitals were stable, and physical exam was unremarkable. He was admitted to the CCU on an amiodarone drip. Only home medication was reported as ibrutinib.

Blood work: unremarkable complete blood count and basic metabolic panel with normal electrolytes.

Angiogram: Near normal coronary arteries.

Echocardiogram: No regional wall motion abnormalities.

Cardiac MRI: Small area of mid-myocardial delayed enhancement in a nonvascular distribution in the basal inferolateral and anterolateral free wall.

Telemetry: Premature ventricular complexes originating from the right ventricular apex.

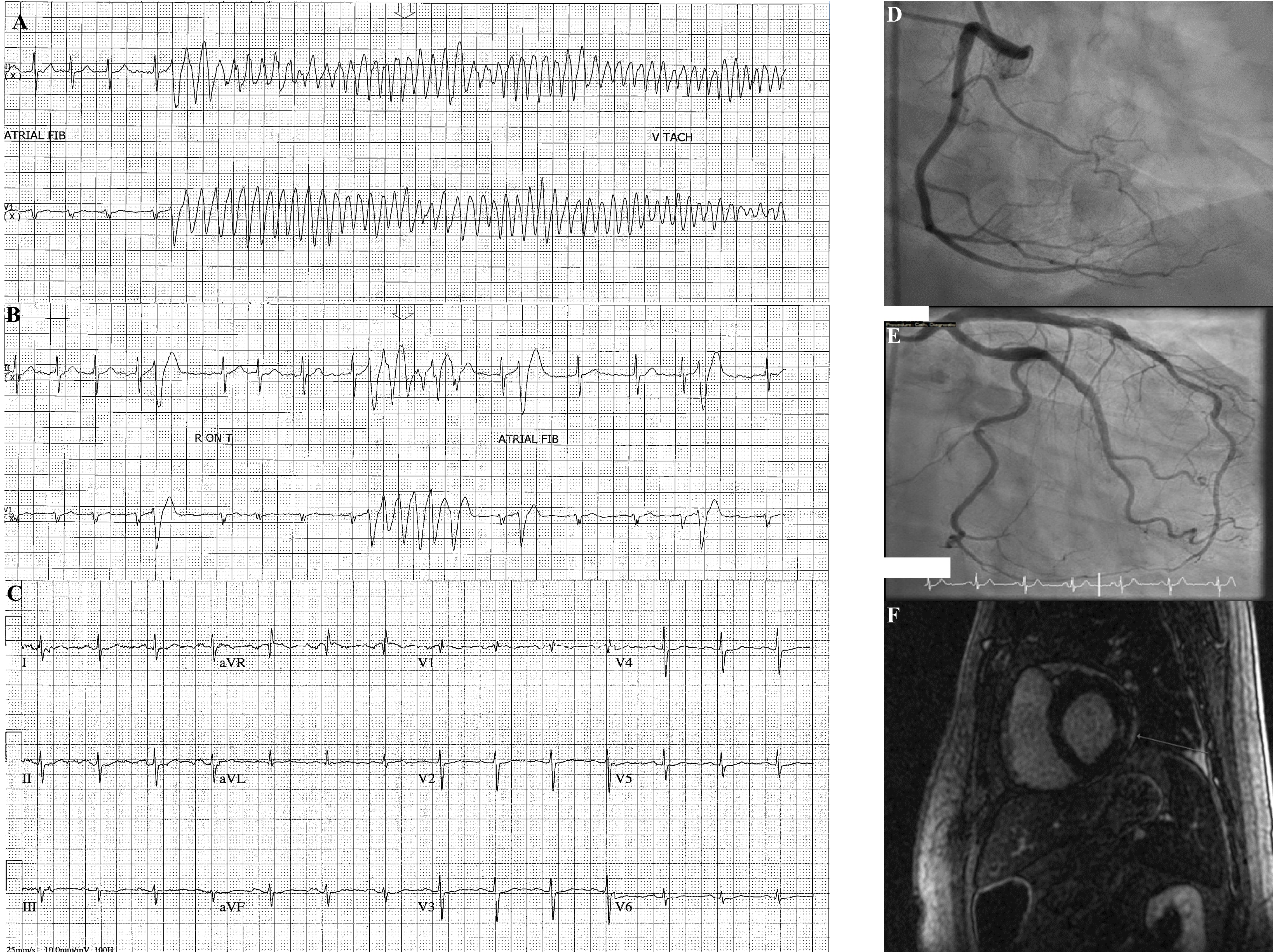


Figure 1.

A - Electrocardiogram demonstrating one episode of ventricular tachycardia (VT) after an R on T phenomenon preceded by normal QTc interval.

B - Electrocardiogram demonstrating non-sustained burst of VT.

C - Electrocardiogram of our patient at the time of discharge significant for RV conduction delay.

D&E - Coronary angiogram showing near normal coronary arteries.

F - Cardiac MRI showing a mid-myocardial scar in a non-vascular distribution.

Management

After extensive multidisciplinary discussion with cardiology, electrophysiology and oncology teams, ibrutinib was discontinued due to its potential association with VT.

An ICD was placed. The patient was started on metoprolol.

Follow-up

No further VT at 6 month review of his ICD.

Discussion

. Atrial fibrillation is a well established adverse effect of ibrutinib with incidence of about 5-16% at 18 months from initiation of therapy.

. There are a few case reports of ventricular tachycardia in patients on ibrutinib. The exact mechanism is not yet established.

. In-vitro studies demonstrated ibrutinib triggered abnormal action potentials, both early and late af-terdepolarizations, and increased late sodium current, leading to enhanced automaticity.

. While association cannot be established, we urge clinicians to remain vigilant of this fatal adverse event.

. Further research efforts should focus on establishing the mechanism of cardiotoxicity in the hopes of developing strategies to prevent this adverse effect.

References

Lampson BL, Yu L, Glynn RJ, et al. Ventricular arrhythmias and sudden death in patients taking ibrutinib. *Blood* 2017;129:2581–2584.

Guha A, Derbala MH, Zhao Q, et al. Ventricular Arrhythmias Following Ibrutinib Initiation for Lymphoid Malignancies. *J. Am. Coll. Cardiol.* 2018;72:697–698.

Disclosures

None of the above named authors have any disclosures.