

# Triple Positive Cardiovascular Toxicity in a 76-Year-Old Male with Non-Small Cell Lung Cancer on Pembrolizumab

Vijay Rao MD PhD<sup>1</sup>, Nadeem Ikhlake MD<sup>2</sup>, Ryan Daly MD<sup>1</sup>, Atul Chugh MD<sup>1</sup>

<sup>1</sup>Franciscan Physician Network Indiana Heart Physicians; <sup>2</sup>Franciscan Physician Network Oncology & Hematology Specialists

## BACKGROUND

Immune checkpoint inhibitors (ICIs) have become an important therapeutic option for numerous advanced stage cancers. Cardiovascular toxicity, including arrhythmias, acute coronary syndrome (ACS), and myocarditis have been reported with increased frequency (1, 2). Herein, we describe a challenging case of a patient presenting with chest pain after initiation of an ICI who developed concurrent rapid atrial fibrillation, ACS, and myocarditis.

## CASE DESCRIPTION

76 yo male with history of remote ACS and left upper-lobe non-small cell lung cancer (NSCLC: T2aN0M0), who was started on Pembrolizumab 3 weeks prior due to marked progression of disease, presented to the hospital with a week of chest tightness occurring at night, worse with lying down, lasting 20-30 minutes and associated with significant fatigue.

Labs, ECG, and ECHO results are presented in Table I.

TABLE 1

**Labs:** Troponin I was 1.1ng/ml (ref <0.04), trended up to 1.17ng/ml.

TSH was 0.03mIU/L (ref 0.27-4.2) with elevated free T4 2.49ng/dL (ref 0.55-1.6).

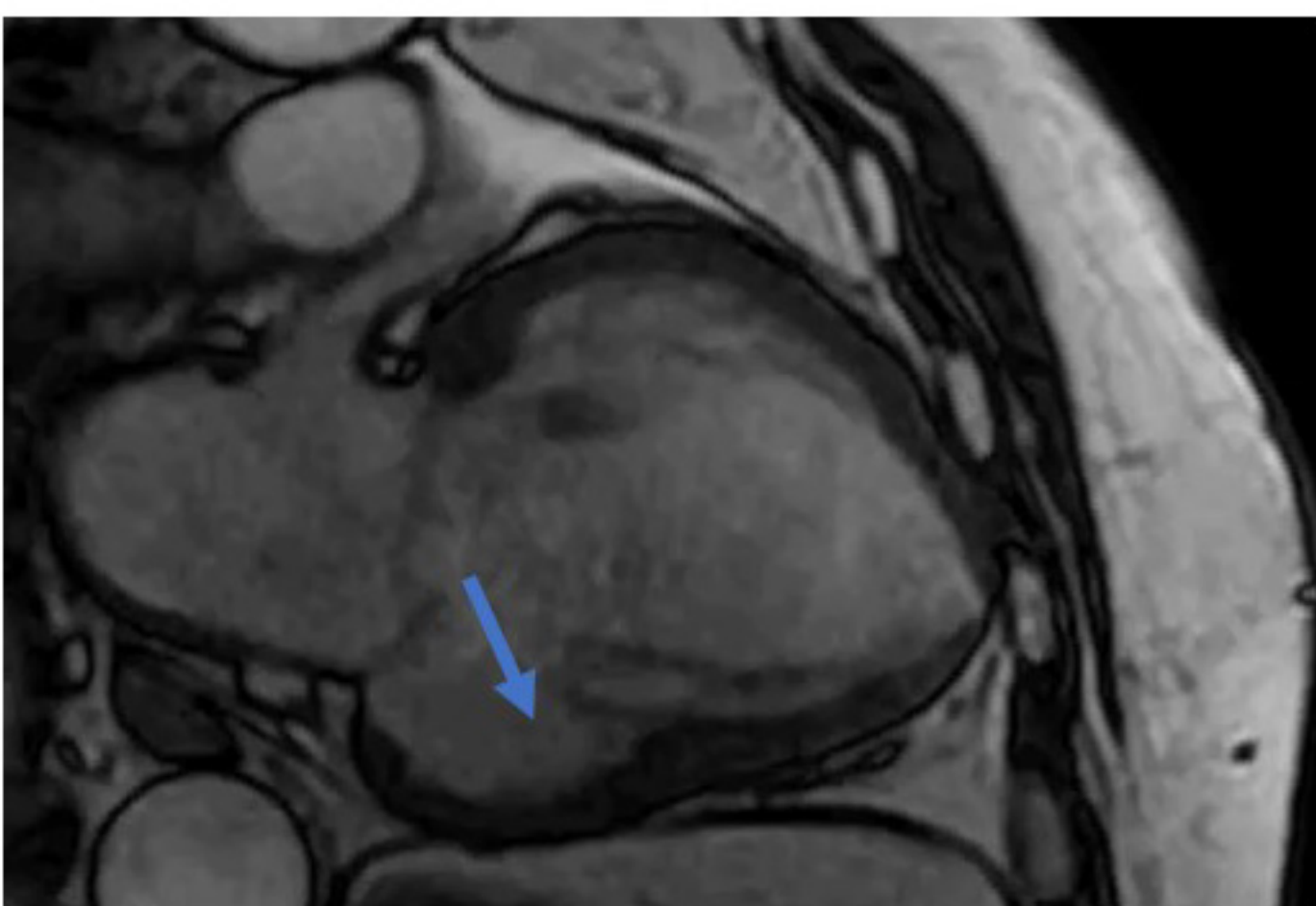
**ECG:** NSR with inferior MI (old) with poor R wave progression vs anterior infarct

**ECHO:** Normal LV size with mildly reduced function (EF 45-50%), akinetic inferior wall, severe hypokinesis of the septum, moderately reduced RV function, severe mitral regurgitation (58cc RV)

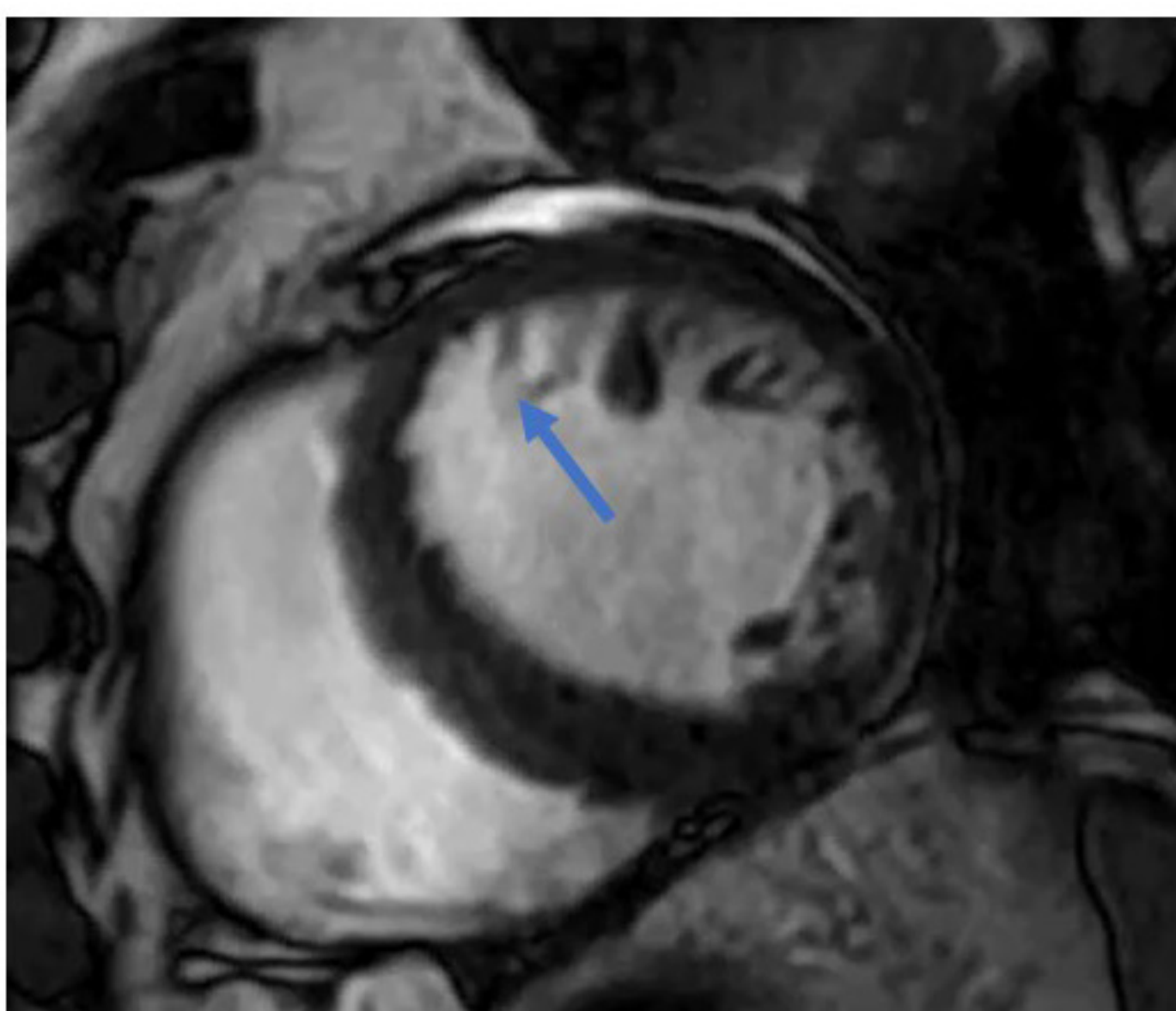
Patient developed rapid atrial fibrillation treated with a diltiazem drip. Given concern for myocarditis, cardiac MRI was obtained (Figure 1A-1C) revealing old inferior infarct, acute anteroseptal infarct, and diffuse myocarditis.

Given stage IV lung cancer with rapid progression, ACS was managed conservatively. The patient was started on prednisone 1mg/kg daily to treat the myocarditis and methimazole for autoimmune thyroiditis thought due to ICI.

FIGURE 1A

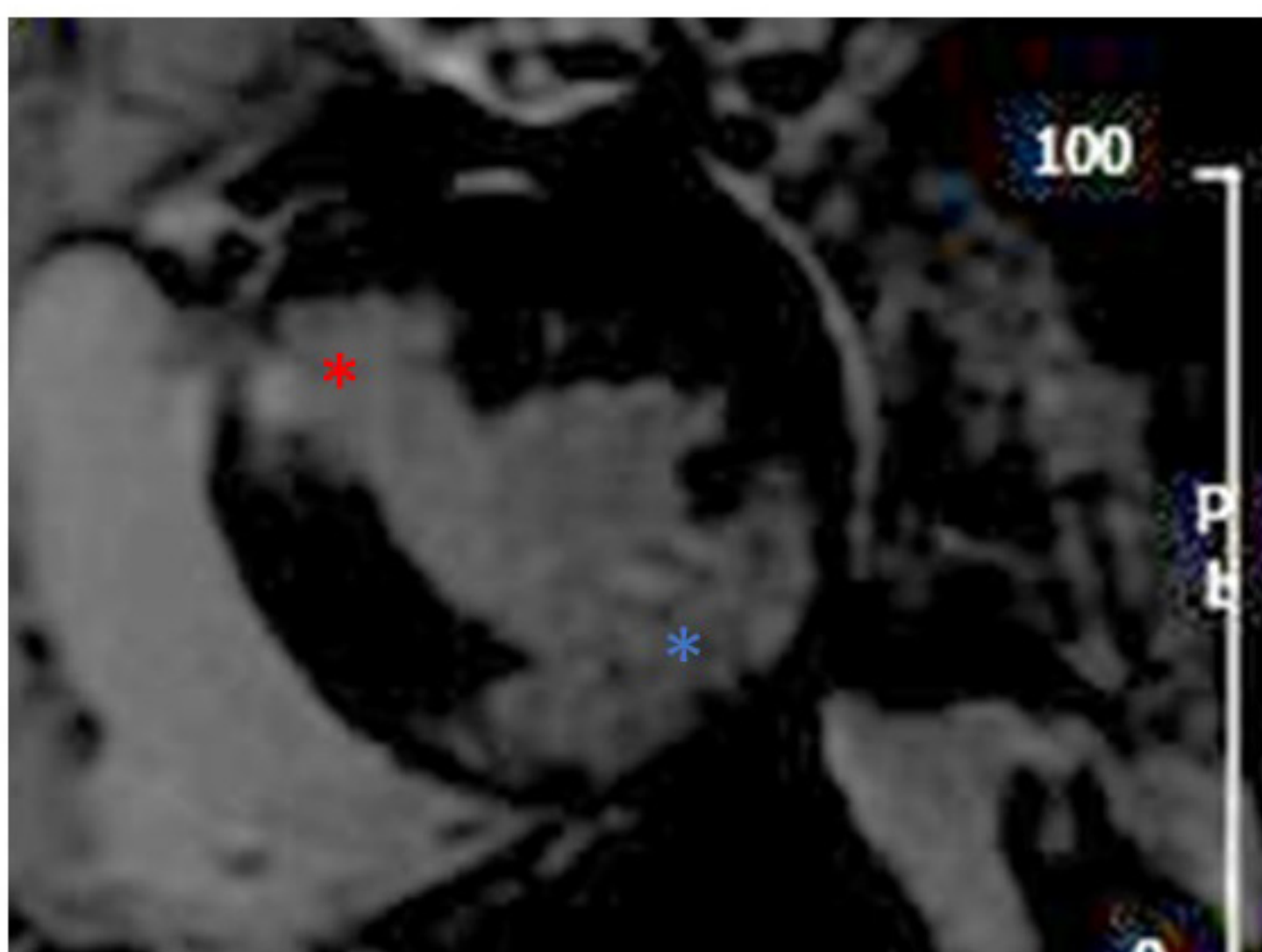


2 chamber view demonstrating a thin, dyskinetic segment at the basal inferior wall (blue arrow)

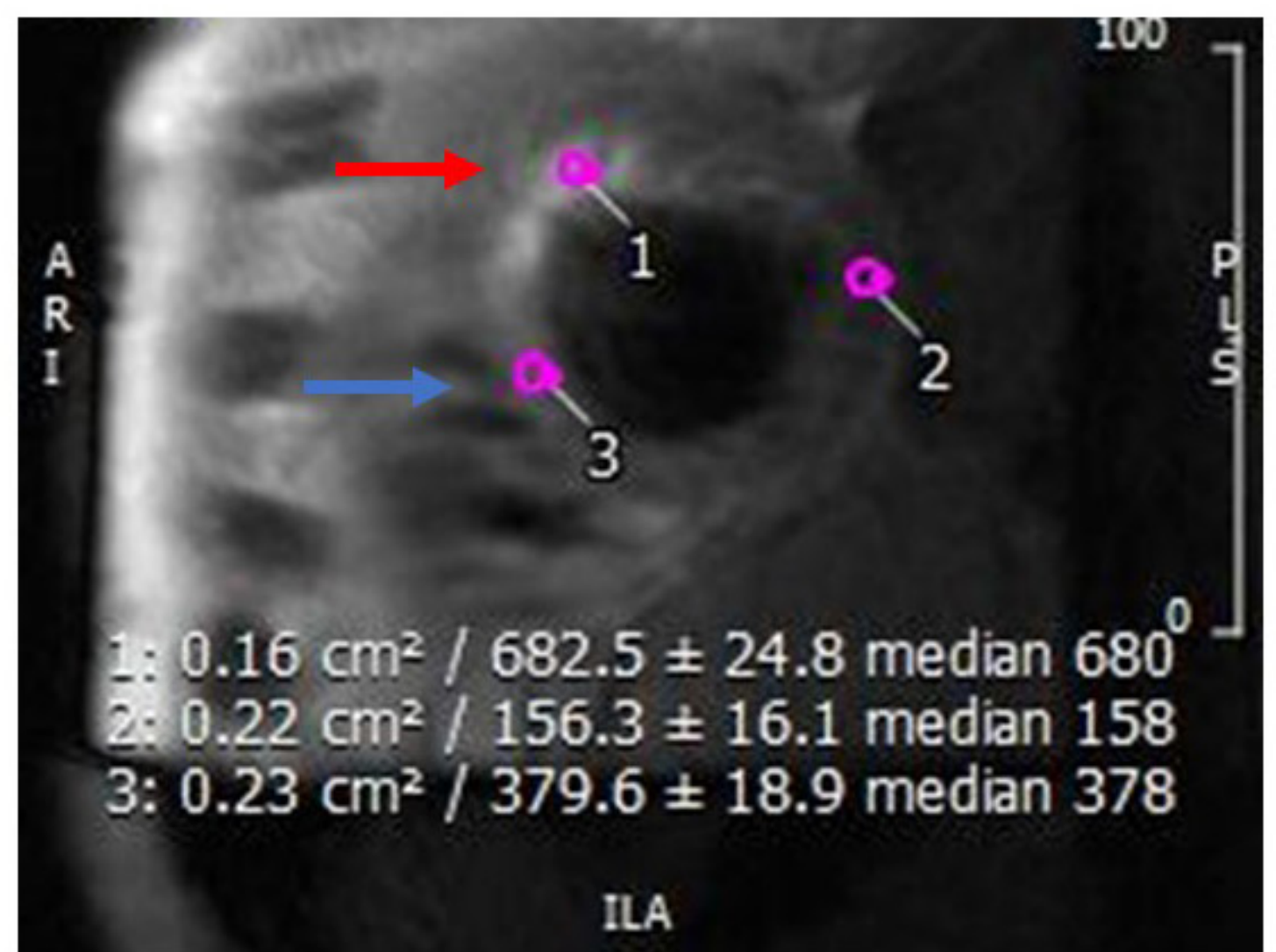


Short axis view demonstrating a hypokinetic mid anteroseptal wall wallmotion abnormality (blue arrow)

FIGURE 1B

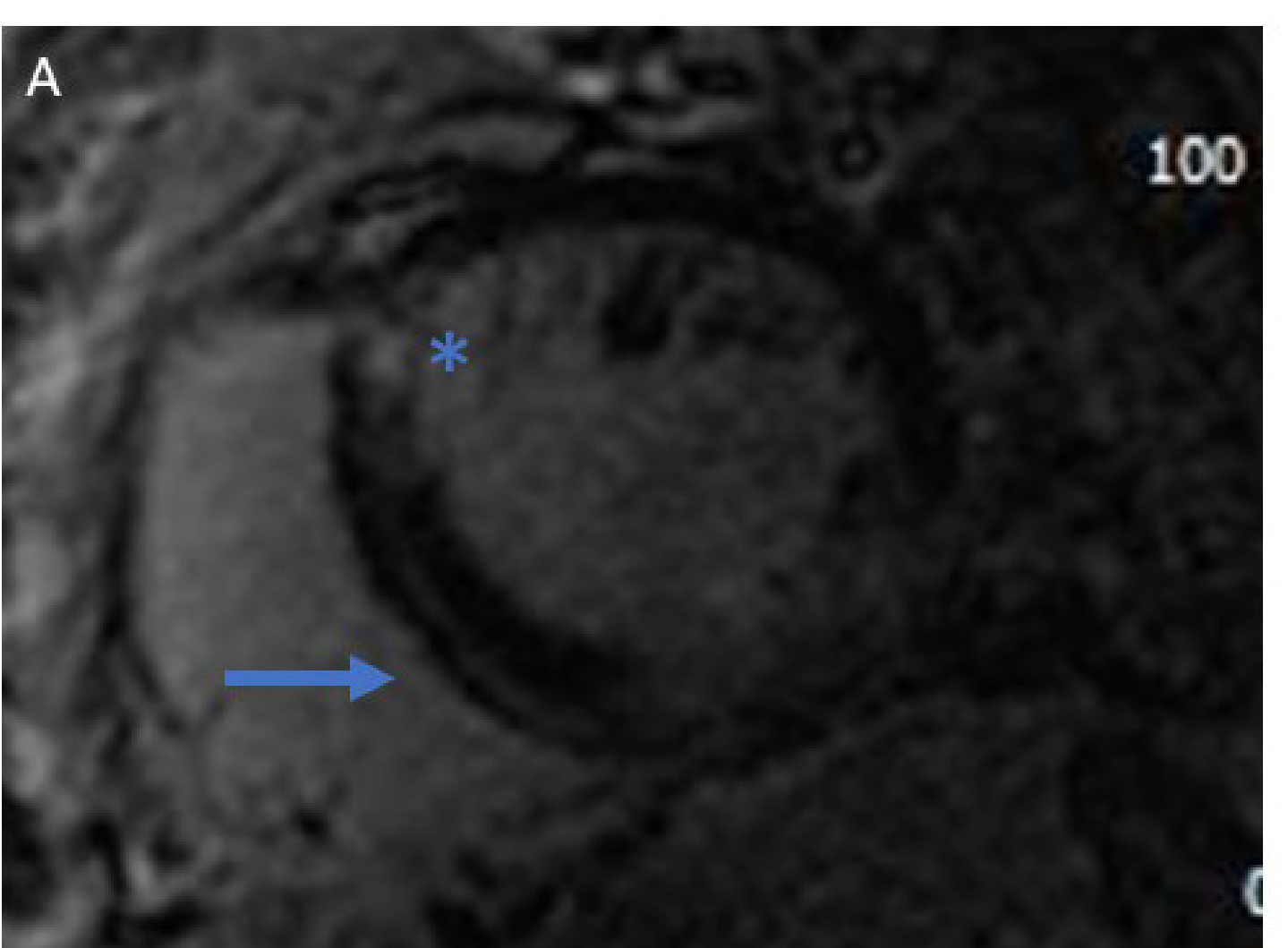


Short axis slice demonstrating subendocardial thinning and late gadolinium enhancement in the anteroseptal (red \*) and inferior wall (blue \*) segments



T2 Stir Imaging reveals dense subendomyocardial edema in the anteroseptal segment (red arrow, median SI: 680). However, there is also a signal for edema in the inferoseptal segment (blue arrow; median SI: 378 vs. 158 in the non-affected lateral wall).

FIGURE 1C



In addition to the subendocardial thinning and late gadolinium enhancement (blue \*) in the anteroseptal segments, there is subepicardial (blue arrow) late gadolinium enhancement in the inferoseptal segments

## OUTCOMES

Patient had rapid progression of lung cancer over next several weeks, and given limited treatment options, he was started back on pembrolizumab/pemetrexed. Shortly thereafter, he developed compression fractures of his lumbar spine and suffered a cardiac arrest in the hospital.

## DISCUSSION

To our knowledge, this is the first case of a patient presenting with three concurrent cardiovascular toxicities attributed to initiation of an ICI. The rapid atrial fibrillation was likely due to a combination of autoimmune thyroiditis, myocarditis, and severe mitral regurgitation resulting from ICI initiation. Several challenging clinical decisions in this case included utilization of high-dose steroids to treat ICI myocarditis in the setting of ACS, and whether or not to re-challenge the patient with ICI once myocarditis had been diagnosed.

## REFERENCES

1. Mahmood et al JACC 2018, Apr 24;71(16): 1755-1764
2. Ganatra and Nielan 2018 The Oncologist 23: 518-523.

*The authors declare that they have no relevant or material financial interests that relate to the research described in this paper.*