

CERTIFIED CARDIOVASCULAR KNOWLEDGE EXAMINATION

For NPs/PAs Practicing in the U.S.



SAMPLE EXAM QUESTIONS

QUESTION 1

A 70-year-old woman comes for a routine annual physical exam. She reports that she feels well and exercises daily. She has a history of hypertension managed with lisinopril and amlodipine. She monitors her blood pressure at home; it ranges from 110/60 to 125/75 mm HG. Additional medications include aspirin 81 mg daily, calcium and vitamin D supplements and monthly alendronate to prevent osteoporosis. The patient is 5 ft 3 in tall and weight 150 lb; BMI is 26.6 kg/m². Heart rate is 75/min, respirations are 10/min, and blood pressure is 135/80 mm HG. Jugular venous pressure is 6 cm H₂O. Carotid artery upstrokes are normal; there is a faint bruit on the left. Lungs are clear to auscultation. Cardiac exam discloses a single S₁ and a physiologically split S₂; there are no murmurs. There are no abdominal bruits. Posterior tibialis and dorsalis pedis pulses are 2+. Laboratory studies show the following:

Blood:

- Cholesterol, total 210 mg/dL
- HDL 44 mg/dL
- LDL 120 mg/dL
- Triglycerides 210 mg/dL

Carotid artery ultrasonography shows stenosis of 65% on the left and less than 49% on the right.

Which of the following is the most appropriate pharmacotherapy?

- A. Clopidogrel
- B. Dipyridamole
- C. Hydrochlorothiazide
- D. Rosuvastatin
- E. Warfarin

CERTIFIED CARDIOVASCULAR KNOWLEDGE EXAMINATION

For NPs/PAs Practicing in the U.S.



QUESTION 2

A 44-year-old woman is referred for evaluation of a diastolic cardiac murmur. Cardiac exam discloses reduced intensity of S1 and S2; there is reverse splitting of S2. A diastolic cardiac murmur can be heard best when the diaphragm of the stethoscope is placed over the left sternal border with the patient sitting, leaning forward, and holding her breath in full expiration.

Which of the following is the most likely cause of the murmur?

- A. Aortic regurgitation
- B. Atrial septal defect
- C. Mitral stenosis
- D. Patent ductus arteriosus
- E. Tricuspid stenosis

QUESTION 3

A 41-year-old white man is referred for evaluation because of a family history of cardiovascular disease. The patient reports no symptoms. Medical history includes seasonal allergies treated with antihistamines as needed. His father sustained a myocardial infarction at age 60 years. The patient has never smoked cigarettes. He is 5'6" (168 cm) tall and weighs 171 lb. (78 kg); BMI is 28 kg/m². Temperature is 97.2°F (36.2°C), heart rate is 64 bpm, respirations are 14 breaths/min, and blood pressure is 118/78 mm Hg. Laboratory studies show the following:

| | |
|--------------------|-----------|
| Hemoglobin A1c | 4.8% |
| Cholesterol, total | 210 mg/dL |
| HDL | 42 mg/dL |
| LDL | 146 mg/dL |
| Triglycerides | 110 mg/dL |

The patient's estimated 10-year and lifetime atherosclerotic cardiovascular disease (ASCVD) risk are 1.5% and 46%, respectively.

- A. Implement the Dietary Approaches to Stop Hypertension (DASH) diet
- B. Initiate low-intensity statin therapy
- C. Order apolipoprotein B levels and LDL subclasses
- D. Order coronary CT calcium score
- E. Repeat the lipid profile in five years

CERTIFIED CARDIOVASCULAR KNOWLEDGE EXAMINATION

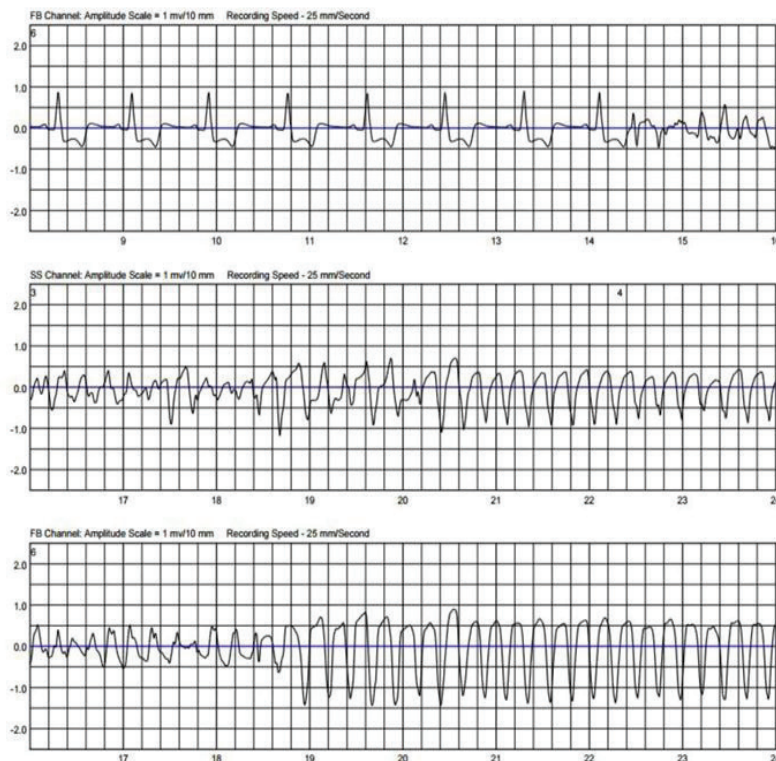
For NPs/PAs Practicing in the U.S.



QUESTION 4

A 51-year-old man calls the office after being awakened from sleep by his wife, who felt him being jolted. One week ago, the patient underwent angioplasty after sustaining a myocardial infarction. A wearable defibrillator was placed on him upon hospital discharge. The patient reports that he currently feels well and is unaware that he was jolted by the device, but he notes that gel was released from the device onto his chest. The device company faxes the strip shown, which was obtained at the time the wife was first awakened.

(Figure 1)



Which of the following is the most likely diagnosis?

- A. Antidromic AV reentrant tachycardia
- B. Ventricular fibrillation
- C. Artifact
- D. Atrial fibrillation conducting down a bypass tract
- E. Monomorphic ventricular tachycardia

CERTIFIED CARDIOVASCULAR KNOWLEDGE EXAMINATION

For NPs/PAs Practicing in the U.S.



QUESTION 5

An 82-year-old man underwent transcatheter aortic valve replacement (TAVR) for severe aortic stenosis eight months ago. He plans to undergo dental extractions in the near future. He reports improvement in his functional status and quality of life since the TAVR. Medical history includes hypertension, benign prostatic hyperplasia, and dementia. Current medications include aspirin 81 mg once daily, lisinopril 5 mg once daily, and tamsulosin 0.4 mg once daily.

Which of the following is the most appropriate recommendation regarding antibiotic prophylaxis for this patient?

- A. Defer dental extractions for one year following transfemoral TAVR procedure
- B. Initiate antibiotic prophylaxis before dental procedures for up to one year following transfemoral TAVR procedure
- C. No antibiotic prophylaxis is indicated
- D. Initiate lifelong antibiotic prophylaxis for dental procedures

Answers below:

Question 1 - D. Rosuvastatin

Question 2 - A. Aortic regurgitation

Question 3 - A. Implement the Dietary Approaches to Stop Hypertension (DASH) diet

Question 4 - B. Ventricular fibrillation

Question 5 - D. Initiate lifelong antibiotic prophylaxis for dental procedures