One COVID-19 case with multiple system damage

Medical team in Hubei
Zhongshan Hospital, Fudan University
East Branch, Rennin Hospital of Wuhan University

Zheyong huang&Jiatian Cao
Shanghai Institute of Cardiovascular Diseases
Dept. of Cardiology, Zhongshan Hospital

History

- Zhu XX, Male, 31-year-old
- [Chief complain] Intermittent fever for 3 weeks
- [Present history] Since January 24, 2020, the patient developed fever with a little cough, so he went to Wuhan Wuchang Hospital on January 26. Laboratory test showed: WBC 2.73*10^9/L, L: 1.15*10^9/L，Plt: 99*10^9/L and CRP: 40mg/L. Chest CT: Multiple patchy opacity, some of them ground-glass.

History

Oropharyngeal swabs(Nucleic acid test): COVID-19 (+)

Oral abidol use for 6 days, Traditional Chinese medicine:Lianhua ,Qingwen capsule: 5 days,“Pneumonia 1st” prescription: 5 days in shelter hospital. Fever worsened for 3 days, Tmax 38.5℃ with sweating and liver dysfunction. Transferred into our department.

Diet, feces and urine were normal

Physical examinations

- Signs on admission:
- T: 38.5℃
- P: 152 beats per min
- R: 24 breaths per min
- BP: 134/107mmHg
- SpO2: 95% (no oxygen)
- Height: 177cm, weight: 88kg
- slightly faster breath
- Soft abdomen, no tenderness or rebound pain
- No obvious filling of jugular vein and no swelling of lower limbs

History

[Medical history] Diabetic 10 years, untreated and hyperlipidemia 5 years, untreated

[History of infectious diseases] Living in Wuhan, probable exposure to COVID-19

[History of operation or trauma] Appendectomy.

[Drug and poison contact] Arbidol 6 days. Qingwen capsule: 5 days

“Pneumonia 1st” prescription: 5 days

[Allergy] None.

[Personal history] Born and living Wuhan, Hubei; no history of cigarettes or alcohol

[Marital history] Married.

[Family history] Denied.

Laboratory test（2020-2-29）

- Blood glucose: 31mmol/L
- Arterial Blood Gas Analysis（intranasal oxygen inhalation 7L/min): PH 7.4，PaCO2 24mmol/L，PaO2 290 mmol/L ，BE -8.3mmol/L

ECG（2020-2-29 1:20 ）

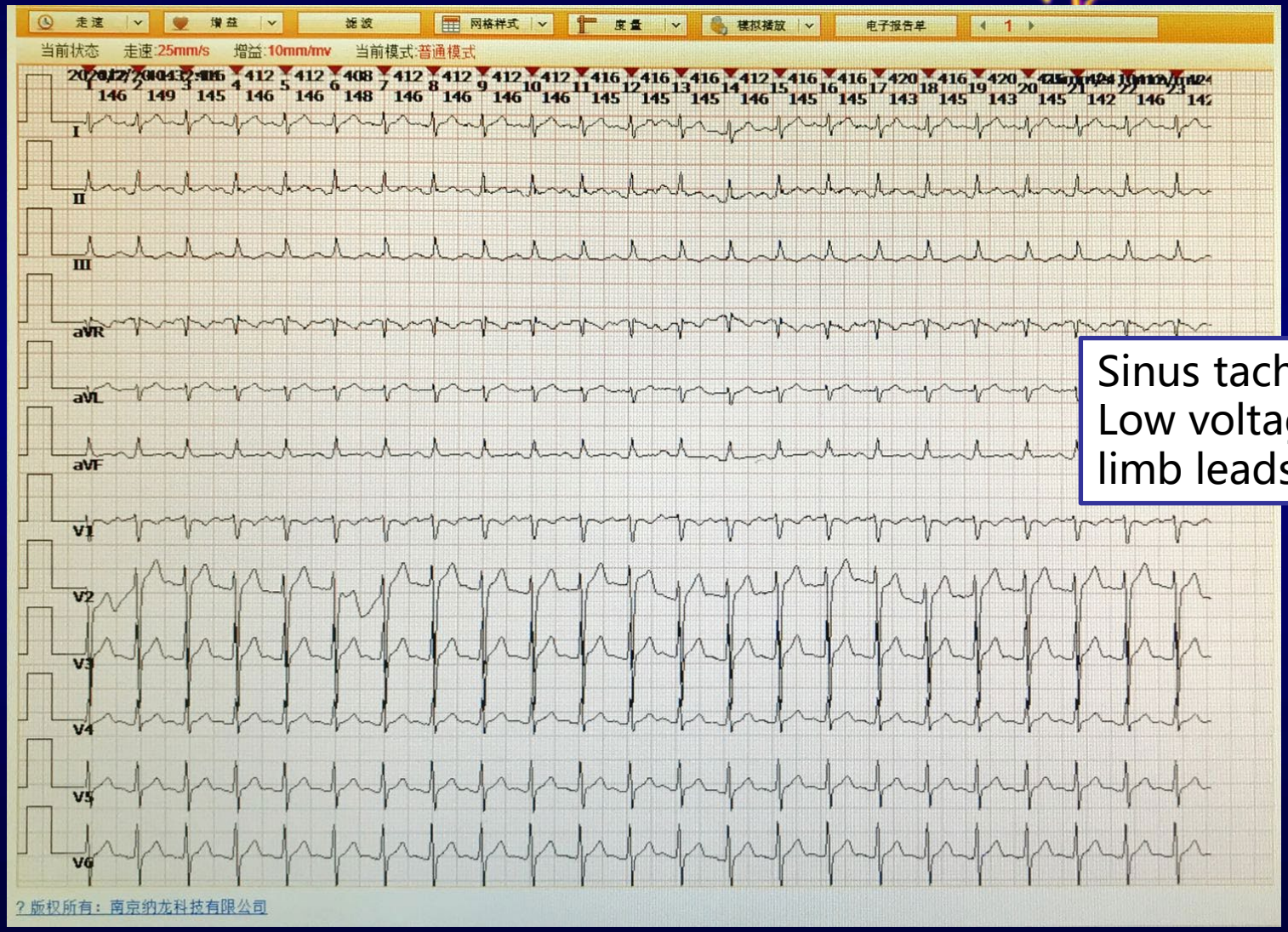

Sinus tachycardia
Low voltage in the limb leads

Laboratory test（2020-2-29 ）

WBC	LYN	NEU	Hb	PLT	CRP	PCT	CD4	CD8	IL6
2.6	0.41	1.98	124	55	> 200	3.37	38	32	146

BNP	cTNI	MYO	CK-MB	ALT	AST	Scr	LDH	K	Na	D-dimer
1651	0.15	33	0.6	189	110	55	380	3.9	126	0.96

lipase	amylase	TC	TG	urine ketone	urine glucose	
(-)	(-)	7.31	8.83	+++	+++++	

Chest CT （2020-2-29 ）

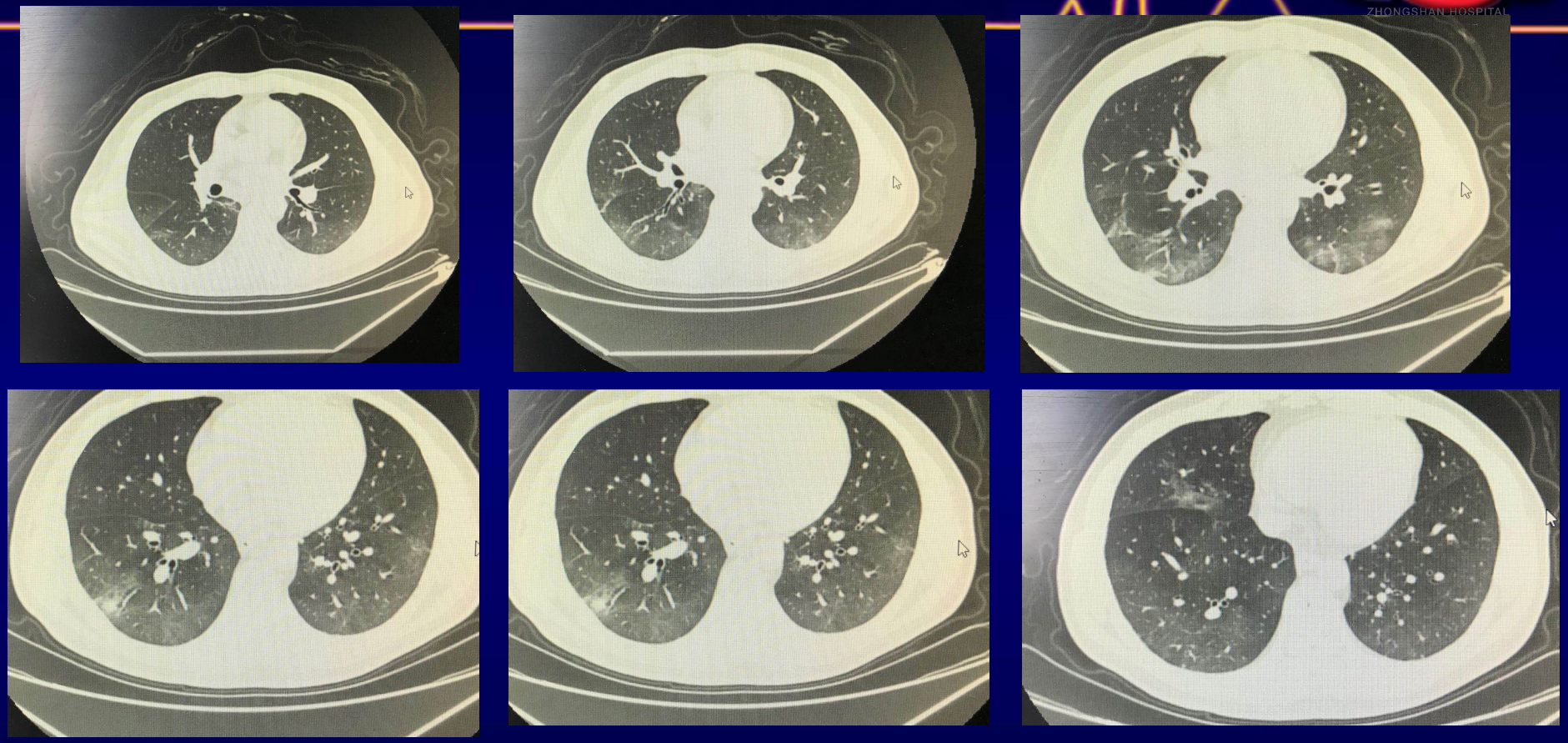

Multiple patchy opacity, some of them ground-glass.

Diagnosis

- Critical COVID-19
- Type 1 diabetes mellitus, ketoacidosis?
- Heart failure, tachycardia, myocardial injury?
- Sepsis?
- Liver dysfunction

Treatment

- Antiviral therapy (Arbidol, completed)
- Anti inflammatory and immunomodulatory therapy

① Enhance immunity (human immunoglobulin + thymalfasin)

② Anti inflammatory (Methylpred nisolone: 20mg q12h）

③ Antibiotics (Meropenem + Tigecycline)

- Oxygen therapy
- Treatment of complications and comorbidity

Treatment of complications and comorbidity

- Blood glucose and Ketosis

① Insulin (insulin pump + Lantus)

② Dilation (Lactate Ringer's solution + physiological saline+ albumin)

- Thrombocytopenia: Recombinant human thrombopoietin injection
- Liver dysfunction: Glutathione + Magnesium Isoglycyrrhizinate Injection

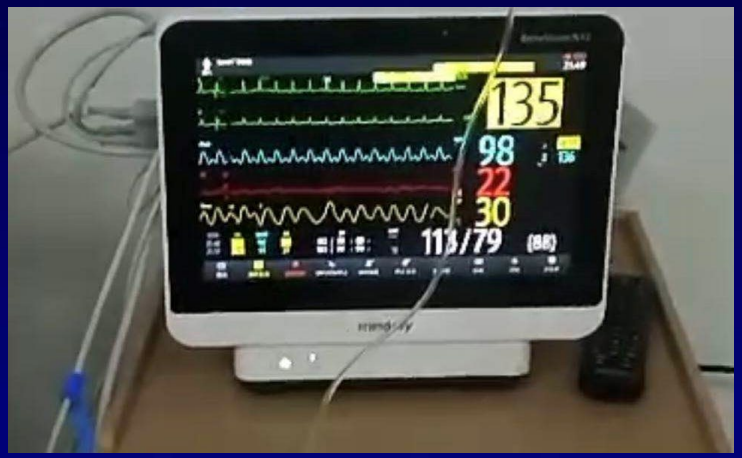

Pink frothy sputum

3-1 21:47 acute heart failure

- Furosemide
- Digoxin
- Morphine
- BIBAP

Echocardiography

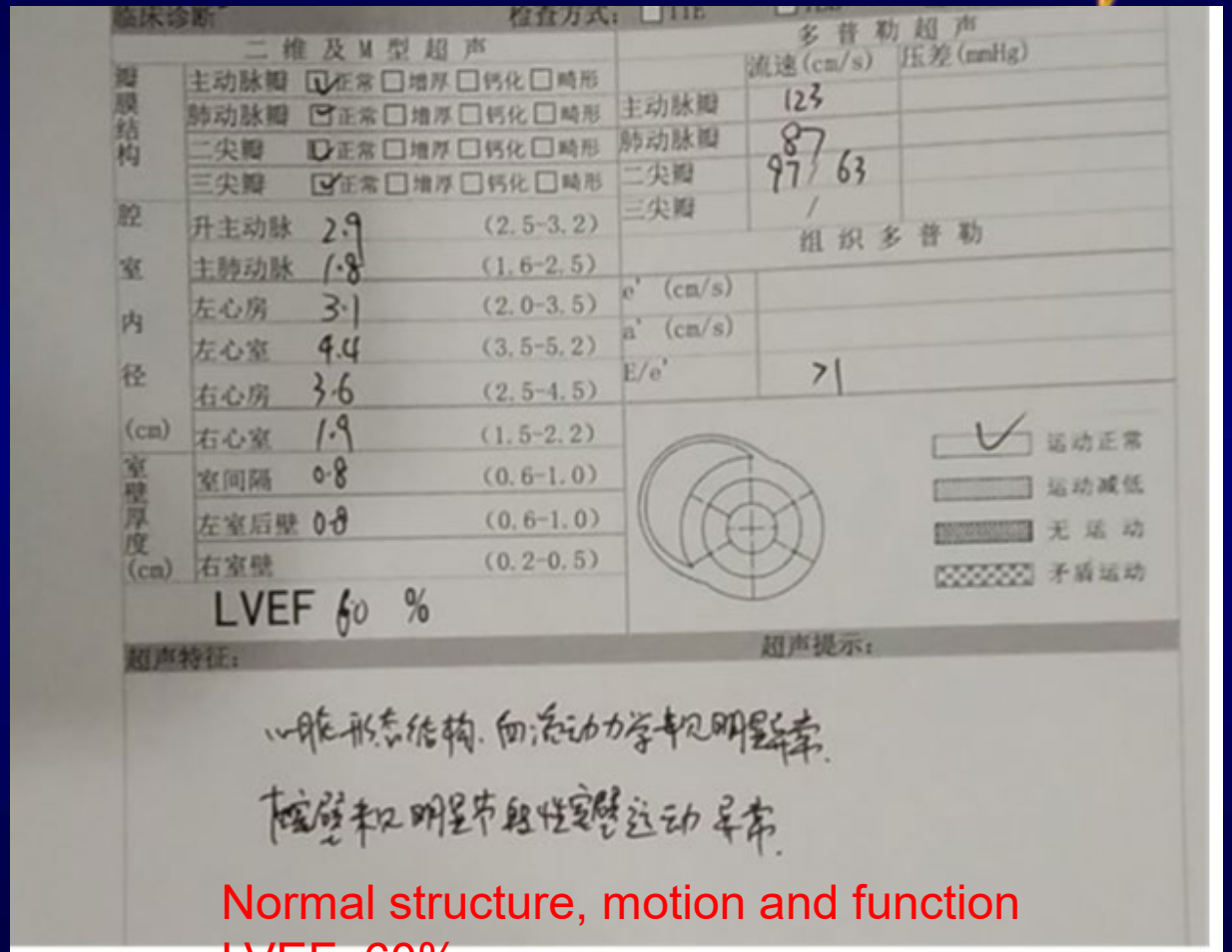

临床诊断 检查方式: TTE

二维及M型超声

瓣膜结构	主动脉瓣	☑正常 ☐增厚 ☐钙化 ☐畸形	
	肺动脉瓣	☑正常 ☐增厚 ☐钙化 ☐畸形	
	二尖瓣	☑正常 ☐增厚 ☐钙化 ☐畸形	
	三尖瓣	☑正常 ☐增厚 ☐钙化 ☐畸形	
腔室内径 (cm)	升主动脉	2.9	(2.5-3.2)
	主肺动脉	1.8	(1.6-2.5)
	左心房	3.1	(2.0-3.5)
	左心室	4.4	(3.5-5.2)
	右心房	3.6	(2.5-4.5)
	右心室	1.9	(1.5-2.2)
室壁厚度 (cm)	室间隔	0.8	(0.6-1.0)
	左室后壁	0.8	(0.6-1.0)
	右室壁		(0.2-0.5)

LVEF 60 %

多普勒超声

	流速(cm/s)	压差(mmHg)
主动脉瓣	123	
肺动脉瓣	87	
二尖瓣	97 / 63	
三尖瓣	/	

组织多普勒

e' (cm/s)	
a' (cm/s)	
E/e'	>1

☑ 运动正常
运动减低
无运动
矛盾运动

超声特征:

心脏形态结构、血流动力学未见明显异常。

室壁未见明显节段性室壁运动异常。

超声提示:

Normal structure, motion and function
LVEF: 60%

Echo

2020/02/22
11:06:39
AP 93.6%
MI 0.7 TIS 1.5
P4-2s
成人心脏
M
97/121

2020/02/22
11:01:32
AP 92.9%
MI 0.4 TIS 0.2
P4-2s
成人心脏
M
230/337

2020/02/22
11:16:05
AP 93.0%
MI 0.4 TIS 0.4
P4-2s
成人心脏
M
135/430

24-hour inflow and outflow volume & central venous pressure

	Inflow (ml)	Outflow (ml)	CVP(cmH_2O)
2-29	2100	2300	15
3-1	2300	3300	10
3-2	1910	2100	15

Treatment

- Torasemide 10mg bid, reduced to 10mg qd on Mar. 2
- Spironolactone 20mg qd

Arterial Blood Gas Analysis

	2-29	3-1	3-2	3-3
PH	7.4	7.38	7.46	7.47
PaCO2 mmol/L	24	30	32	38
PaO2 mmol/L	290	129	120	124
BE(B) mmol/L	-8.3	-6.5	-0.5	3.8

Laboratory test

	WBC	LYN	NEU	HB	PLT	CRP	PCT	CD4	CD8	IL6
2-29	2.6	0.41	1.98	124	55	> 200	3.37	38	32	146
3-1	3.96	0.27	3.42	118	91	123	2.36	24	25	135
3-2	3.69	0.39	3.02	105	94	> 200	-	-	-	-
3-4	3.51	0.31	2.89	110	141	106.5	0.33	-	-	20.45

	Pro-BNP	cTNI	MYO	CK-MB	ALT	AST	Scr	LDH	K	Na	D-dimer
2-29	1651	0.159	33	0.6	189	110	55	380	3.9	126	0.96
3-1	4260	0.45	29.8	0.78	104	52	64	268	4.09	132	6.69
3-2	2153	0.114	19.2	0.27	76	27	61	218	3.5	136	-
3-4	3399	0.135	30.37	0.3	50	12	54	199	3.48	144	3.5

Signs of the patient(3-4)

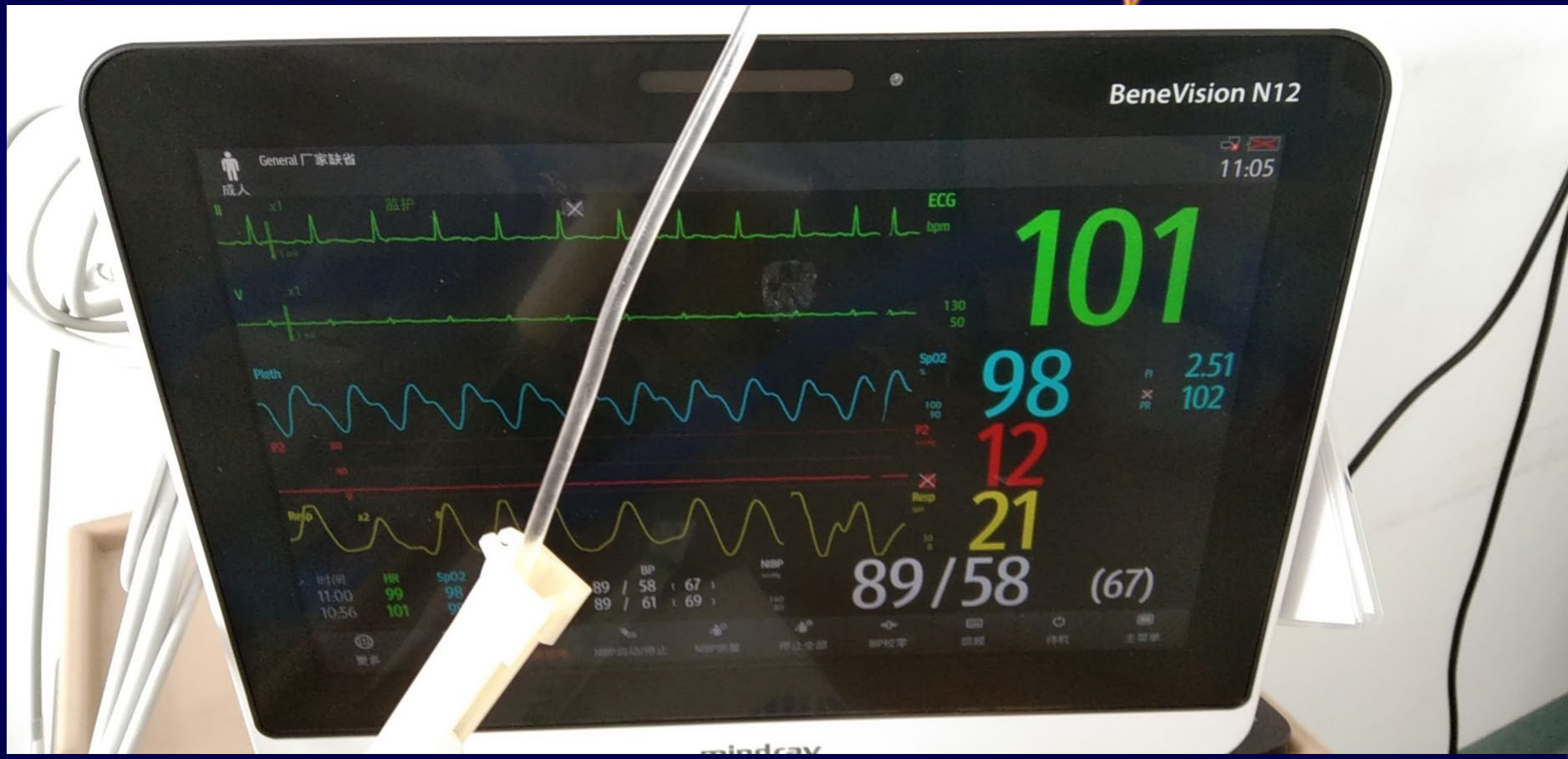

BOVATE

Question

- The mechanism of elevation of NT-proBNP and cTnI?
- The reasons of increased D-dimmer?
- Liver dysfunction?
- Treatment plan?