

## EDITORIAL COMMENT

# Cardiovascular Magnetic Resonance for the Diagnosis of Acute Myocarditis\*

## Prospects for Detecting Myocardial Inflammation

Peter P. Liu, MD, FACC,†  
Andrew T. Yan, MD, FRCPC‡  
Toronto, Ontario, Canada; and  
Boston, Massachusetts

Acute myocarditis is defined as inflammation of the myocardium, most often caused by viral infection or an autoimmune process. Myocarditis can lead to life-threatening arrhythmias or cardiogenic shock, chronic dilated cardiomyopathy, or spontaneous recovery. Conceptually, the pathogenesis of myocarditis can be divided into three stages: an initial viral proliferation phase, followed by immunologic response and inflammation, and finally myocardial remodeling and fibrosis (1). The latter two processes are particularly amenable to imaging by cardiovascular magnetic resonance (CMR).

See page 1815

Autopsy series of consecutive cases have demonstrated an incidence of myocarditis at approximately 1%. However, myocarditis is seriously under-diagnosed clinically. It is often a default diagnosis when patients present with unexplained symptoms of heart failure or chest pain but the coronary arteries were found to be normal on angiography. Part of the challenge is that the current modalities for diagnosis or prognosis remain poor. The commonly discussed modalities and their reported sensitivities and specificities are outlined in Table 1.

The gold standard has been traditionally viewed as pathology based on myocardial biopsy. However, it generally is considered to be very specific but too insensitive for clinical use, mostly because of the patchy nature of the disease. Indium-111 antimyosin scan is sensitive but rela-

tively non-specific. Therefore, a more accurate and noninvasive modality is needed clinically to diagnose myocarditis and potentially evaluate prognosis and treatment efficacy.

## DIAGNOSTIC ADVANTAGE OF CMR FOR MYOCARDITIS

Cardiovascular magnetic resonance imaging is inherently attractive for the detection of myocarditis because CMR visualizes the entire myocardium, which is ideal for a patchy process such as myocarditis. It also is sensitive to changes in tissue composition, which is altered in inflammation.

The acute inflammatory process in myocarditis involves local cytokine release and mobilization of inflammatory cell and subsequently antibodies and complement to the foci of activity (2,3). In the subacute phase, the tissue undergoes remodeling with local cell necrosis, increased vascular permeability, tissue edema, and finally fibrosis (1). By altering inherent tissue relativity signatures and contrast kinetics, these processes can be readily detected by CMR.

In terms of intrinsic sensitivities to cardiac inflammation, the tissue  $T_2$  relaxation time is inherently an indicator of tissue water content, which is increased in inflammation or necrosis, such as during myocardial infarction or myocarditis. The study by Abdel-Aty et al. (4) in this issue of the *Journal* used a  $T_2$ -sensitive imaging sequence to study 25 patients with suspected myocarditis and 23 control subjects. The increase in  $T_2$  signal intensity demonstrated a sensitivity of 84% and specificity of 74% in distinguishing the myocarditis population from control subjects. The  $T_2$  values also correlated with markers of cardiac injury in this population, likely reflecting the degree of local acute tissue necrosis and tissue edema.

To enhance the detection of pathology on CMR, gadolinium-diethylene triamine pentaacetate (DTPA) is an approved extracellular  $T_1$ -enhancing contrast agent. Abdel-Aty et al. (4) also demonstrated higher levels of global myocardial enhancement after gadolinium infusion, likely secondary to increased membrane permeability or increased capillary blood flow. The former process is likely the major contributor because inflammation damages cell membrane through both T-cell perforin and B-cell antibody/complement-mediated mechanisms. The resulting increase in volume of distribution leads to the accumulation of extracellular imaging labels such as gadolinium-DTPA.

Interestingly, Abdel-Aty et al. (4) also have found that late gadolinium enhancement was present in approximately half of patients with myocarditis. This finding is similar to findings in patients with myocardial infarction and confers specificity to myocardial necrosis. The exact pathophysiological mechanism is not certain, but recent pathological correlation studies in patients with hypertrophic cardiomyopathy suggest that the local formation of collagen bundles may provide a framework for this phenomenon (5), which

\*Editorials published in the *Journal of the American College of Cardiology* reflect the views of the authors and do not necessarily represent the views of *JACC* or the American College of Cardiology.

From the †Heart & Stroke/Richard Lewar Centre of Excellence, University of Toronto, and University Health Network, Toronto, Ontario, Canada; and the ‡Cardiovascular Division, Brigham and Women's Hospital, Harvard Medical School, Boston, Massachusetts. Supported in part by grants from the Heart and Stroke Foundation of Ontario and the Canadian Institutes of Health Research. Dr. Liu is the Heart & Stroke/Polo Chair Professor of Medicine at the University of Toronto. Dr. Yan is supported by a Canadian Institutes of Health Research Award.

may explain the higher frequency of late gadolinium enhancement observed in subacute myocarditis, when healing has begun to take place and the laying down of collagen framework is in progress.

**CLINICAL APPLICATION OF CMR IN MYOCARDITIS—COMPARISON WITH OTHER STUDIES TO DATE**

The study by Abdel-Aty et al. (4) is the latest and the most comprehensive of a series of studies by various investigators in the application of CMR, particularly with contrast, to diagnose myocarditis (6–8). All the studies recognize the patchy abnormalities to be regional, temporally variable, and that the sensitivity of detection is enhanced by the application of contrast agents. Several studies also have noted a general increase in global myocardial enhancement in peripheral muscle during the acute phase, suggesting generalized peripheral muscle changes in addition to the myocardium during acute myocarditis that is hitherto unrecognized. The overall sensitivities and specificities of the various studies are illustrated in Figure 1. The study by Abdel-Aty et al. (4) is the only one showing excellent accuracy with T<sub>2</sub>-weighted sequence without contrast, likely because of the particular dominance of T<sub>2</sub> weighting in their inversion recovery imaging sequence.

F1

**CONTINUING CHALLENGES IN DIAGNOSIS OF MYOCARDITIS**

The study by Abdel-Aty et al. (4) does have some deficiencies. Confirmation of myocarditis by myocardial biopsy was conducted only in two patients. Although this “gold standard” is very insensitive, it does add specificity to the study (9). This is particularly relevant when only 21 of the 25 patients had coronary angiography.

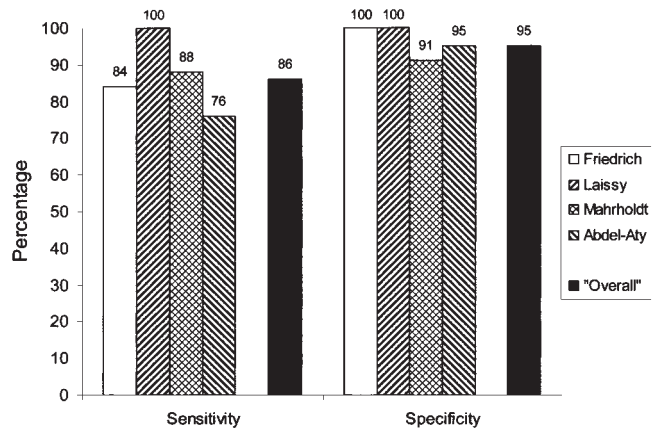
Like other important studies, the one by Abdel-Aty et al. (4) raises several issues that need to be addressed in the

**Table 1.** Comparison of Efficacy of Various Diagnostic Modalities for Myocarditis

Diagnostic Modality	Sensitivity Range (%)	Specificity Range (%)
ECG changes (AV block, Q, ST changes)	47	Unknown
Troponin	34	89
CK-MB	6	100
Antibodies to virus or myosin	25–32	40
In-111 antimyosin scintigraphy	85–91	34–53
Myocardial biopsy (Dallas criteria of pathology)	35–50	78–89
Myocardial biopsy (viral genome by PCR) (9)	38	80–100

The gold standard used in each consisted of clinical composites of presentation, natural history, and myocardial biopsy or autopsy.

AV = atrioventricular; CK-MB = creatine kinase-myocardial band; ECG = electrocardiography; In = indium; PCR = polymerase chain reaction.



**Figure 1.** Comparison of the various studies of the relative accuracies of cardiovascular magnetic resonance imaging in the detection of acute myocarditis. The earliest study was by Friedrich et al. (6), which featured 19 patients and 18 control subjects, followed by Laissy et al. (7), whose work featured 20 patients and 7 control subjects and, in 2004, studies by Mahrholdt et al. (8), featuring 32 patients and 11 control subjects), and the current study by Abdel-Aty et al. (4), featuring 25 patients and 23 control subjects. “Overall” diagnostic sensitivity was 86% (83 of 96 cases) and specificity was 95% (56 of 59 control subjects), arrived at by a simple pooling of the subjects, and the associated caveats thereof.

future. The use of healthy volunteers as study controls might have introduced a spectrum bias, and the diagnostic performance of CMR among patients with structural heart diseases that masquerade as myocarditis (i.e., the true clinical utility of CMR) should be confirmed in prospective studies. Conversely, because the study cases were defined on the basis of clinical criteria and other readily available biomarkers, the incremental diagnostic value of CMR and its role in the routine workup of suspected myocarditis also require clarification. Because the extent and distribution of tissue changes detected by CMR evolve over time (6), the optimal timing of this modality and whether the proposed diagnostic cutoffs should be modified according to the time from symptom onset are among other practical issues. Finally, because myocarditis represents a heterogeneous condition with a variable and often unpredictable outcome, the greatest clinical utility of CMR may lie in its ability to prognosticate patients—those with a benign natural history are unlikely to benefit from aggressive treatments—whereas those with a less-favorable prognosis require intensive surveillance and may be enrolled in clinical trials evaluating novel therapies. We are optimistic that, in concert with ongoing advances in genomic and proteomic technologies, future developments in molecular and cellular imaging using CMR will provide invaluable insights in the pathophysiology, early diagnosis, and management of this intriguing disease.

**Reprint requests and correspondence:** Dr. Peter Liu, Heart & Stroke/Richard Lewar Centre of Excellence, NCSB 11-1266, 200 Elizabeth Street, Toronto, Ontario M5G 2C4, Canada. E-mail: peter.liu@utoronto.ca.

## REFERENCES

1. Liu P, Mason J. Advances in the understanding of myocarditis. *Circulation* 2001;104:1076-82.
2. Ayach B, Fuse K, Martino T, Liu P. Dissecting mechanisms of innate and acquired immunity in myocarditis. *Curr Opin Cardiol* 2003;18:175-81.
3. Liu P, Aitken K, Kong YY, et al. Essential role for the tyrosine kinase p56lck in coxsackievirus B3 mediated heart disease. *Nat Med* 2000;6:429-34.
4. Abdel-Aty H, Boyé P, Zagrosek A, et al. Diagnostic performance of cardiovascular magnetic resonance in patients with suspected acute myocarditis: comparison of different approaches. *J Am Coll Cardiol* 2005;45:1815-22.
5. Moon JC, Reed E, Sheppard MN, et al. The histologic basis of late gadolinium enhancement cardiovascular magnetic resonance in hypertrophic cardiomyopathy. *J Am Coll Cardiol* 2004;43:2260-4.
6. Friedrich MG, Strohm O, Schulz-Menger J, Marciniak H, Luft FC, Dietz R. Contrast media-enhanced magnetic resonance imaging visualizes myocardial changes in the course of viral myocarditis. *Circulation* 1998;97:1802-9.
7. Laissy JP, Messin B, Varenne O, et al. MRI of acute myocarditis: a comprehensive approach based on various imaging sequences. *Chest* 2002;122:1638-48.
8. Mahrholdt H, Goedecke C, Wagner A, et al. Cardiovascular magnetic resonance assessment of human myocarditis: a comparison to histology and molecular pathology. *Circulation* 2004;109:1250-8.
9. Bowles NE, Ni J, Kearney DL, et al. Detection of viruses in myocardial tissues by polymerase chain reaction: evidence of adenovirus as a common cause of myocarditis in children and adults. *J Am Coll Cardiol* 2003;42:466-72.